

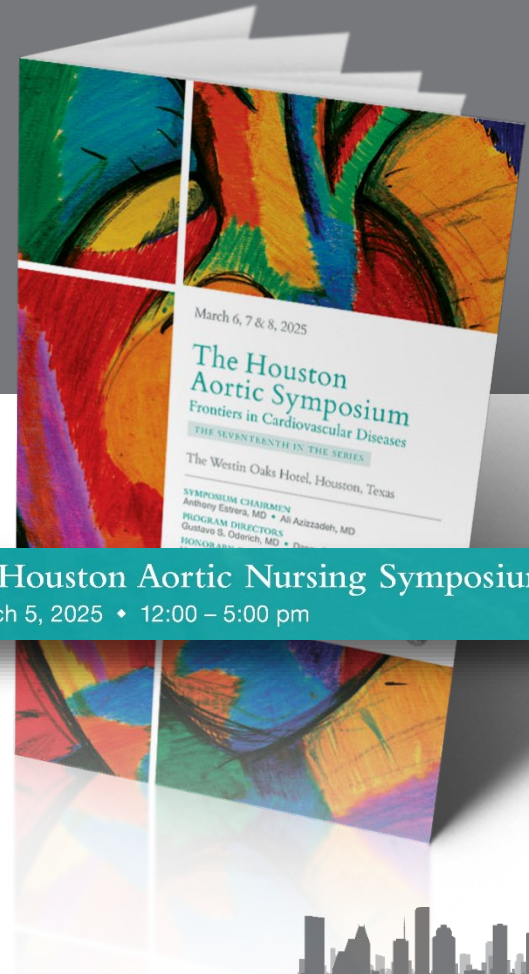
Acute Limb Ischemia and Compartment Syndrome

Karen Edgington

MPAS, PA-C

Department of Cardiothoracic and Vascular Surgery
McGovern Medical School at UTHealth
Houston, Texas / USA

Department of
**Cardiothoracic &
Vascular Surgery** |  **UTHealth® Houston**
McGovern Medical School

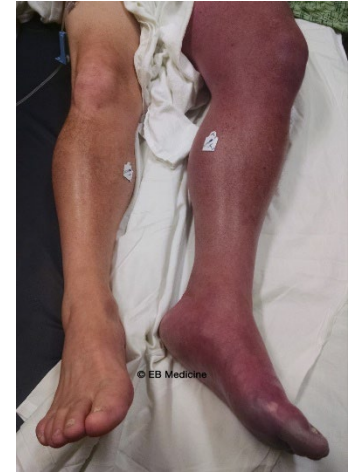

7th Annual Houston Aortic Nursing Symposium

Wednesday, March 5, 2025 • 12:00 – 5:00 pm

Acute Limb Ischemia

- Arterial occlusion
 - Native arterial thrombosis, arterial thrombosis following intervention, arterial embolus, arterial injury
- Extensive venous occlusion
 - Total occlusion of deep iliofemoral venous system



Physical Examination

- Clinical Features (6 P's)
 - Pain
 - Pallor
 - Poikilothermia
 - Pulselessness
 - Paresthesia paralysis.



Table 1.

Stages of acute limb ischemia (ALI) according to the Rutherford classification [14].

Stage	Prognosis	Findings		Doppler Signal	
		Sensory Loss	Muscle Weakness	Arterial	Venous
I	Limb viable, not immediately threatened	None	None	Audible	Audible
IIa	Limb marginally threatened, salvageable if promptly treated	Minimal (toes)	None	Often inaudible	Audible
IIb	Limb immediately threatened, salvageable with immediate revascularization	More than toes, pain at rest	Mild or moderate	Inaudible	Audible
III	Limb irreversibly damaged, major tissue loss or permanent nerve damage inevitable	Profound, anesthetic	Paralysis (rigor)	Inaudible	Inaudible



- Therapeutic strategy

- Type of occlusion
- Type of conduit
- Rutherford class
- Duration of ischemia
- Co-morbidities
- Therapy related risks



Treatment

- Therapeutic anticoagulation
- Catheter- directed thrombolysis (CDT)
- Mechanical thrombectomy
- Open surgery



Absolute and relative contraindications to catheter-directed thrombolysis (CDT) (modified after [29]).

Absolute Contraindications to CDT

Active bleeding

Intracranial hemorrhage

Presence or development of compartment syndrome

Severe limb ischemia, requiring immediate operative intervention

For streptokinase: prior administration of streptokinase

Relative Contraindications to CDT

Uncontrolled hypertension > 180/110 mmHg

Puncture of non-compressible vessel

Intracranial tumor

Ischemic cerebrovascular event < 2 months

Neurosurgery or head trauma within past 3 months

Gastrointestinal bleeding < 10 days

Hepatic failure, particularly in cases with coagulopathy

Pregnancy/postpartum status

Bacterial endocarditis

History of severe contrast allergy or hypersensitivity



Mechanical thrombectomy

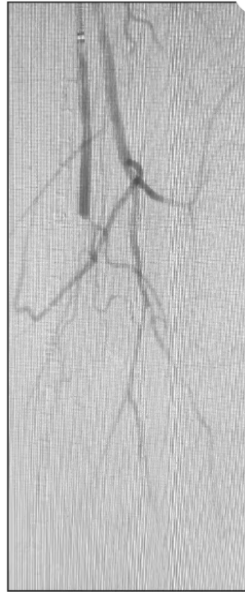

Figure 1. Arteriogram demonstrating an embolus occluding the superficial femoral artery and popliteal artery.




Figure 2. Completion arteriogram after the use of a CAT 6 (Penumbra, Inc.) and Viabahn (Gore & Associates) stenting of the superficial femoral and popliteal arteries.



Reperfusion Injury

- Pain out of proportion
- Decreased pulses
- Skin changes
- Decreased sensation



Acute compartment Syndrome

- Clinical diagnosis
- ICP >30mmHg
- Pain “out of proportion”
- “wood-like”

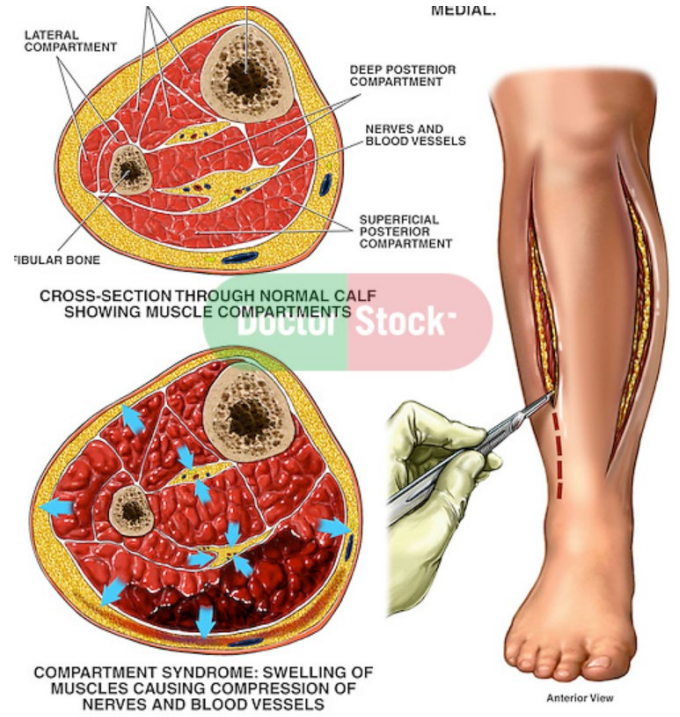


Anatomical structures of lower leg

- Anterior compartment
 - Tibialis anterior
 - Extensor hallucis longus
 - Extensor digitorum longus
 - Peroneus tertius
 - Deep fibular nerve
 - Anterior tibial artery
- Lateral compartment
 - Peroneus longus
 - Peroneus tertius
 - Superficial fibular nerve
 - Fibular artery
- Superficial posterior compartment
 - Gastrocnemius
 - Soleus
 - Plantaris
 - Sural nerve
- Deep posterior compartment
 - Tibialis posterior
 - Flexor hallucis longus
 - Flexor digitorum longus
 - Popliteus
 - Tibial nerve
 - Posterior tibial artery



Fasciotomy



References

1. Mitchell, M. (2025, February). *Clinical features and diagnosis of acute arterial occlusion of the lower extremities [Online forum post]*. UpToDate. Retrieved March 3, 2025, from https://www.uptodate.com/contents/clinical-features-and-diagnosis-of-acute-arterial-occlusion-of-the-lower-extremities?source=mostViewed_widget
2. "Phlegmasia Cerulea Dolens (PCD) - Visual Diagnosis." Ebmedicine.net, 2025, www.ebmedicine.net/content.php?action=showPage&pid=%20475. Accessed 5 Mar. 2025.
3. Olinic DM, Stanek A, Tătaru DA, Homorodean C, Olinic M. Acute Limb Ischemia: An Update on Diagnosis and Management. *J Clin Med*. 2019 Aug 14;8(8):1215. doi: 10.3390/jcm8081215. PMID: 31416204; PMCID: PMC6723825.
4. Michael C. Siah, M. (2021, January 19). *Evaluation and management of acute limb ischemia*. Endovascular Today. <https://evtoday.com/articles/2021-jan/evaluation-and-management-of-acute-limb-ischemia>
5. Torlincasi AM, Lopez RA, Waseem M. Acute Compartment Syndrome. [Updated 2023 Jan 16]. In: StatPearls [Internet]. Treasure Island (FL): StatPearls Publishing; 2025 Jan-. Available from: <https://www.ncbi.nlm.nih.gov/books/NBK448124/>
6. Ikhlas M, Atherton NS. Vascular Reperfusion Injury. [Updated 2023 Aug 14]. In: StatPearls [Internet]. Treasure Island (FL): StatPearls Publishing; 2025 Jan-. Available from: <https://www.ncbi.nlm.nih.gov/books/NBK562210/>
7. <https://www.doctorstock.com/image/I0000trUdwuuYX3Y>
8. Ormiston RV, Marappa-Ganeshan R. Fasciotomy. [Updated 2023 Aug 17]. In: StatPearls [Internet]. Treasure Island (FL): StatPearls Publishing; 2025 Jan-. Available from: <https://www.ncbi.nlm.nih.gov/books/NBK556153/>






Thank You!



Department of
**Cardiothoracic &
Vascular Surgery**

 **UTHealth** Houston
McGovern Medical School

   **UTH_CVSurgery**
info.ctvs@uth.tmc.edu
<https://med.uth.edu/cvs/>

