# Treating Patients With Renal Insufficiency

## *Zero Contrast PCI*

**Ziad A Ali MD DPhil**

**Columbia University Medical Center**

**Cardiovascular Research Foundation**

# Disclosure Statement of Financial Interest

Within the past 12 months, I or my spouse/partner have had a financial interest/arrangement or affiliation with the organization(s) listed below.

| Affiliation/Financial Relationship | Company |
| --- | --- |
| Grant/Research Support | NIH/NHLBI, Abbott Vascular, Cardiovascular Systems Inc |
| Consulting Fees/Honoraria | Acist Medical, Boston Scientific, Cardinal Health, Opsens Medical, Shockwave Medical |
| Equity | Shockwave Medical |

# Cardiovascular disease in CKD IV-V/ ESRD

- Accounts for 53% of all deaths with a known cause
- Remains the leading cause of death after renal transplantation
- Exclusion from RCTs has led to a paucity of data making cardiovascular management in this population very challenging

Bhatti and Ali. JAHA 2016;5(8)

# Morbidity of Contrast Nephropathy

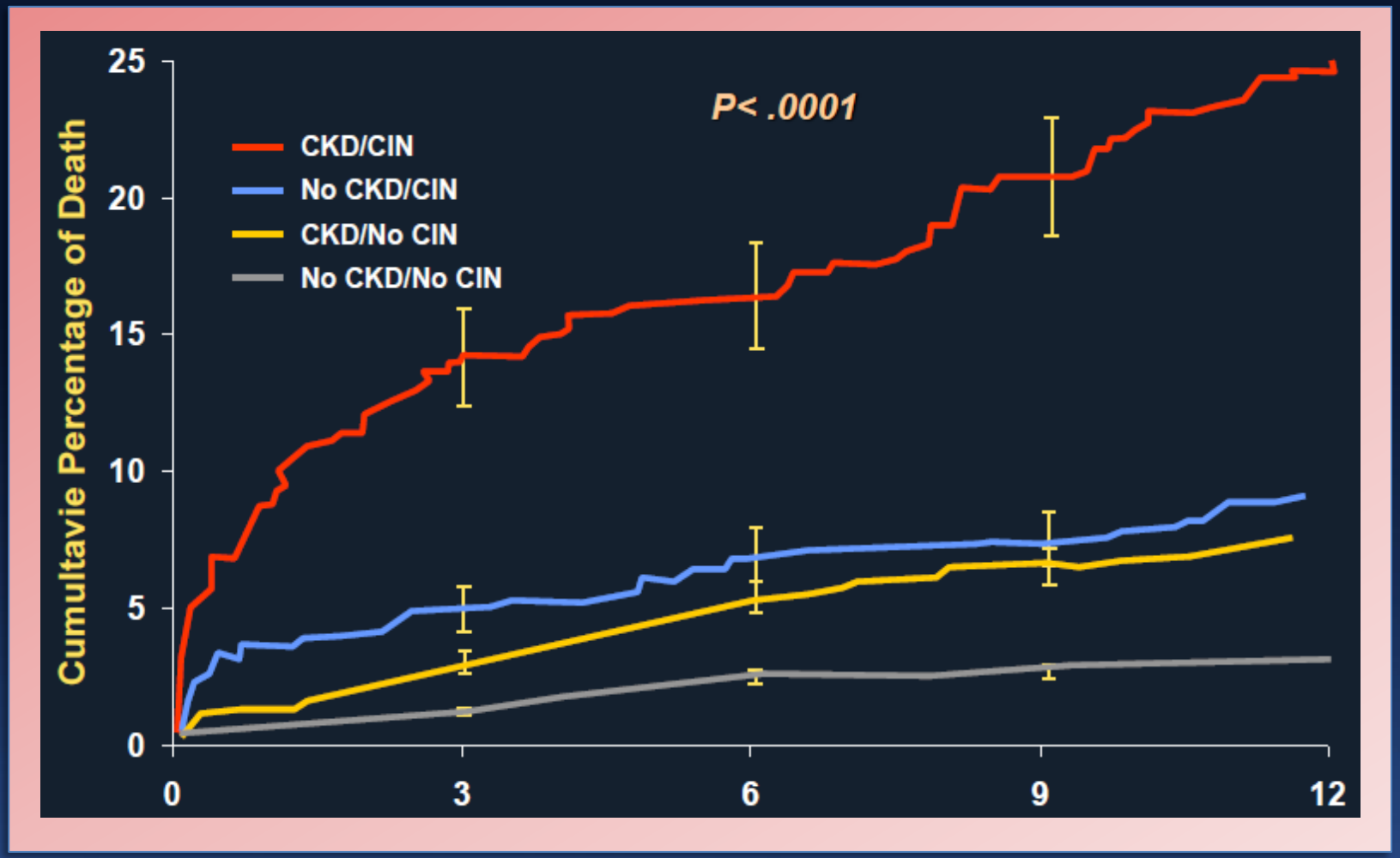


- Revascularization by PCI in patients with advanced CKD is drastically underutilized.

Cardiovascular Research Foundation

Dangas et al. AJC 2005; 95:13-19

Columbia University Medical Center
NewYork-Presbyterian

# "Renalism"

| Author | Presentation | N | CKD | CKD Invasive | No CKD Invasive |
|---|---|---|---|---|---|
| Chertow | MI | 57,284 | 26% | 25% | 47% |
| Han | NSTEACS | 45,343 | 14% | 48% | 74% |
| Goldenberg | NSTEACS | 13,141 | 32% | 50% | 68% |
| Szummer | MI | 57,477 | 33% | 33% | 58% |

Weisbord S. Clin J Am Soc Nephrol. 2014;9(11):1823-35

# Atherosclerotic Progression in CKD


CKD V


HD

# Benefits of PCI in NSTEACS in CKD

N = 15 680

| eGFR | Strategy | Adjusted OR | P |
|---|---|---|---|
| 60-90 | OMT vs PCI | 0.63 (0.49-0.81) | <0.001 |
| 45-60 | OMT vs PCI | 0.69 (0.51-0.95) | 0.020 |
| 30-45 | OMT vs PCI | 0.68 (0.49-0.94) | 0.021 |
| <30 | OMT vs PCI | 0.80 (0.52-1.24) | 0.32 |

*Entered into model, hypertension, previous angina, previous myocardial infarction, hyperlipidaemia, peripheral vascular disease, cerebrovascular disease, chronic obstructive airways disease, congestive cardiac failure, diabetes mellitus, previous PCI, previous CABG, hemoglobin (g/dl) and peak troponin*

Cardiovascular Research Foundation

Shaw et al. PLoS One. 2014 Jun 17;9(6):e99925.

Columbia University Medical Center
NewYork-Presbyterian

# Potential Management Strategies

***Experimental***

- **DyeVert[1]**
- **RenalGuard[2]**

***Experimental***

- **N-acetylcysteine[3]**
- **Sodium Bicarbonate[3]**
- **Iso-osmolar contrast[4,5]**


[1]Catheter Cardiovasc Interv. 2013 Dec 10.
[2]JACC Cardiovasc Interv. 2017 Feb 27;10(4):355-363.
[3]N Engl J Med. 2018 Feb 15;378(7):603-614.
[4]Circulation. 2007 Jun 26;115(25):3189-96.
[5]Circ Cardiovasc Interv. 2009 Oct;2(5):430-7

# Clinically Validated Strategies

# Hemodynamic-guided IV Hydration

Randomized, parallel-group, comparator-controlled, single-blind phase 3 trial

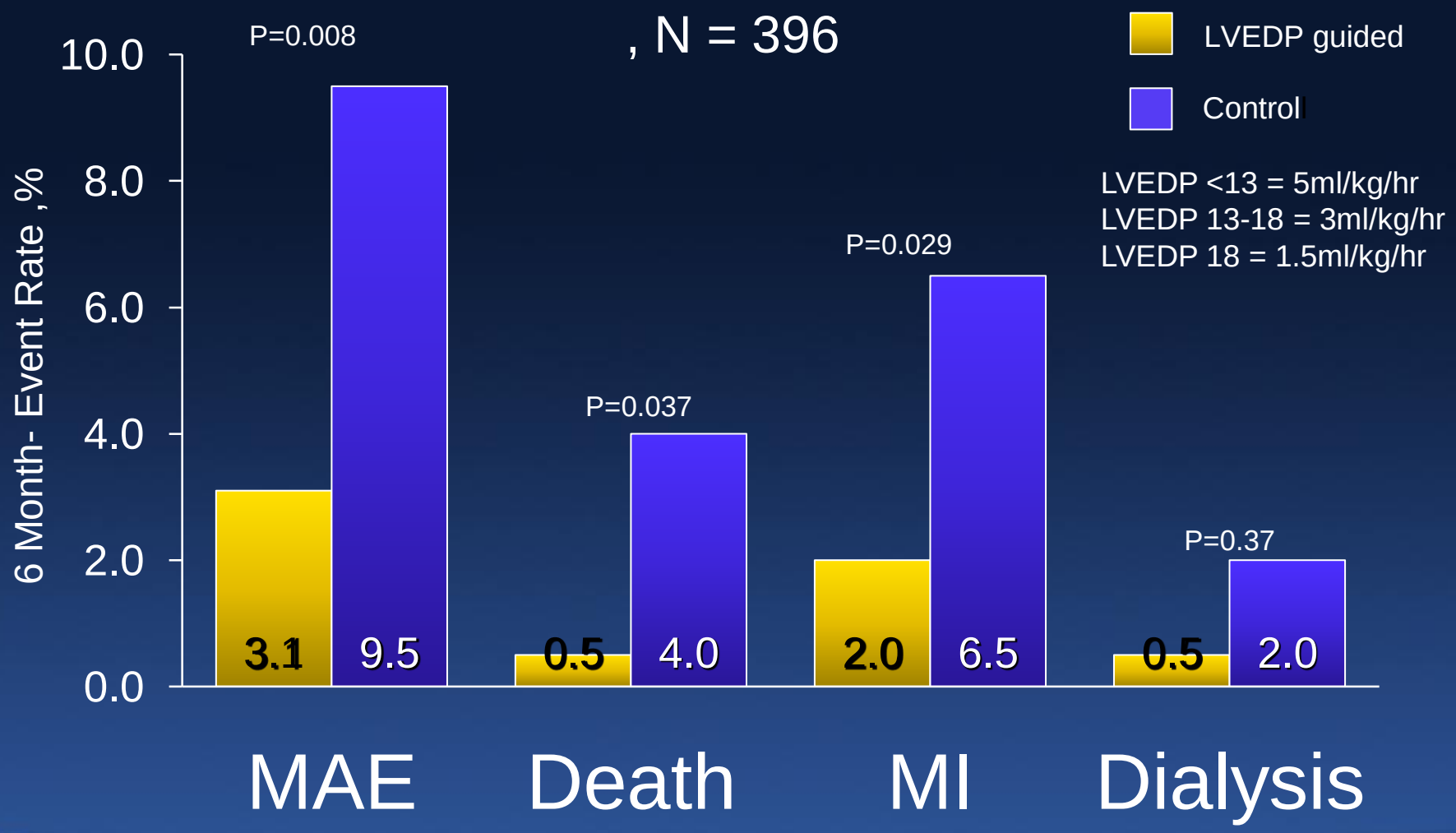


Brar et al. Lancet 2014

# Intravascular Imaging Guidance

## Intravascular Ultrasound Guidance to Minimize the Use of Iodine Contrast in Percutaneous Coronary Intervention

### The MOZART (Minimizing cOntrast utiliZation With IVUS Guidance in coRonary angioplasTy) Randomized Controlled Trial

**CONCLUSIONS** Thoughtful and extensive use of IVUS as the primary imaging tool to guide PCI is safe and markedly reduces the volume of iodine contrast compared with angiography-alone guidance. The use of IVUS should be considered for patients at high risk of contrast-induced acute kidney injury or volume overload undergoing coronary angioplasty. (Minimizing cOntrast utiliZation With IVUS Guidance in coRonary angioplasTy [MOZART]; NCT01947335) (J Am Coll Cardiol Intv 2014;7:1287–93) © 2014 by the American College of Cardiology Foundation.

| Primary endpoint | Angiography-guided (n=42) | IVUS-guided (n=41) | *P* |
|---|---|---|---|
| **Total contrast volume, ml** | 71.4 ± 35.9 | 22.9 ± 12.5 | <0.001 |

Marini et al. JACC Int 2014; 7:1287

# Ultra-low contrast angiography

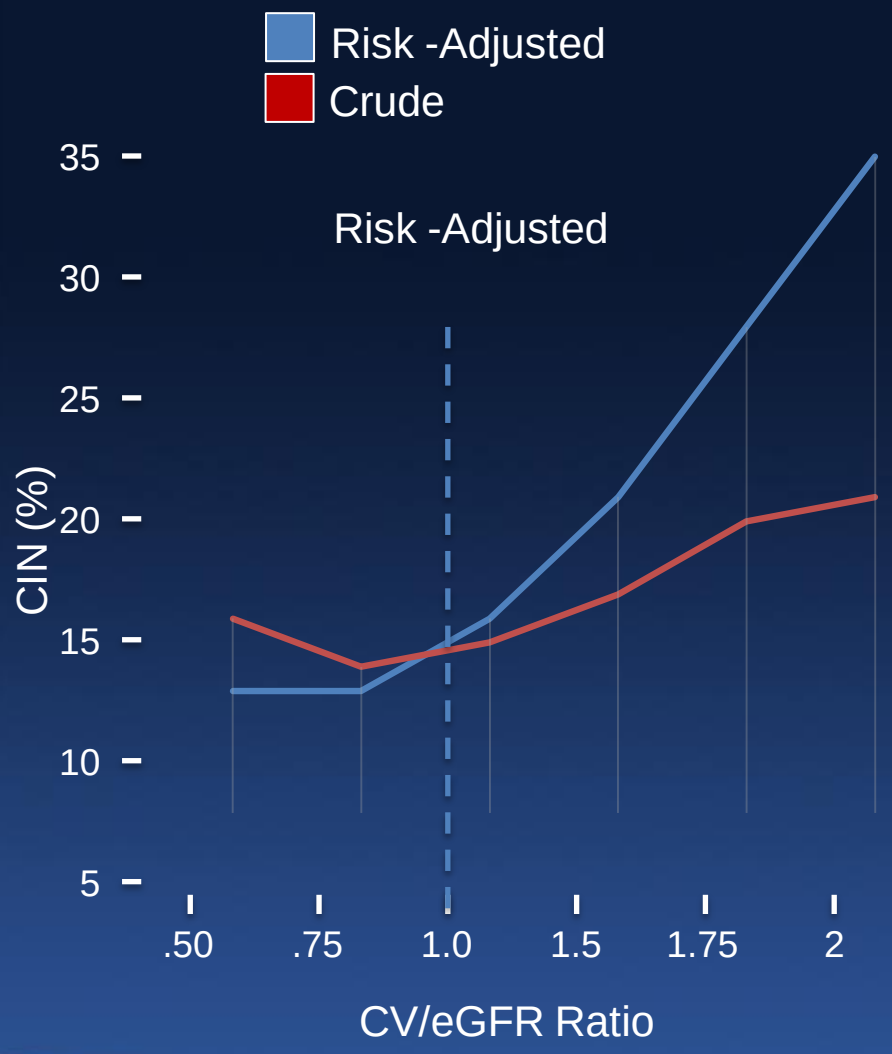


- Contrast volume/eGFR ratio ≤ 1
- eGFR <15 contrast diluted
- Projections
  - RCA – LAO/Cranial
  - LCA – AP/Cranial and AP/Caudal
- LVEDP used to guide hydration

Cardiovascular Research Foundation

Brown et al. Circ Interv 2010;3:346-350

Columbia University Medical Center
NewYork-Presbyterian

# Ultra-low contrast angiography

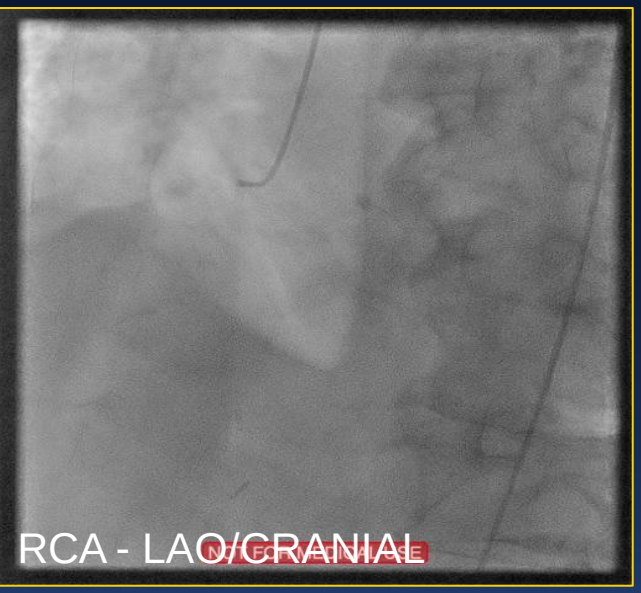


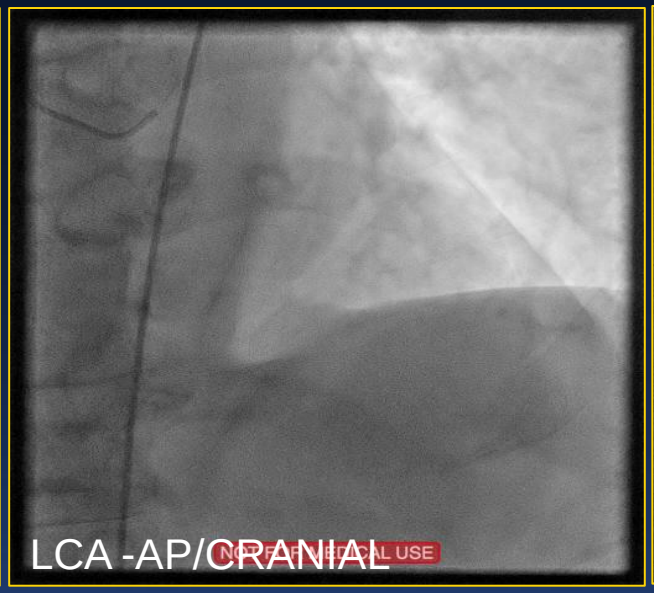


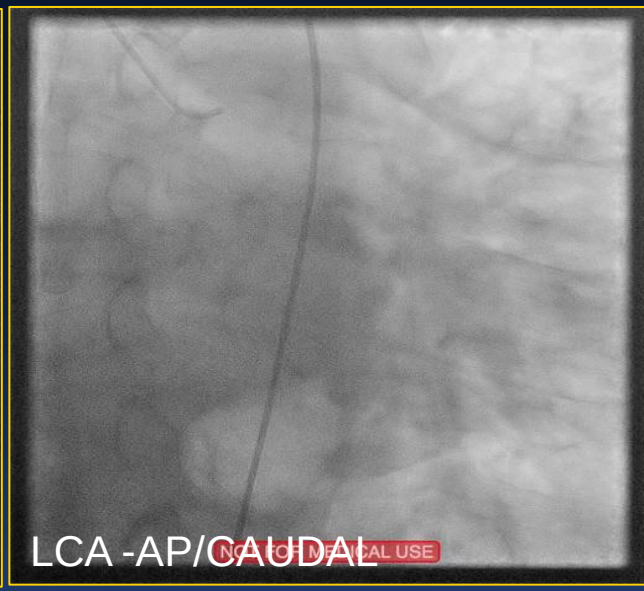

# ULCA

# Standard of Care

## CKD V
## eGFR – 16mg/dL

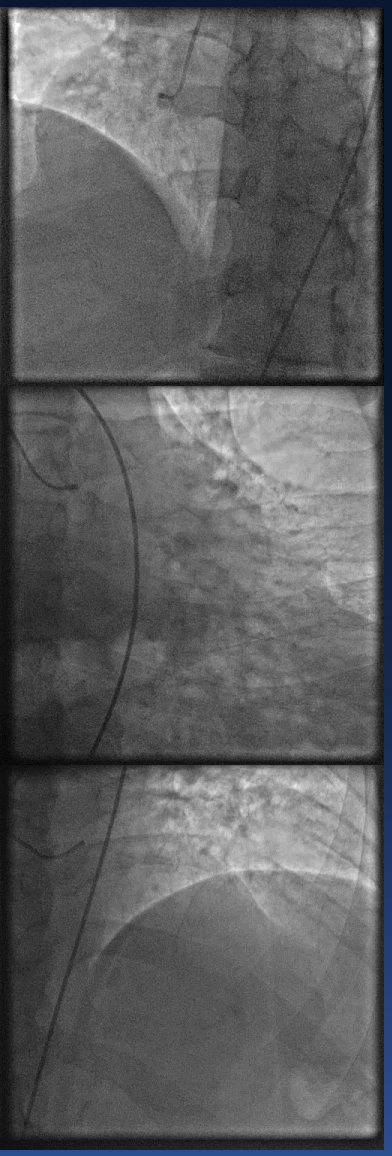

9cc contrast

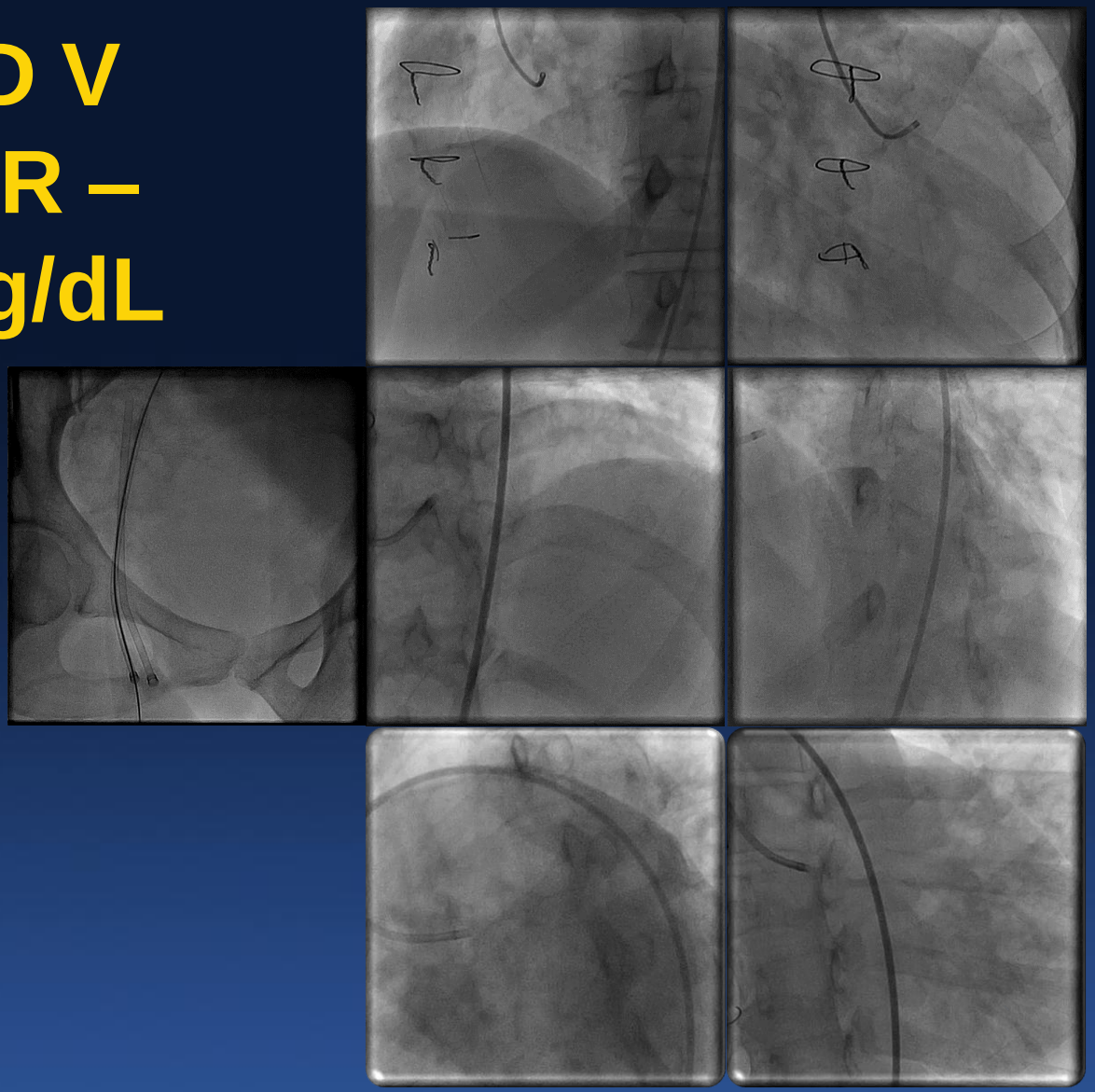

77cc contrast

# Physiological Guidance

FFR/iFR with pullback used to confirm ischemia in:

- intermediate lesions
- poor visualization

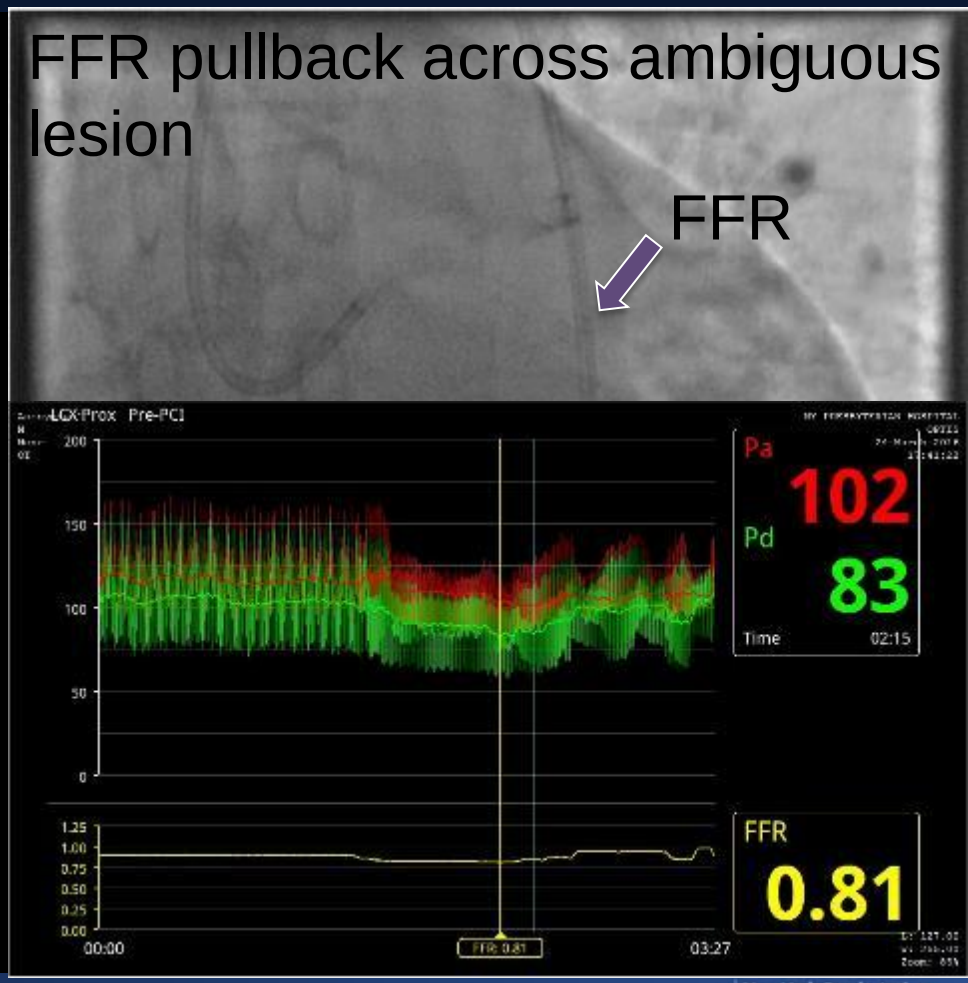

# Ultra-low contrast angiography

| Clinical Characteristics | Ultra-Low Contrast (n=51) | Standard (n=50) | *P* |
|---|---|---|---|
| eGFR | 20.2 ± 13.0 | 21.6 ± 7.0 | 0.51 |
| Age | 65.3 ± 13 | 67.3 ± 13 | 0.45 |
| Male, % | 72 | 72 | 0.95 |
| African American, % | 16 | 12 | 0.56 |
| Hypertension, % | 90 | 90 | 1.0 |
| Diabetes Mellitus, % | 67 | 60 | 0.37 |
| Dyslipidemia, % | 74 | 90 | 0.04 |
| Peripheral arterial disease, % | 14 | 18 | 0.56 |
| Congestive Heart Failure, % | 34 | 44 | 0.30 |
| LVEF | 46 ± 18 | 44 ± 17 | 0.71 |
| Previous MI, % | 40 | 34 | 0.53 |
| Previous PCI, % | 32 | 30 | 0.88 |
| Previous CABG, % | 12 | 12 | 0.97 |
| Active Smoker, % | 8 | 4 | 0.41 |
| Former Smoker, % | 51 | 42 | 0.42 |

# Outcomes

| Clinical Characteristics | Ultra-Low Contrast (n=51) | Standard (n=50) | *P* |
|---|---|---|---|
| Contrast Volume | 13.5 ± 6.5 | 39.9 ± 47.6 | <0.0001 |
| **Post-angiography** | | | |
| CIN | 0 | 8 | 0.04 |
| GFR | 19.6 ± 11.9 | 22.3 ± 8.0 | 0.18 |
| RRT | 0 | 8 | 0.04 |
| **Follow-up** | | | |
| GFR | 22.1 ± 13.6 | 15.1 ±15.0 | 0.009 |

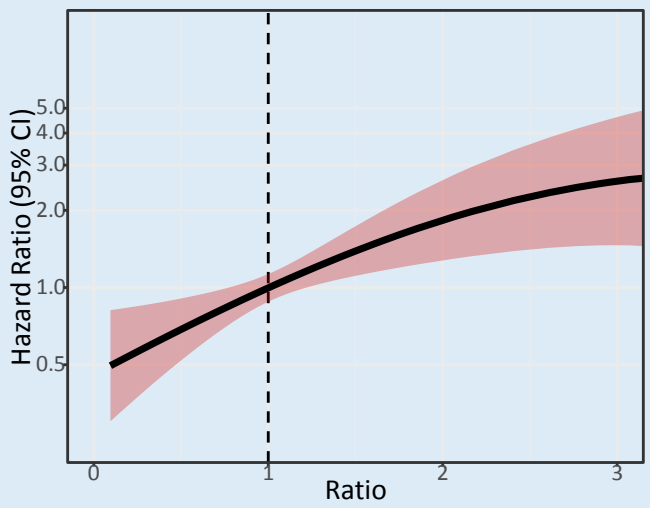


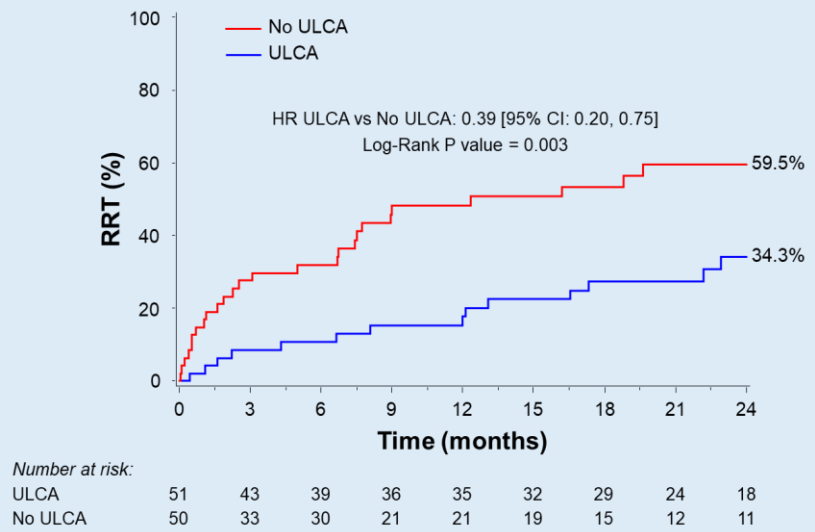

# Predictors of Renal Replacement Therapy

## Multivariable Predictors

| Clinical Characteristics | Hazard Ratio | 95% Confidence Interval | *P* |
|---|---|---|---|
| ULCA | 0.40 | 0.18-0.86 | 0.02 |
| LVEF | 0.97 | 0.95-0.99 | 0.003 |
| African American | 2.93 | 1.25-6.85 | 0.01 |
| Pre-angio eGFR | 0.91 | 0.86-0.96 | 0.003 |

# Minimal Contrast Angiography - CABG

No femoral artery arteriogram


Single AP Caudal of LCA given LIMA




Rahim and Ali et al. Coronary Artery Disease 2019; 30(5):346-51

# LIMA Angiography

Guidewire guidance to identify LIMA


LIMA angiography


Rahim and Ali et al. Coronary Artery Disease 2019; 30(5):346-51

# SVG Angiography

Guide wire guidance to identify SVG


SVG angiography


- Median contrast volume 13.5ml [IQR, 10.5, 17.8]



Rahim and Ali et al. Coronary Artery Disease 2019; 30(5):346-51

# Zero Contrast PCI

**First Description of PCI without Radio-contrast utilization**

European Heart Journal
doi:10.1093/eurheartj/ehw078

EHJ BRIEF COMMUNICATION
*Interventional cardiology*

## Imaging- and physiology-guided percutaneous coronary intervention without contrast administration in advanced renal failure: a feasibility, safety, and outcome study

**Ziad A. Ali[1,2]*, Keyvan Karimi Galougahi[1], Tamim Nazif[1,2], Akiko Maehara[1,2], Mark A. Hardy[3], David J. Cohen[4], Lloyd E. Ratner[3], Michael B. Collins[1,2], Jeffrey W. Moses[1,2], Ajay J. Kirtane[1,2], Gregg W. Stone[1,2], Dimitri Karmpaliotis[1,2], and Martin B. Leon[1,2]**

[1]Division of Cardiology, Center for Interventional Vascular Therapy, New York Presbyterian Hospital and Columbia University, New York, NY, USA; [2]Cardiovascular Research Foundation, New York, NY, USA; [3]Department of Surgery, New York Presbyterian Hospital and Columbia University, New York, NY, USA; and [4]Division of Nephrology, New York Presbyterian Hospital and Columbia University, New York, NY, USA

*Received 21 December 2015; revised 10 January 2016; accepted 3 February 2016*



Ali et al. Eur Heart J. 2016;37(40):3090-3095.

# Zero contrast PCI

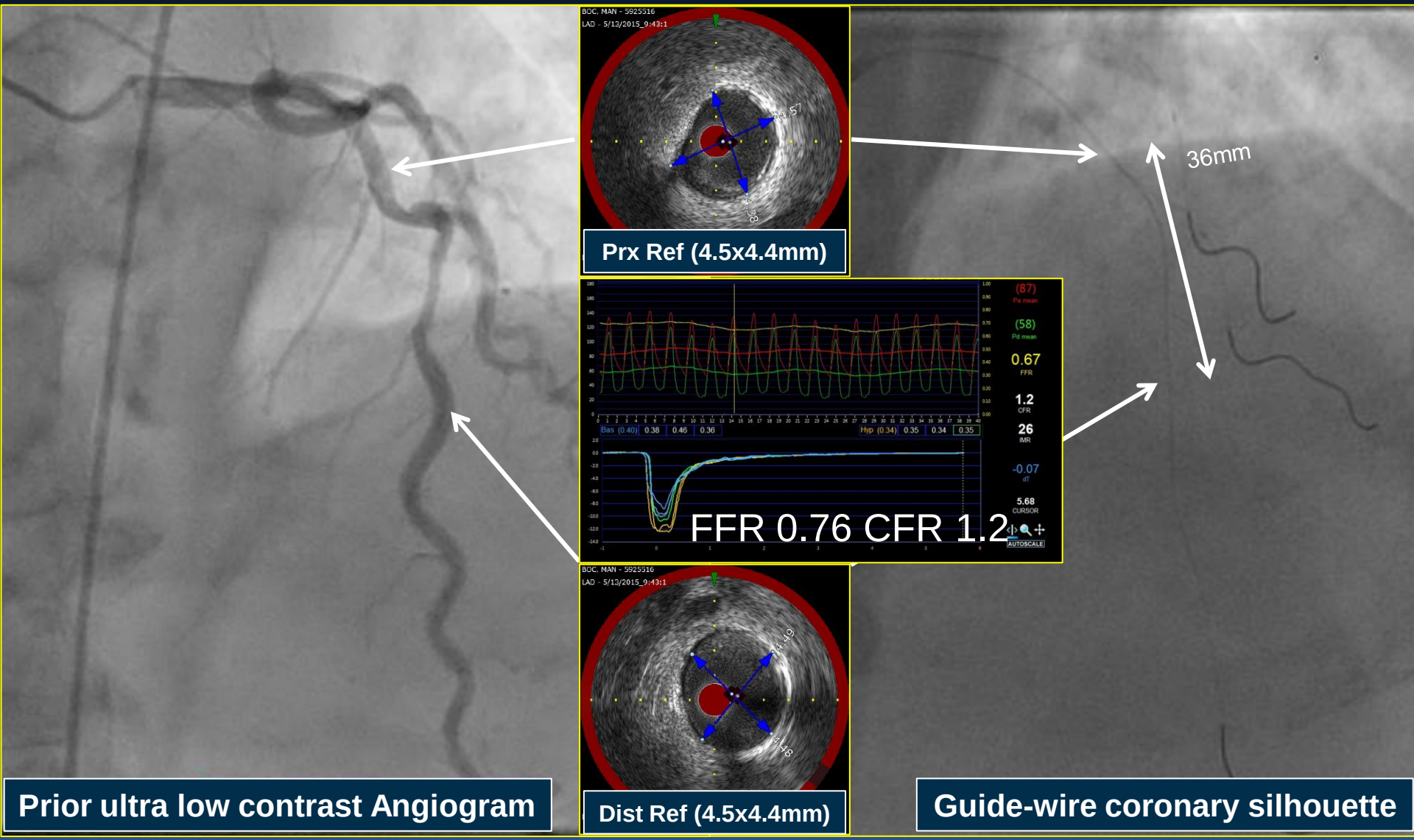


Ali et al. Eur Heart J. 2016;37(40):3090-3095.

# Zero contrast PCI

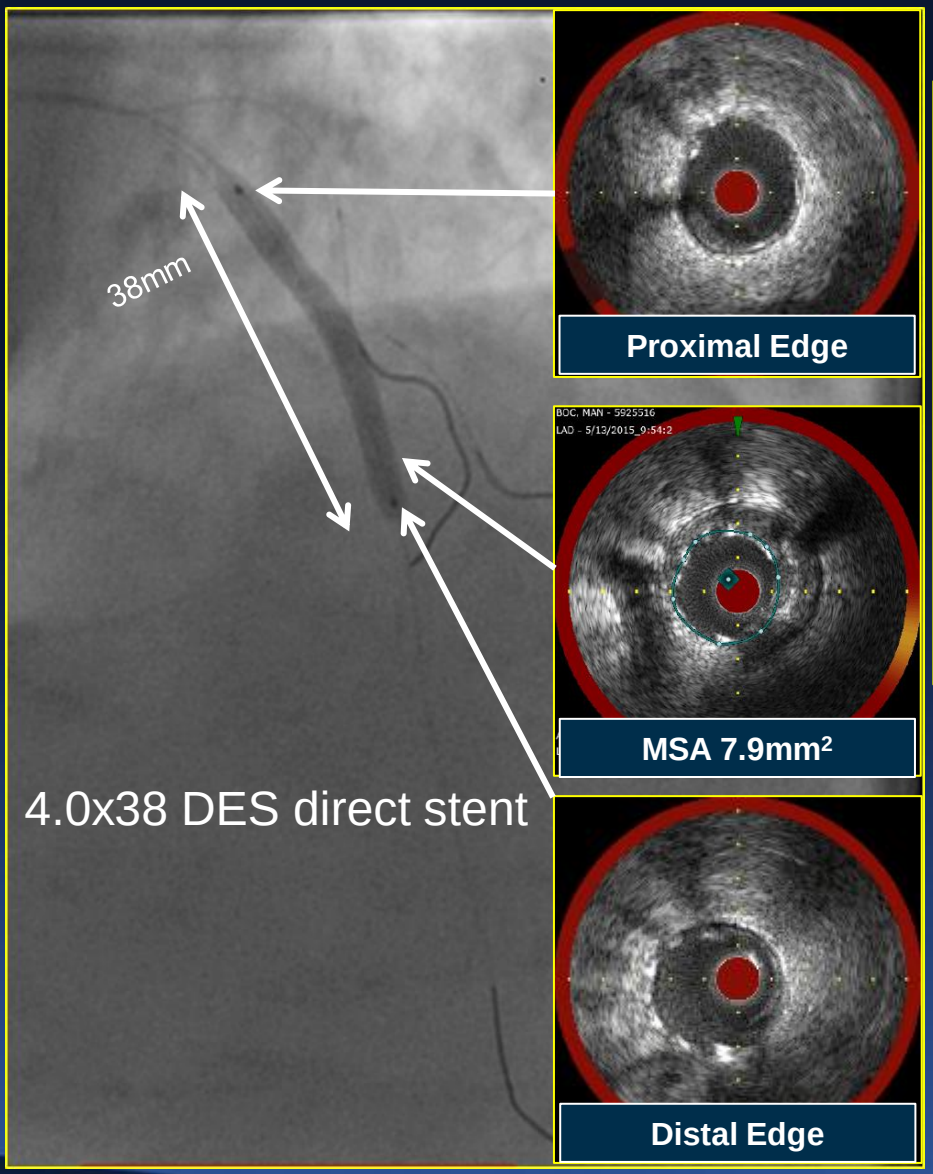


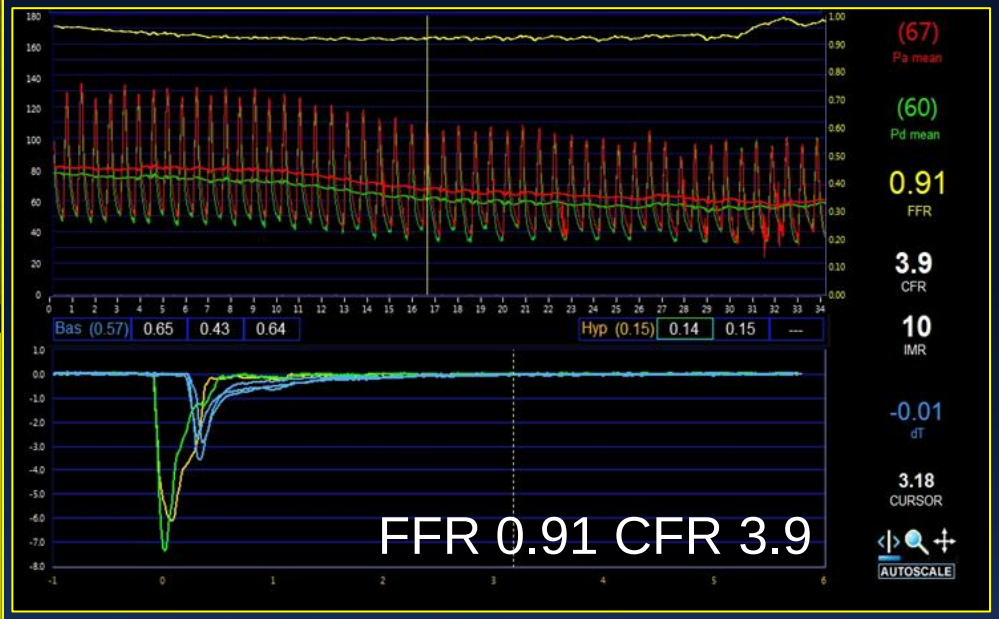


- 93% stent expansion
- FFR 0.91 (no ischemia)
- CFR 3.9 (no slow flow)

Ali et al. Eur Heart J. 2016;37(40):3090-3095.

# Angiography

- 68 year-old male IDDM (EF 55%), CKD V (Cr 3.8, GFR 13) who presents with progressive angina and SOB for 5 months.
- Has been having increasing medical therapy over that time, now on Carvedilol 12.5mg BID, Amlodipine 7.5mg OD (intolerant to nitrates).
- Primary cardiologist referred for coronary angiography to Columbia University Cardio-renal Center

# Minimal Contrast Angiography

Pre-angiography LVEDP guides hydration

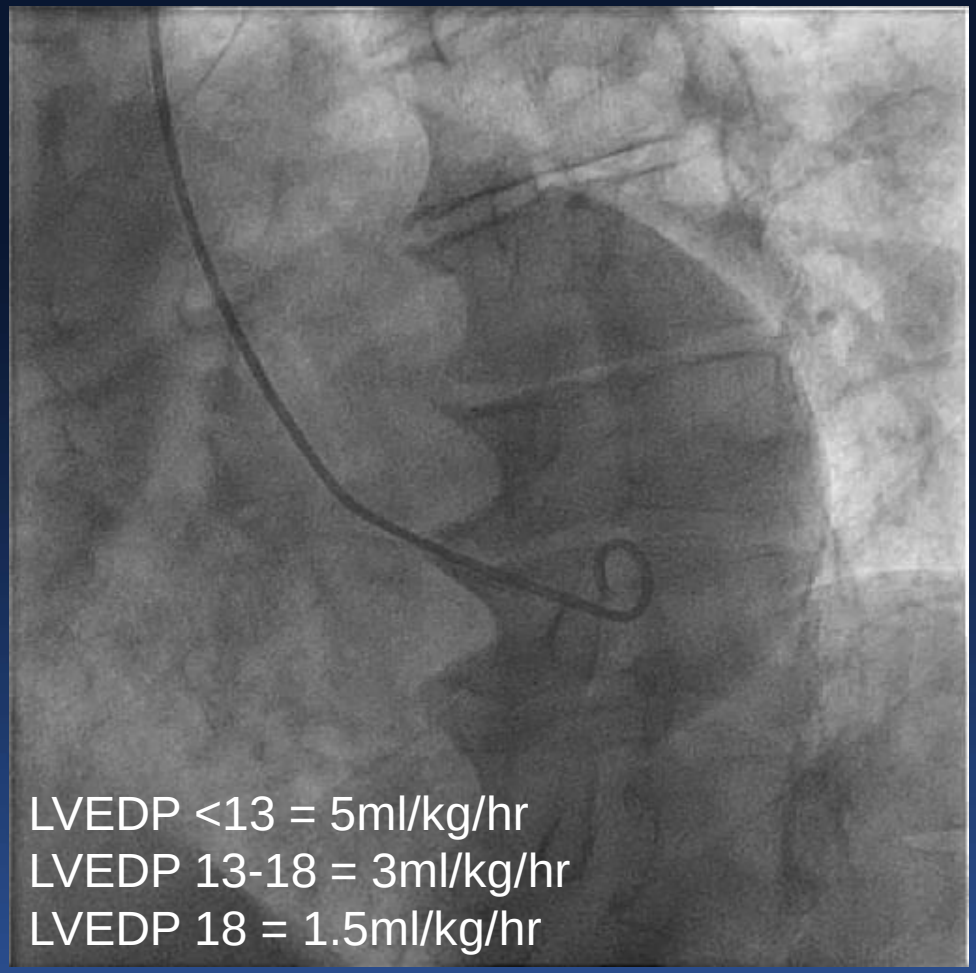


Brar et al. POSEIDEN. Lancet 2014

# Confirmation of Catheter Engagement

Baseline EKG

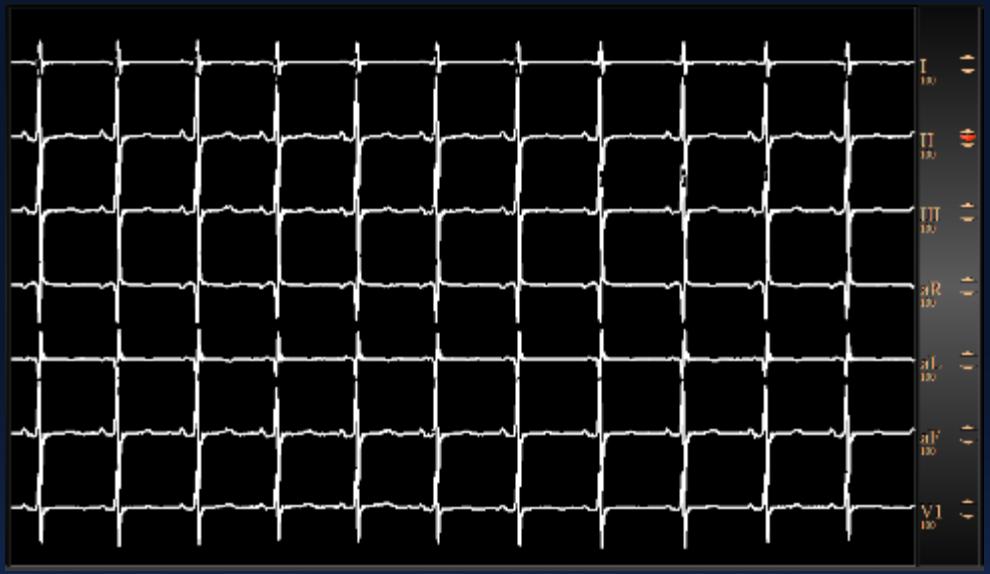


Intracoronary injection of 10cc 0.9% NaCl

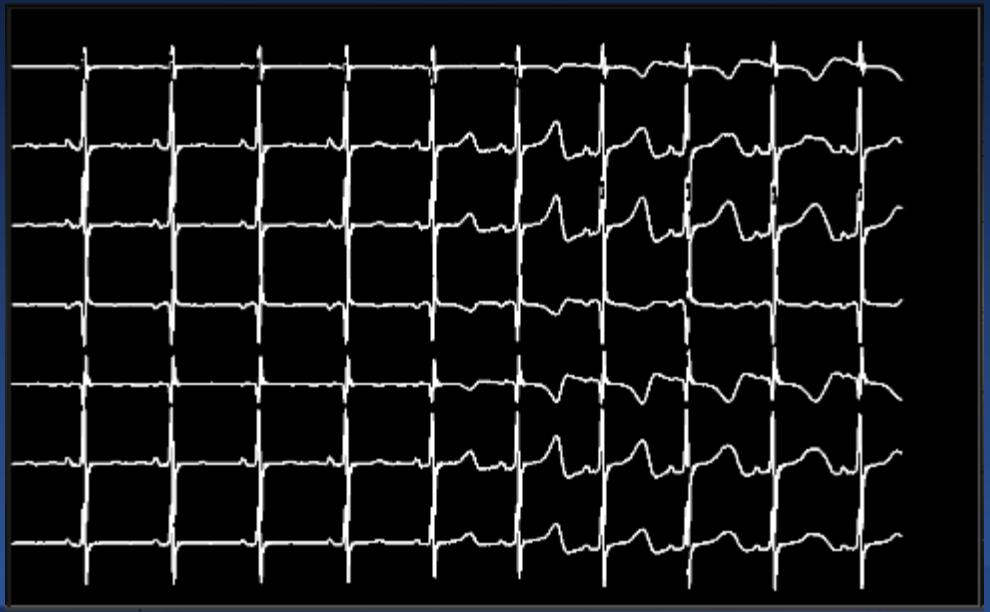

# Ultra-low Contrast Angiography

- CV/eGFR< 1
- GFR 13 ➔ Absolute contrast limit 13mL

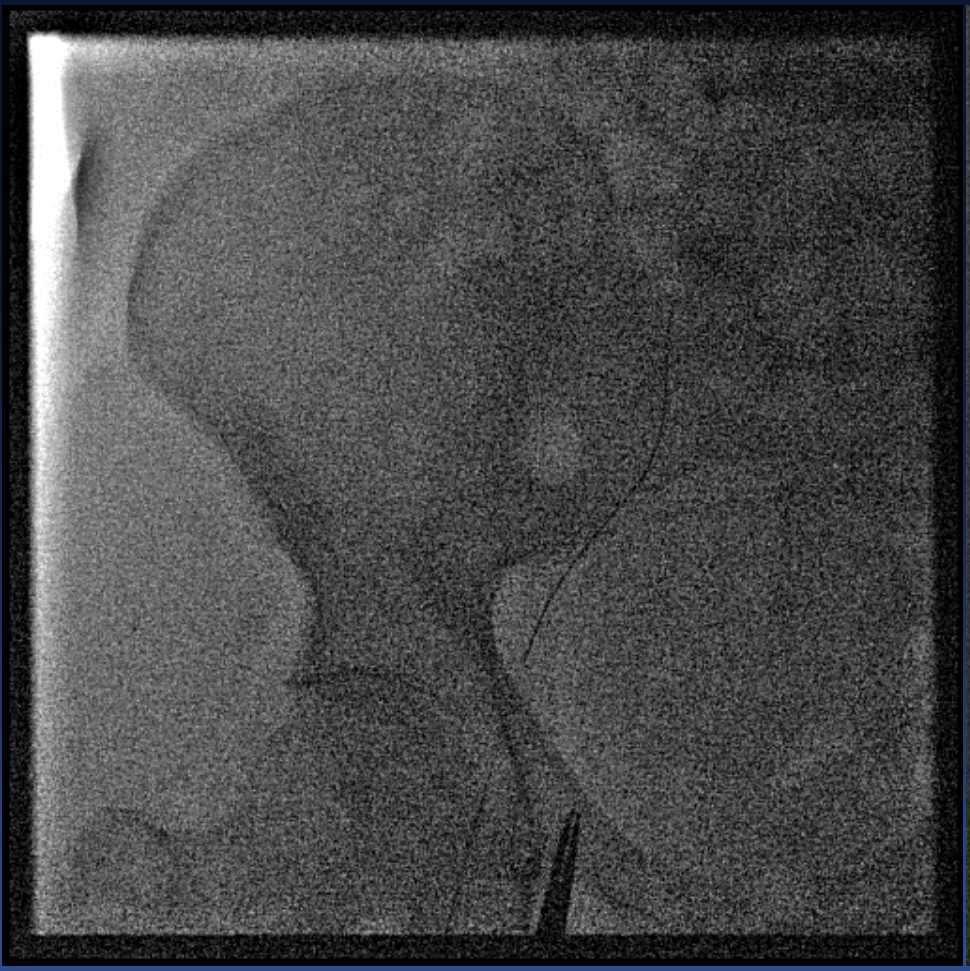

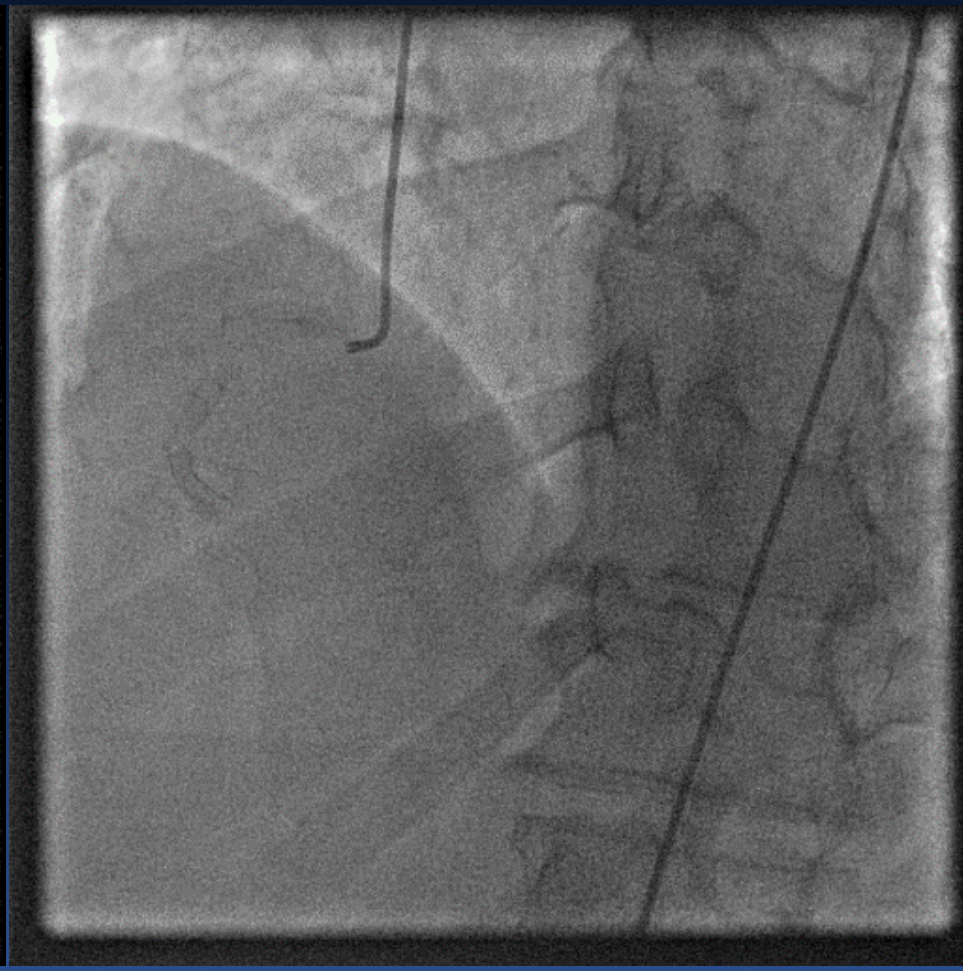

- US guided groin access with micropuncture
- RCA 2.9mL

# Angiography

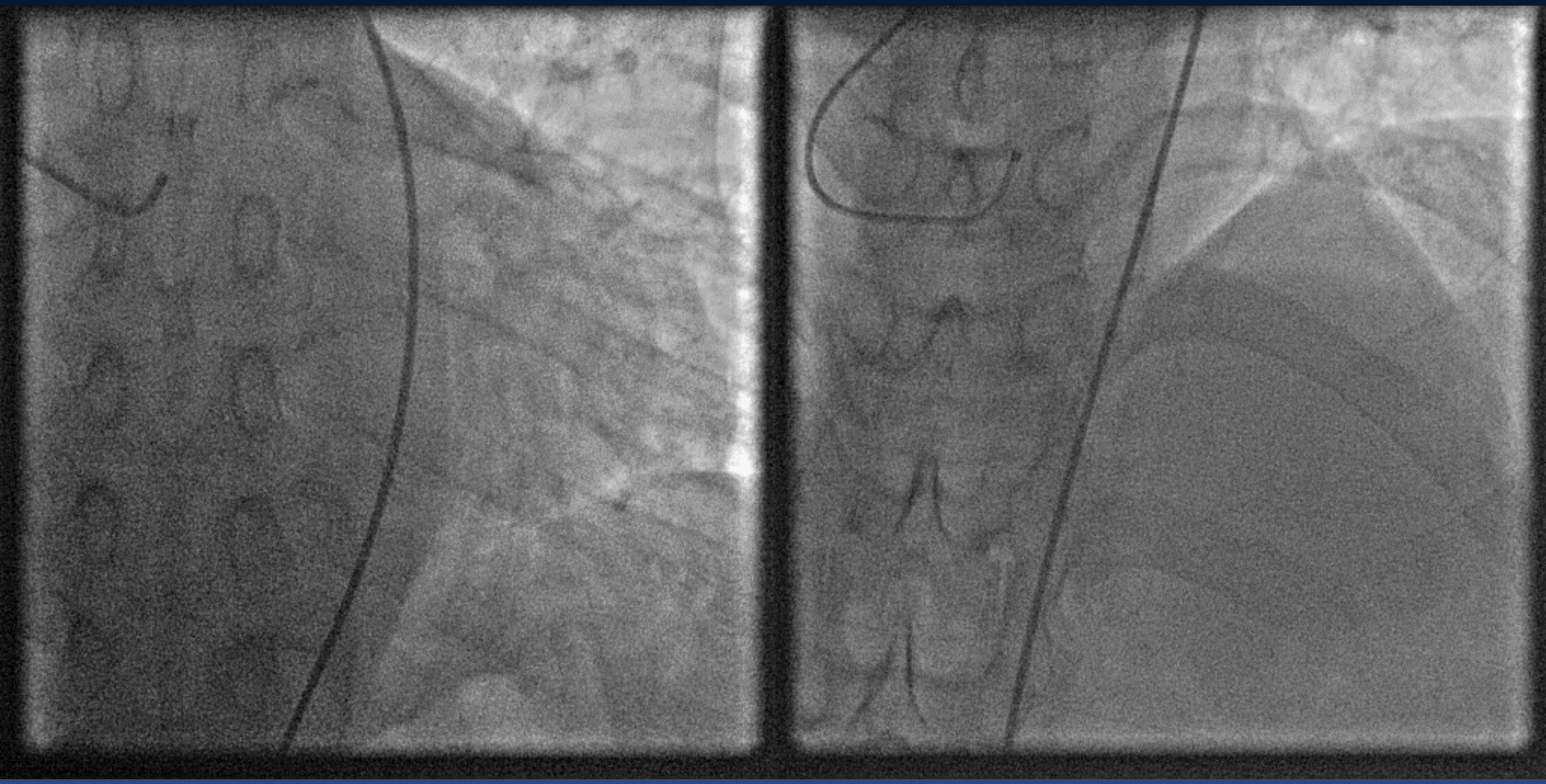

AP/CAU 3.1mL

AP/Cr 3mL

Total Contrast 9mL

# Multi-vessel disease?

# RCA

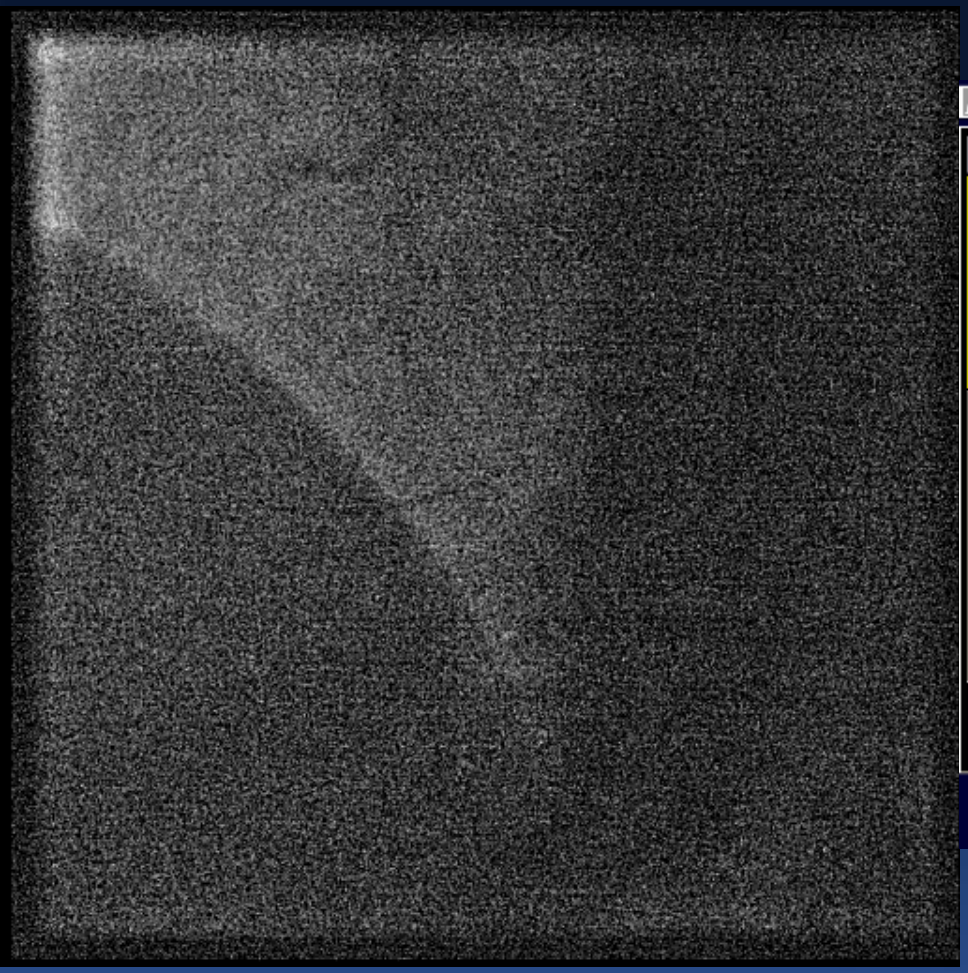

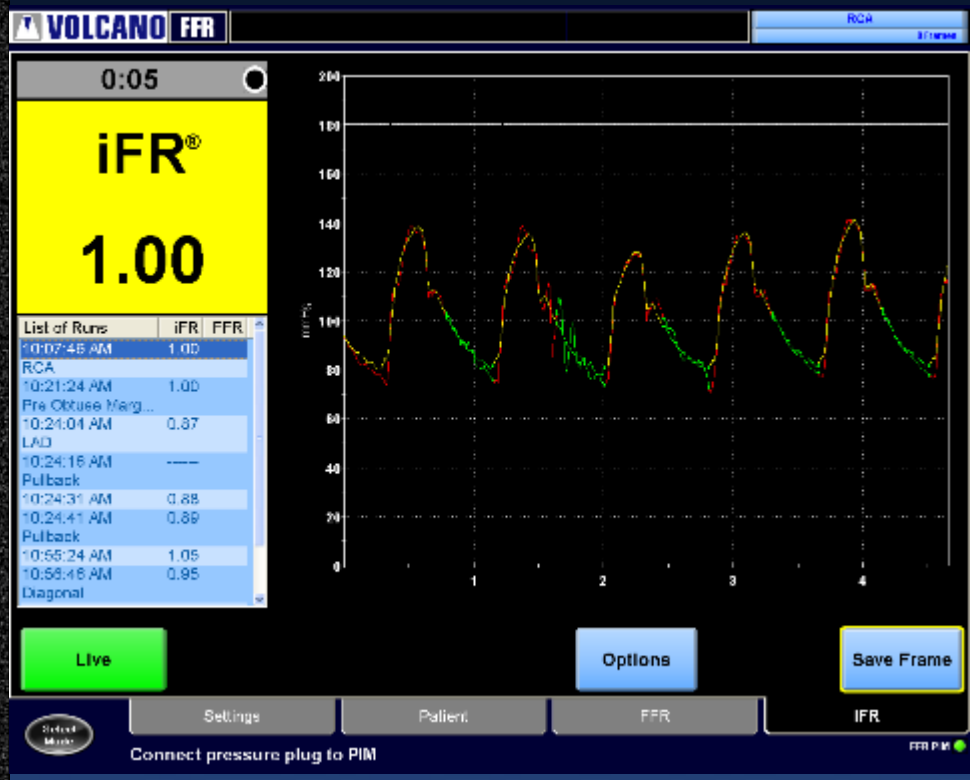


- RCA iFR 1.00

# Cx

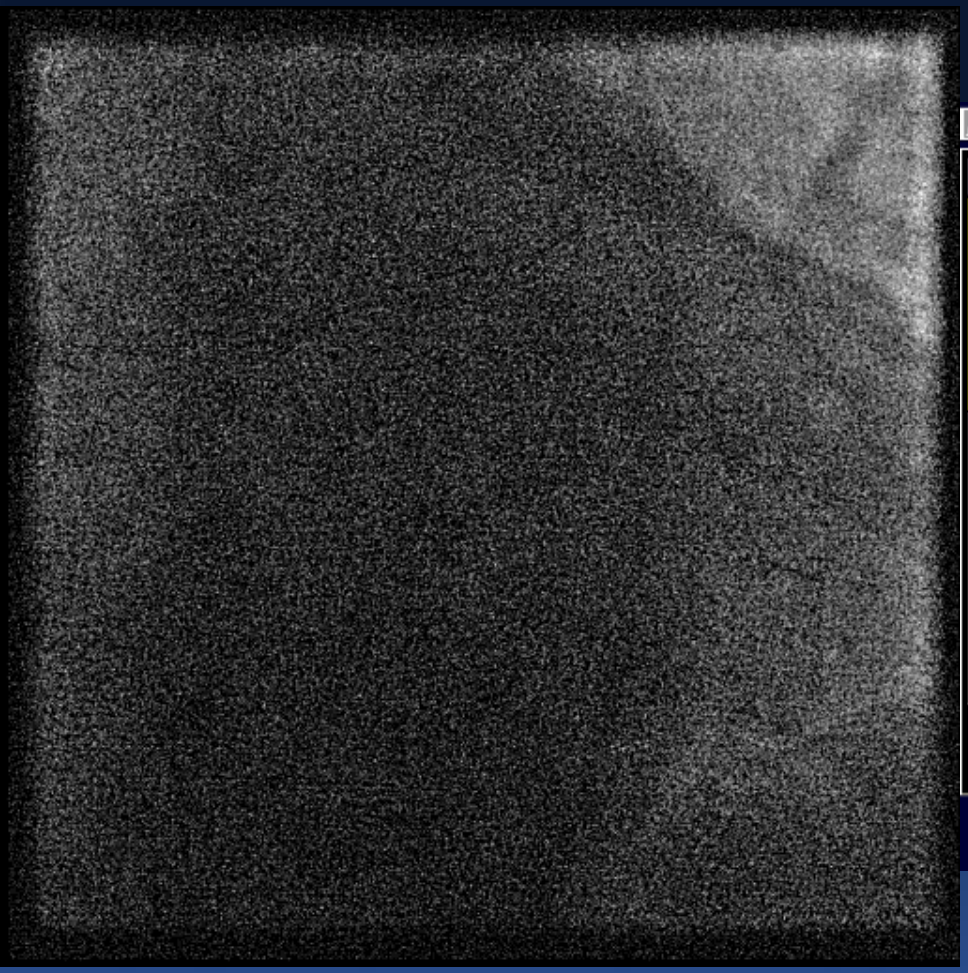

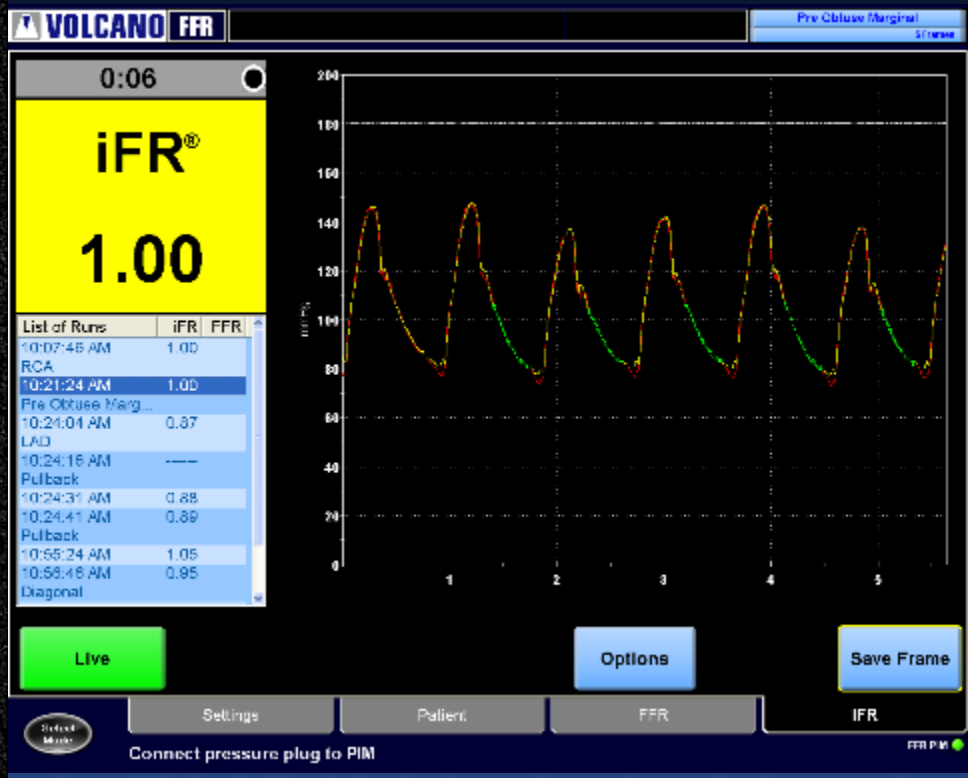
VOLCANO FFR
Pre Obtuse Marginal
0:06
iFR®
1.00
List of Runs iFR FFR
10:07:46 AM 1.00
RCA
10:21:24 AM 1.00
Pre Obtuse Marg...
10:24:04 AM 0.87
LAD
10:24:16 AM ----
Pullback
10:24:31 AM 0.88
10:24:41 AM 0.89
Pullback
10:55:24 AM 1.05
10:56:46 AM 0.95
Diagonal
Live
Options
Save Frame
Settings
Patient
FFR
IFR
Connect pressure plug to PIM

- Cx iFR 1.00

# LAD

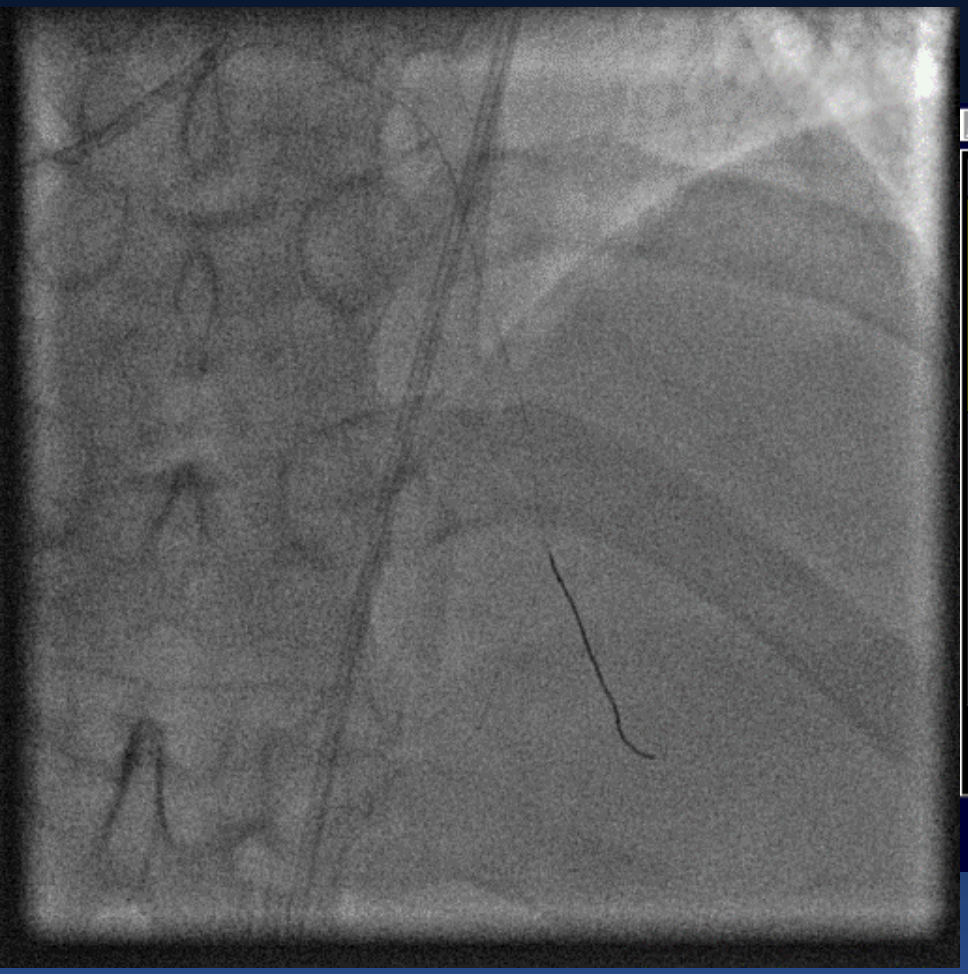

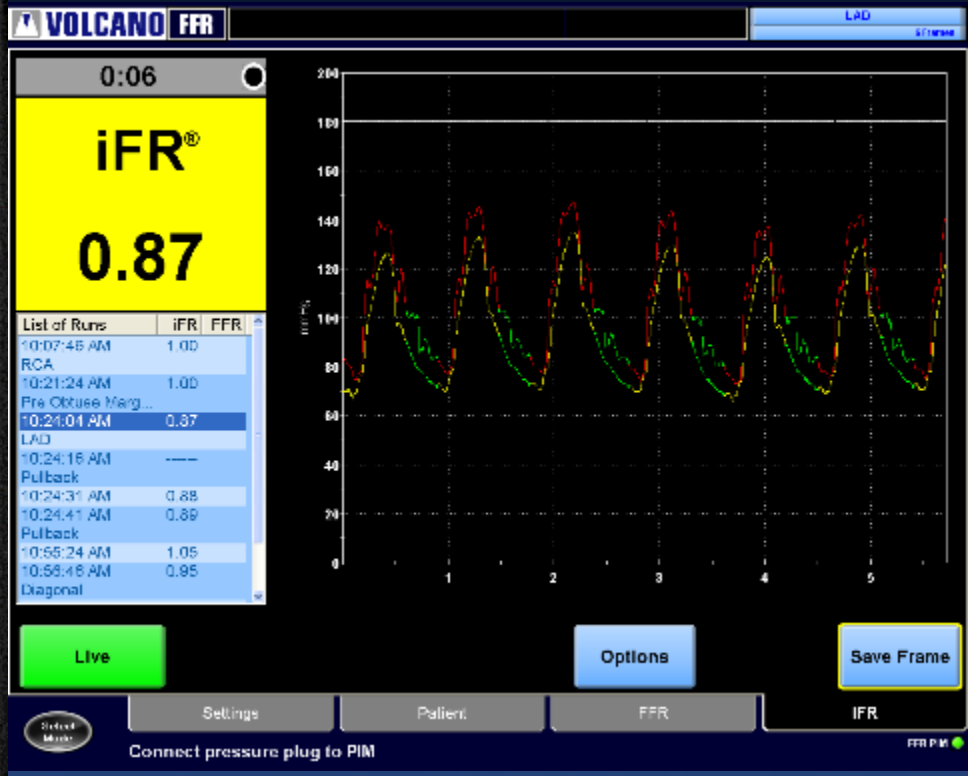


- LAD iFR 0.87

# LAD Pullback



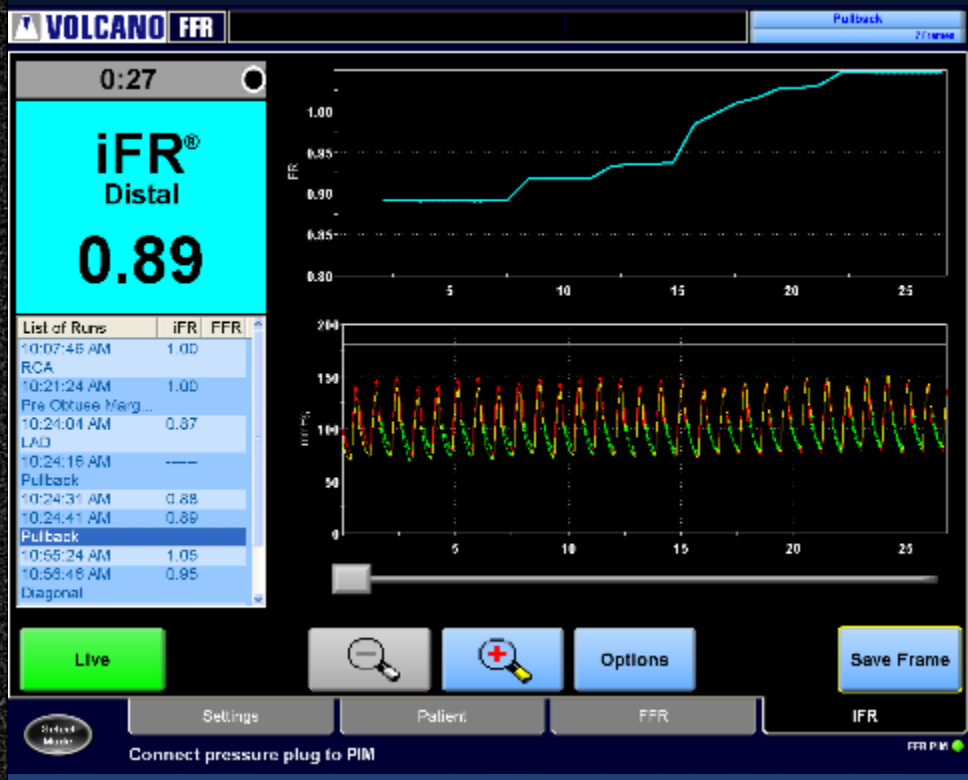


- iFR pullback shows discrete lesion

# IVUS Co-registration

At the distal reference, dry cine angiogram is recorded

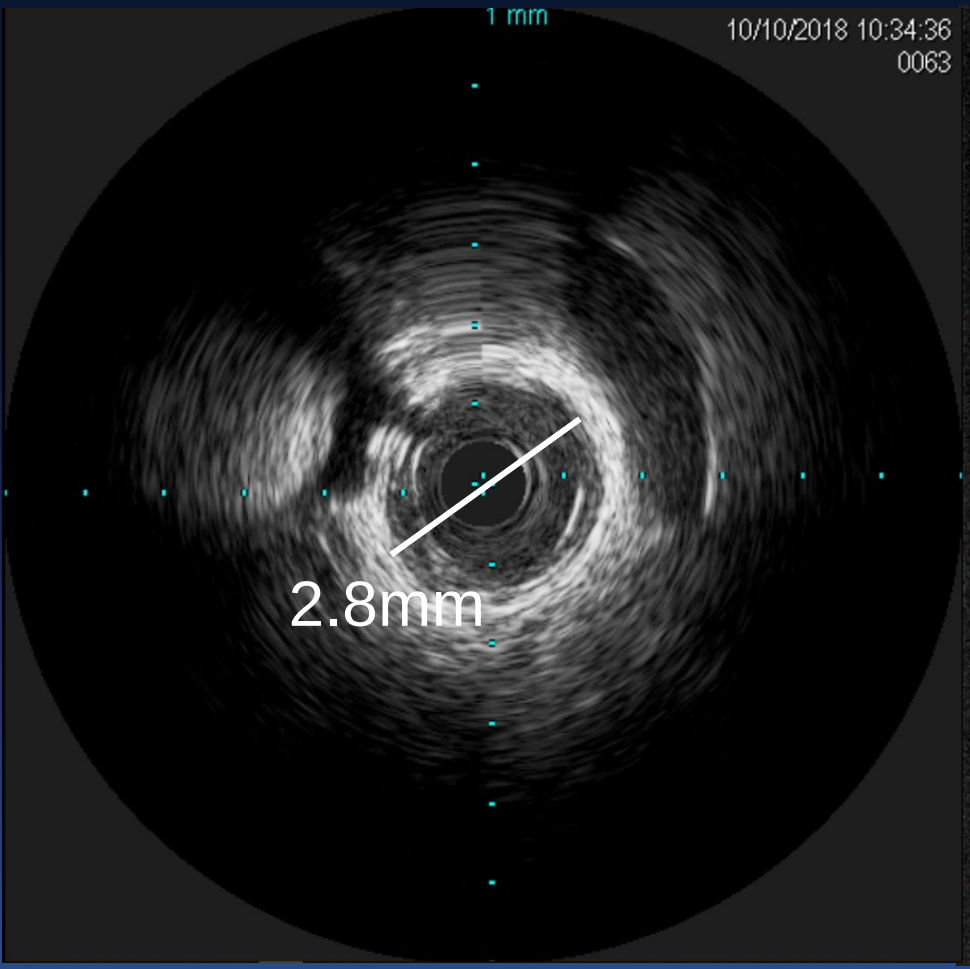


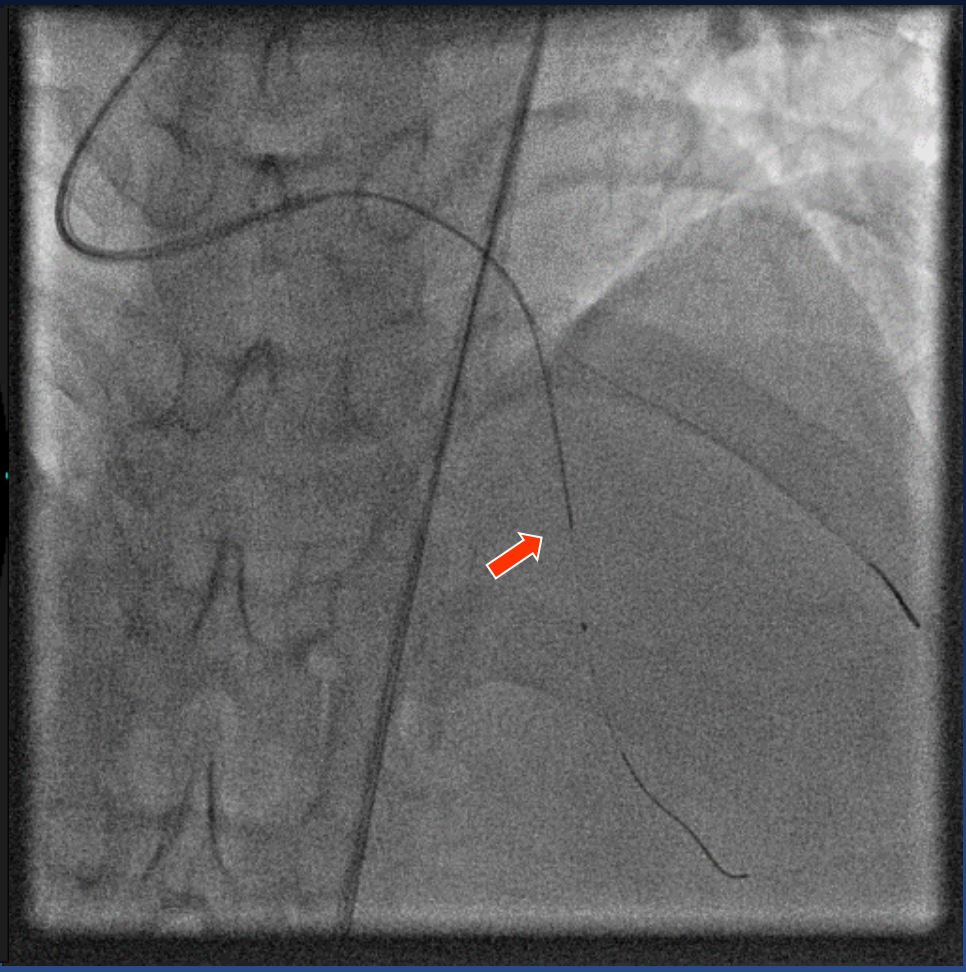

IVUS measures distal reference EEL-EEL 2.8mm

# Imaging-guided Stent Sizing

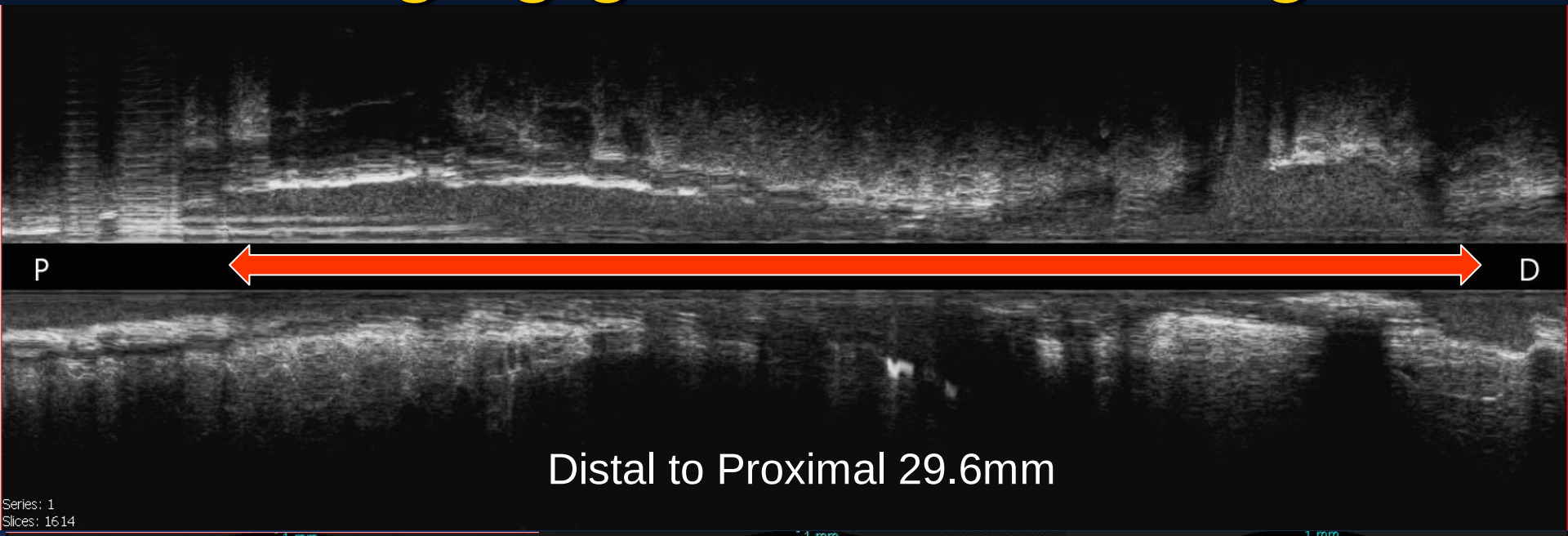


Distal to Proximal 29.6mm

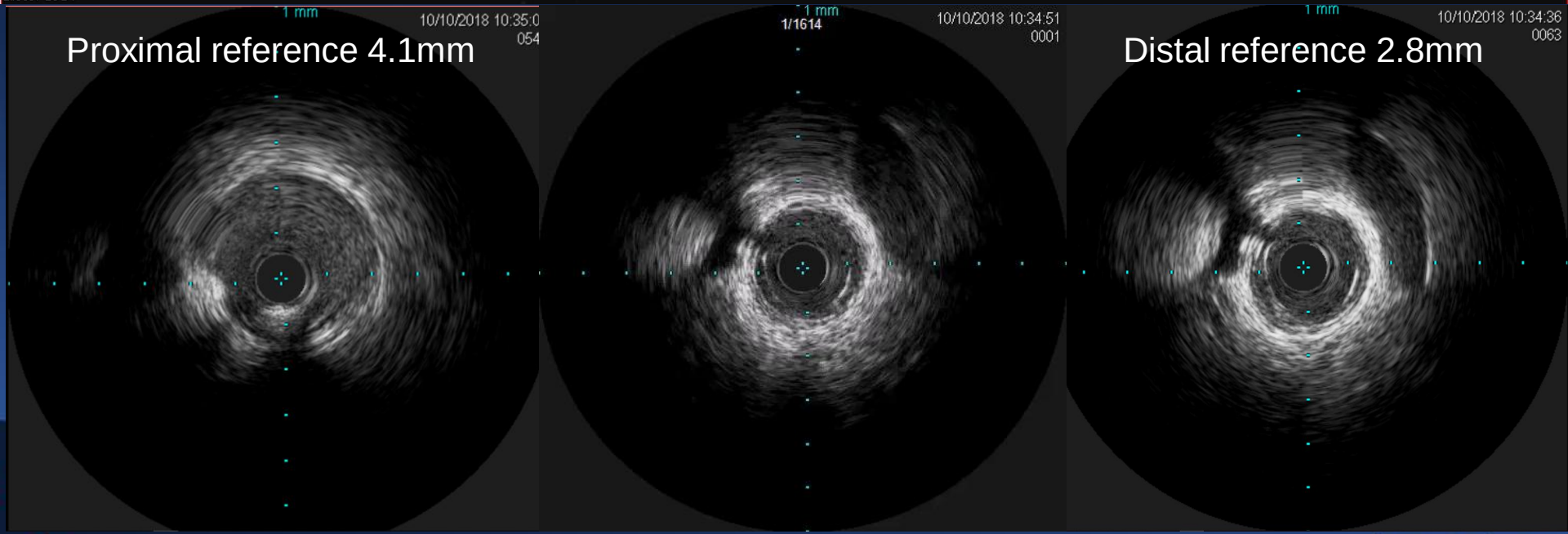


Proximal reference 4.1mm

Distal reference 2.8mm

# Stent Deployment

Distal reference IVUS cine used as roadmap for co-registration

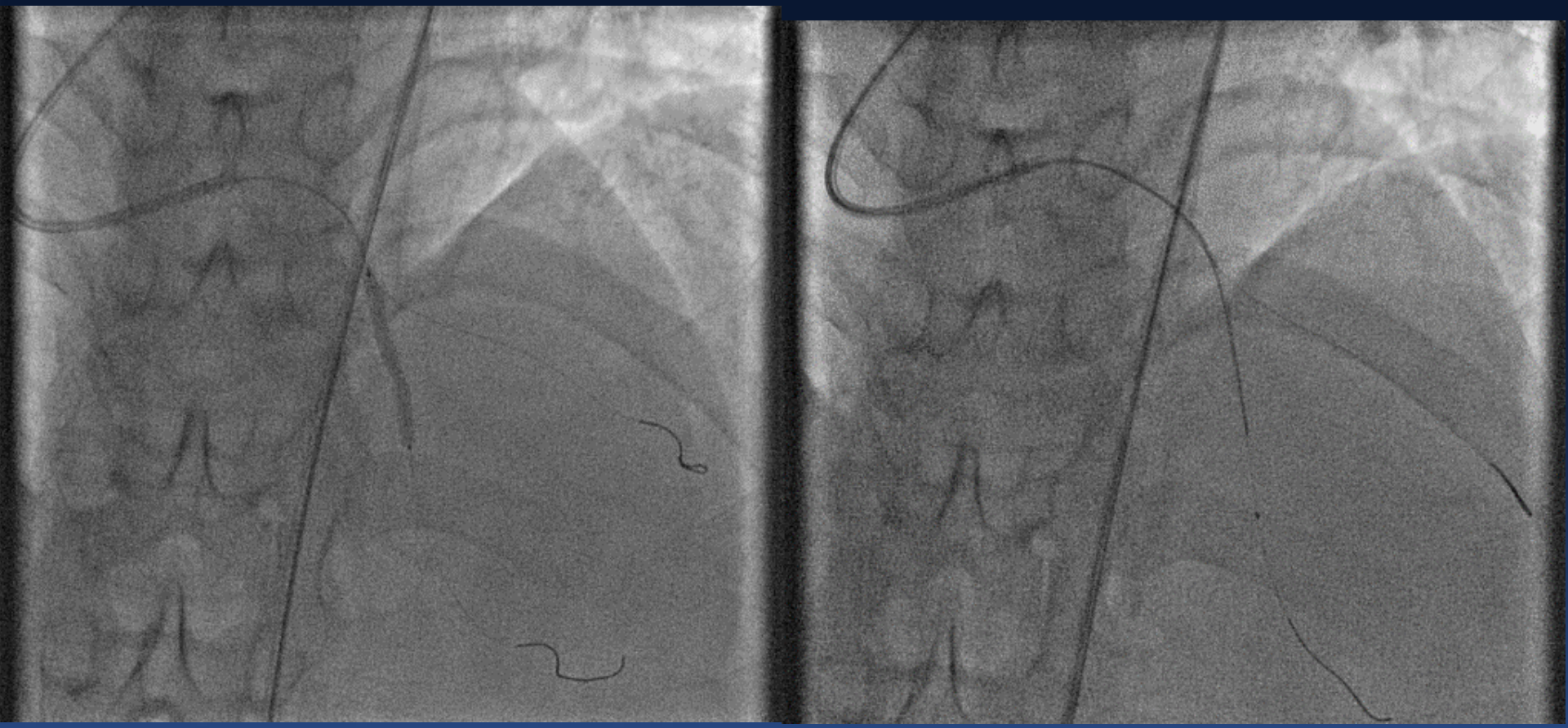

2.5x30 DES deployed at 12 atmospheres

# PCI Optimization

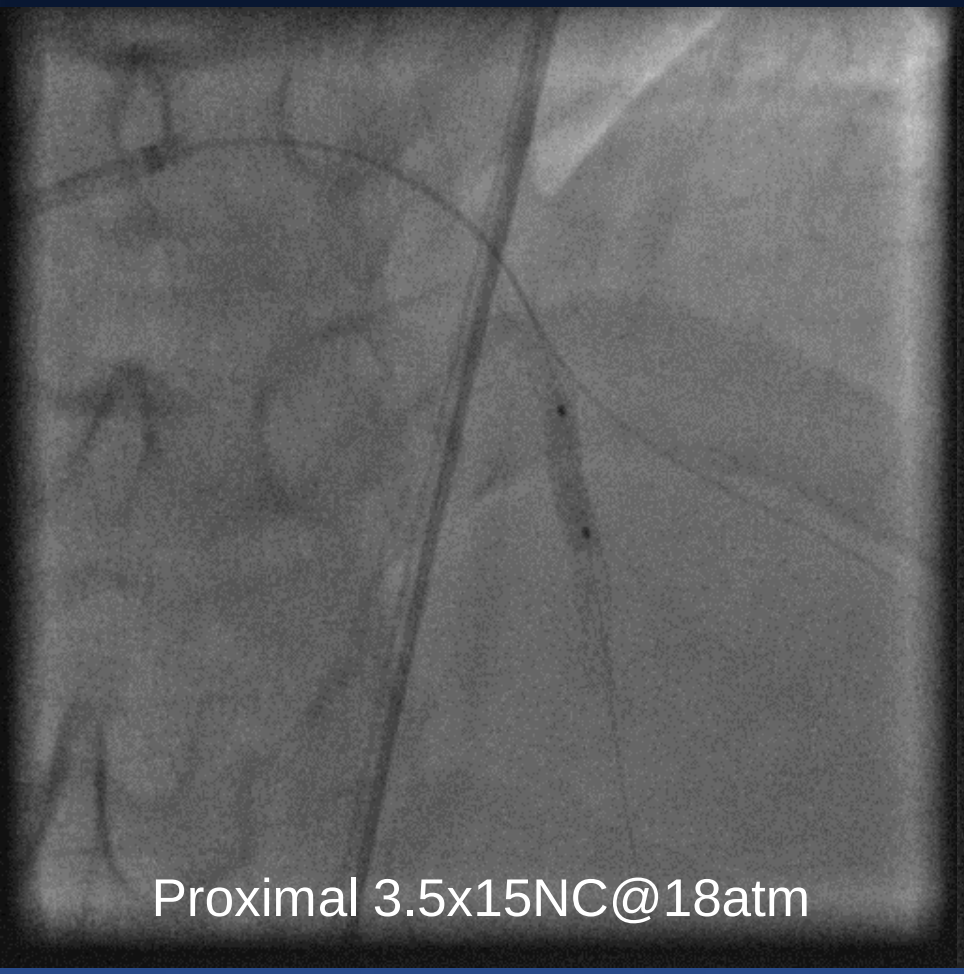


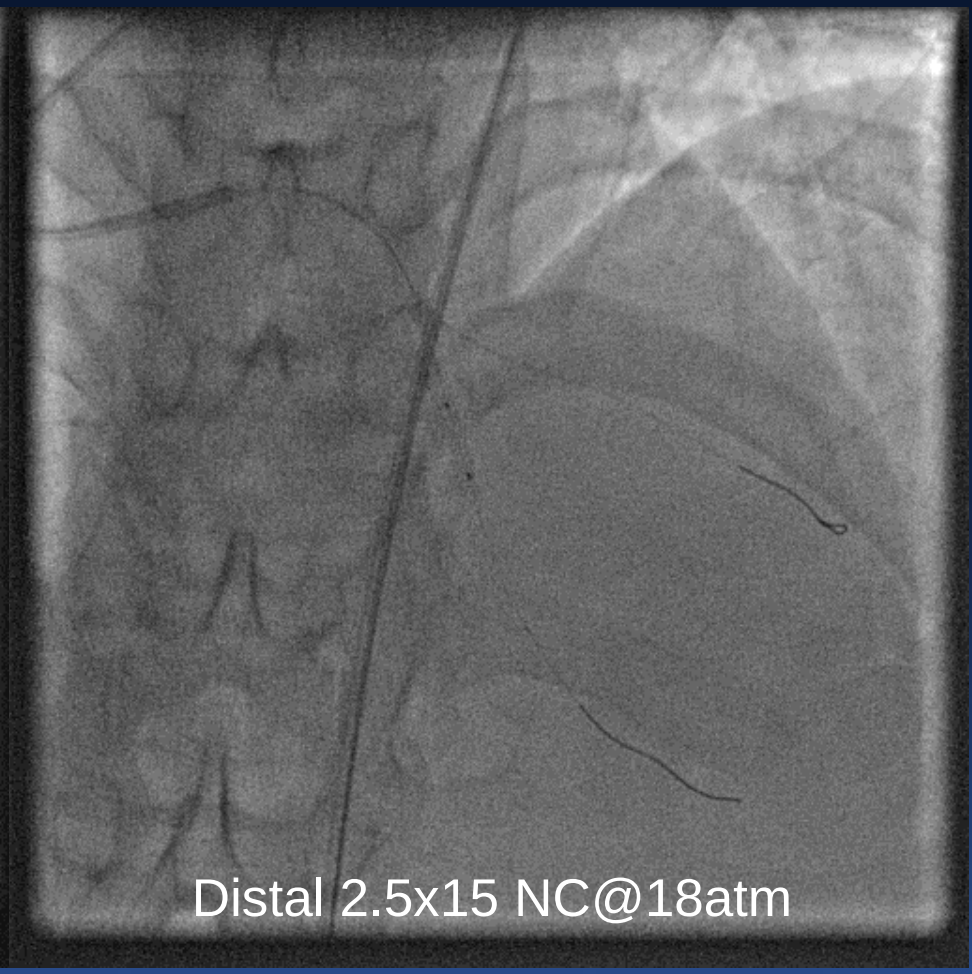

# Imaging-guided Optimization

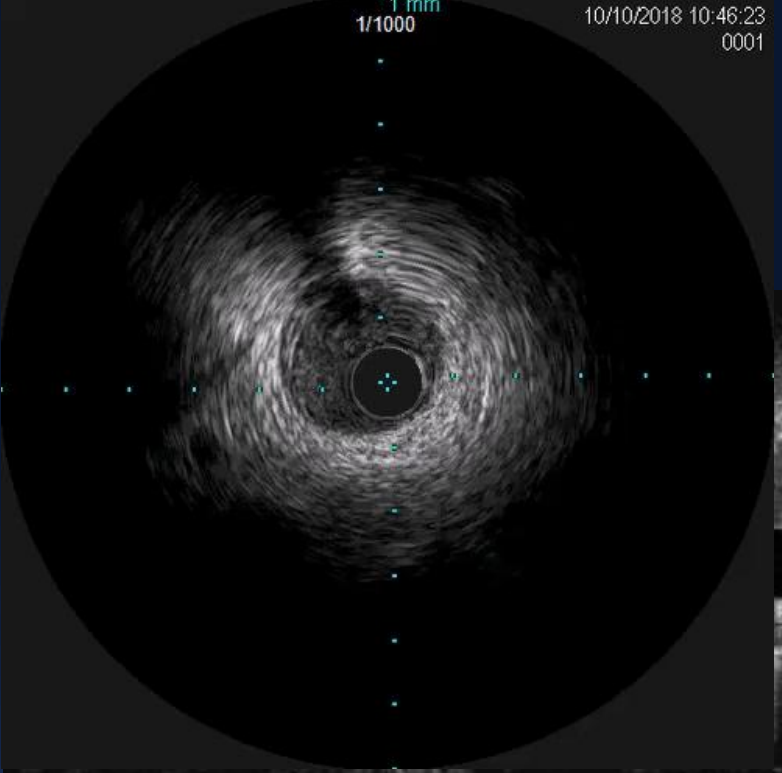


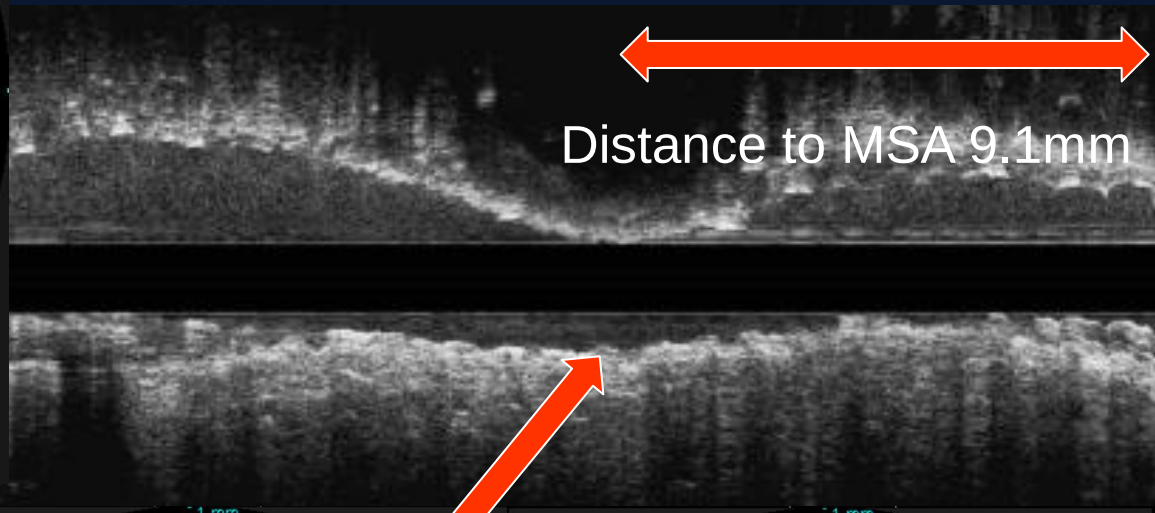


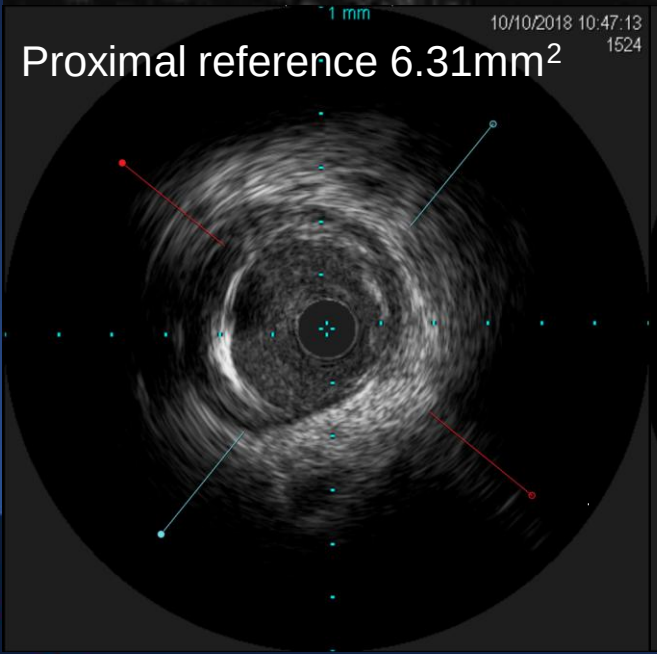


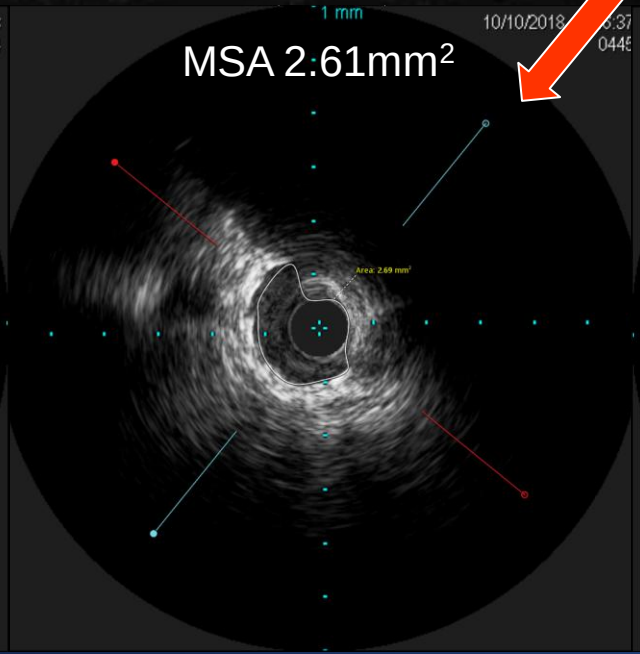


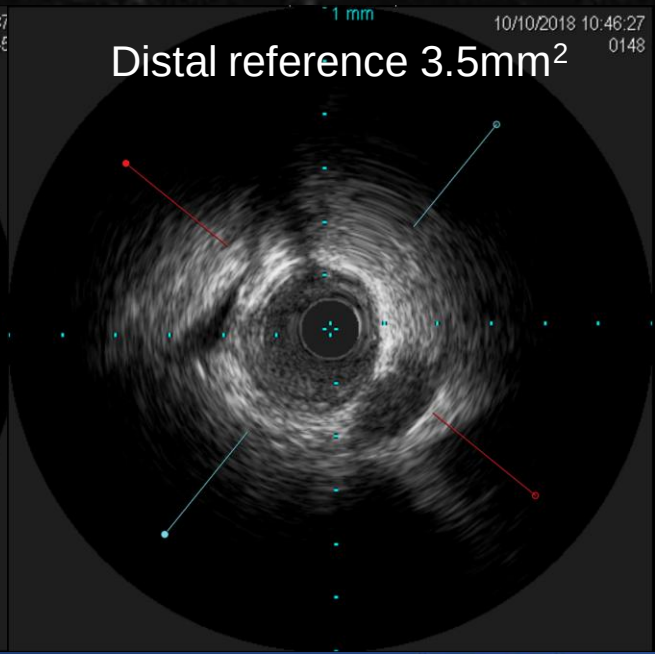

# Targeted Optimization

Targeted optimization is performed of the distal segment of stent

2.75x15 NC balloon deployed at 20 atmospheres

# Post PCI-Physiology D1

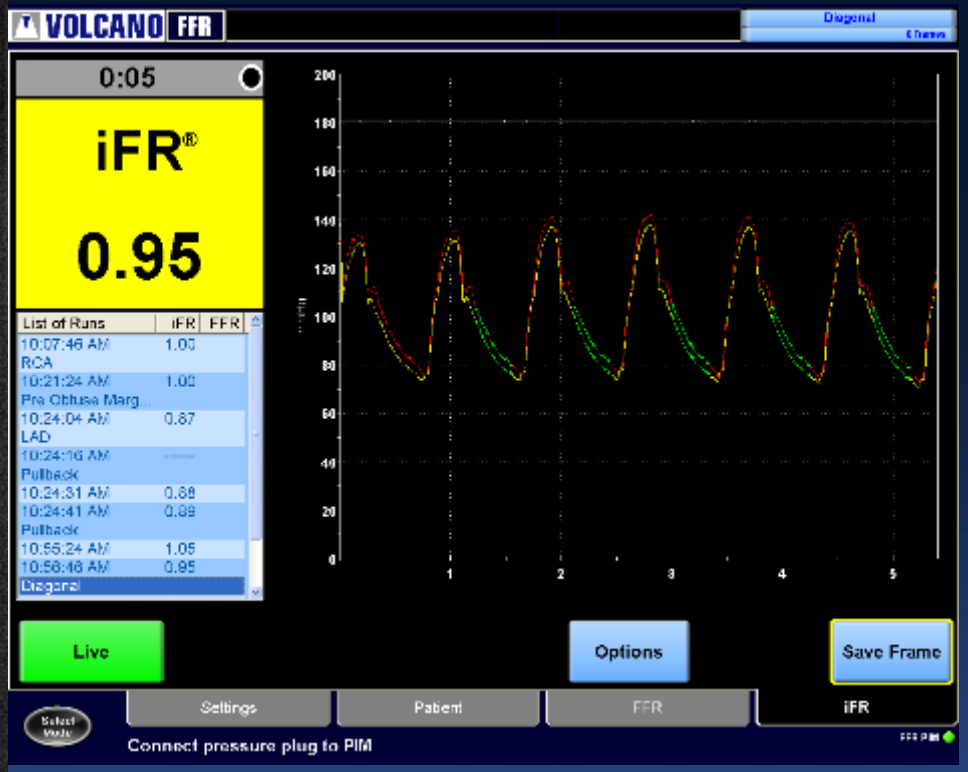


IVUS confirms expansion, apposition and absence of protrusion, dissection

# Post PCI-Physiology LAD

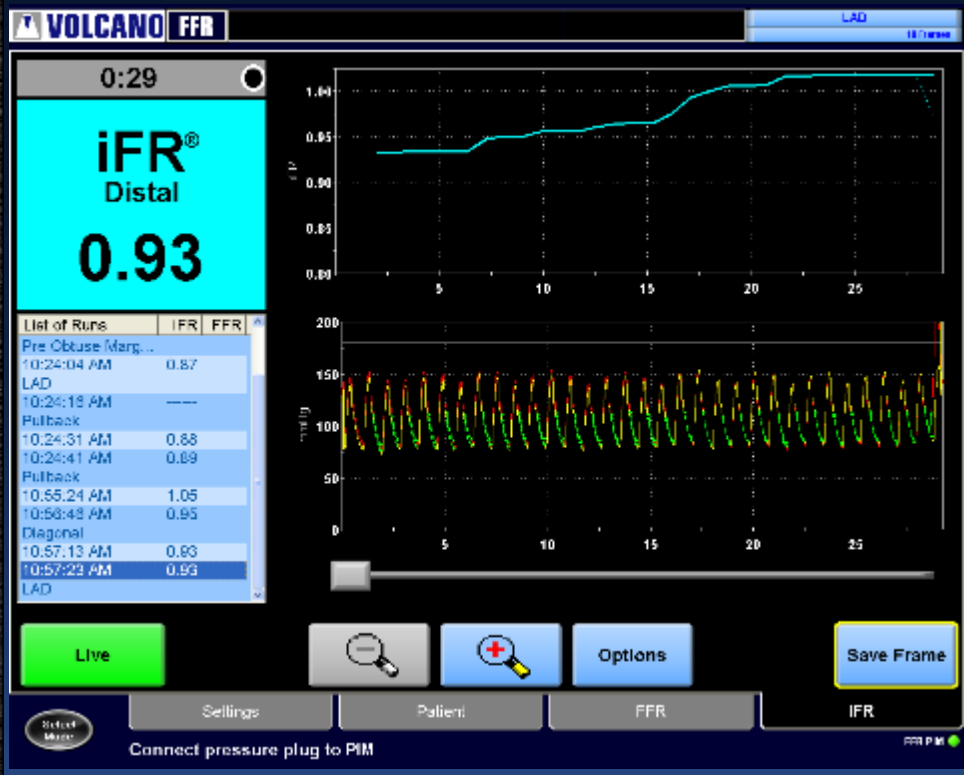

# Completion of PCI procedure

Post-PCI LVEDP guides hydration

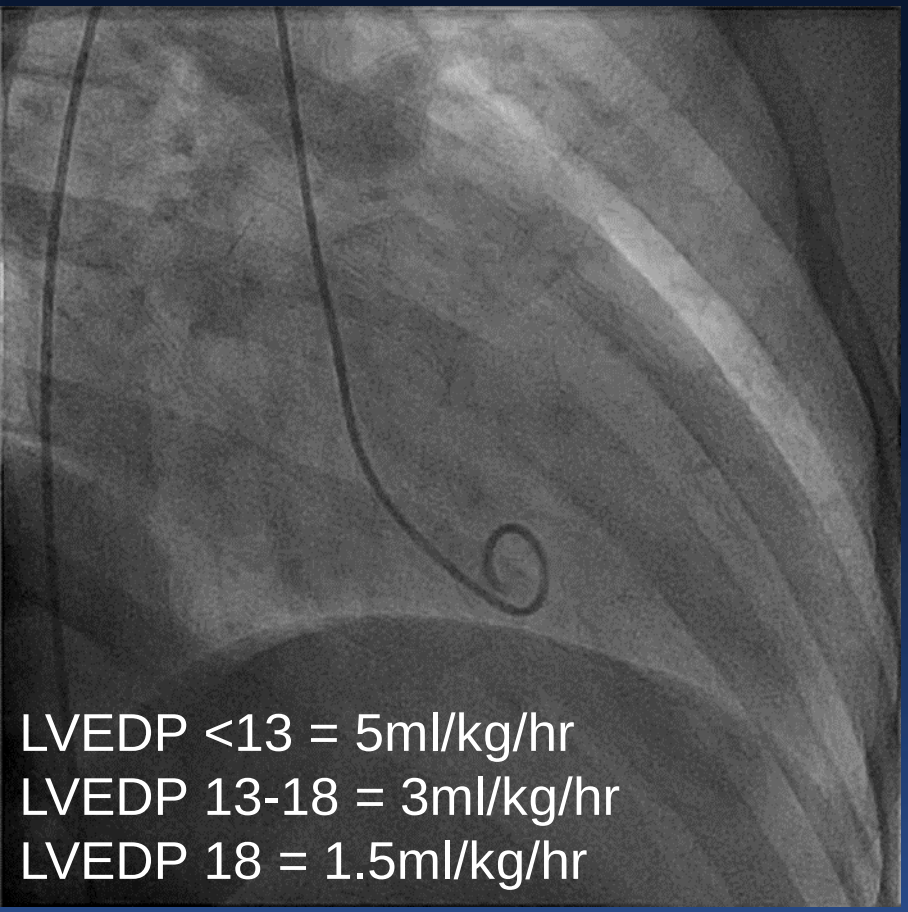


Brar et al. POSEIDEN. Lancet 2014

If post-procedure there are;

a) Symptoms
b) EKG Changes
c) New effusion

Limited angiography is performed.

TTE to rule out new effusion

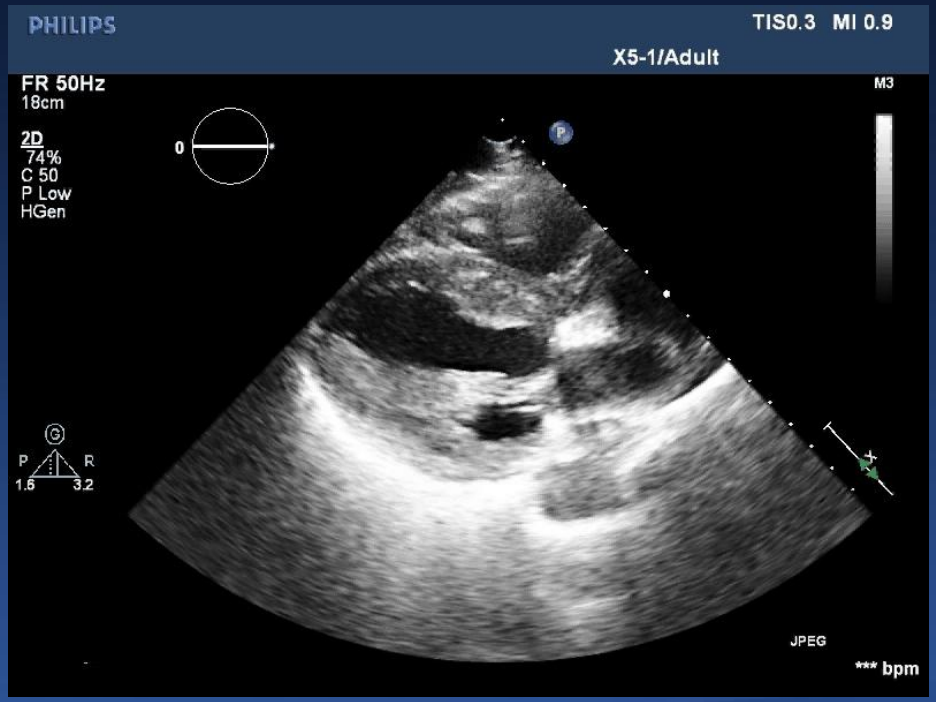

# Imaging and Physiology Outcomes

| PCI, physiology, IVUS, and follow-up data | |
|---|---|
| Guide wires | 3 [3, 4] |
| Lesion length (mm) | 22 [16, 38] |
| Number of stents | 1 [1, 1] |
| Total stent length (mm) | 22 [16, 38] |
| Stent diameter (mm) | 3 [3, 3.5] |
| Pre-dilation | 25 (81) |
| Post-dilation | 30 (97) |
| Minimal stent area ($mm^2$) | 6.8 [5.9, 8.3] |







Cardiovascular Research Foundation

Ali et al. Eur Heart J. 2016;37(40):3090-3095.

Columbia University Medical Center
NewYork-Presbyterian

# Pre-specified criteria for angiography

Post-procedure;

a) Symptoms
b) EKG Changes
c) CFR <1.8
d) Ischemic FFR
e) New effusion

# Acute Clinical Outcomes

- No patient received contrast during PCI

| PCI, physiology, IVUS, and follow-up data | |
|---|---|
| Procedure time (min) | 72 [61, 119] |
| Fluoroscopy time (min) | 20 [16, 35] |
| Radiation dose (mGy) | 1154 [538, 1932] |
| Follow-up (days) | 79 [33, 207] |
| Follow-up eGFR (mL/min/1.73 $m^2$) | 18 [14, 22] |
| Change in eGFR (mL/min/1.73 $m^2$) | −0.2 [−1.4, 1.8] |
| Renal replacement therapy | 0 (0) |
| Stent thrombosis | 0 (0) |
| Revascularization | 0 (0) |
| MI | 0 (0) |
| Death | 0 (0) |

Ali et al. Eur Heart J. 2016;37(40):3090-3095.

# Propensity Matched Analysis (6-months)

1:1 Propensity matching according to Mehran criteria for CIN Risk

| | Zero Contrast (n=40) | Standard (n=29) | *P* |
|---|---|---|---|
| **Contrast Nephropathy** | 0 (0%) | 17 (58%) | <.001 |
| **Renal Replacement Rx, n (%)** | 0 (0%) | 8 (27%) | <.001 |
| **MACE** | 0 (0%) | 6 (20%) | 0.02 |
| Stent Thrombosis | 0 (0%) | 0 (0%) | |
| Repeat Revascularization | 0 (0%) | 3 (10%) | 0.06 |
| Myocardial Infarction | 0 (0%) | 1 (3.4%) | 0.40 |
| Death | 0 (0%) | 2 (6.9%) | 0.16 |

Ali et al. Eur Heart J. 2016;37(40):3090-3095.

# 1-year Clinical Outcome

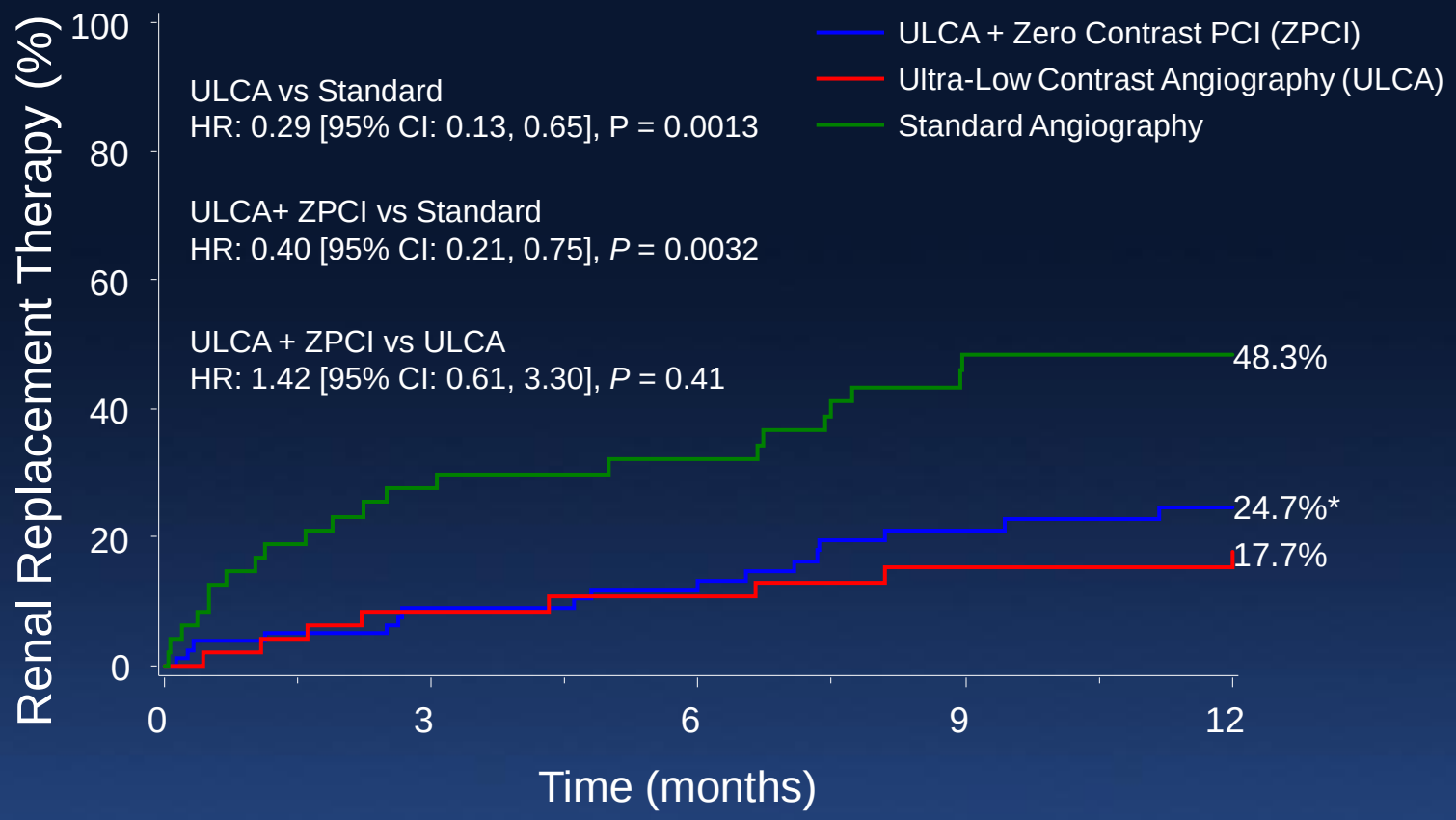


| *Number at risk:* | | | | | |
|---|---|---|---|---|---|
| ULCA + ZPCI* | 82 | 66 | 58 | 47 | 37 |
| ULCA | 51 | 43 | 39 | 36 | 35 |
| Standard Angiography | 50 | 33 | 30 | 21 | 21 |

*Indirect comparison

# Zero-contrast Rota-PCI



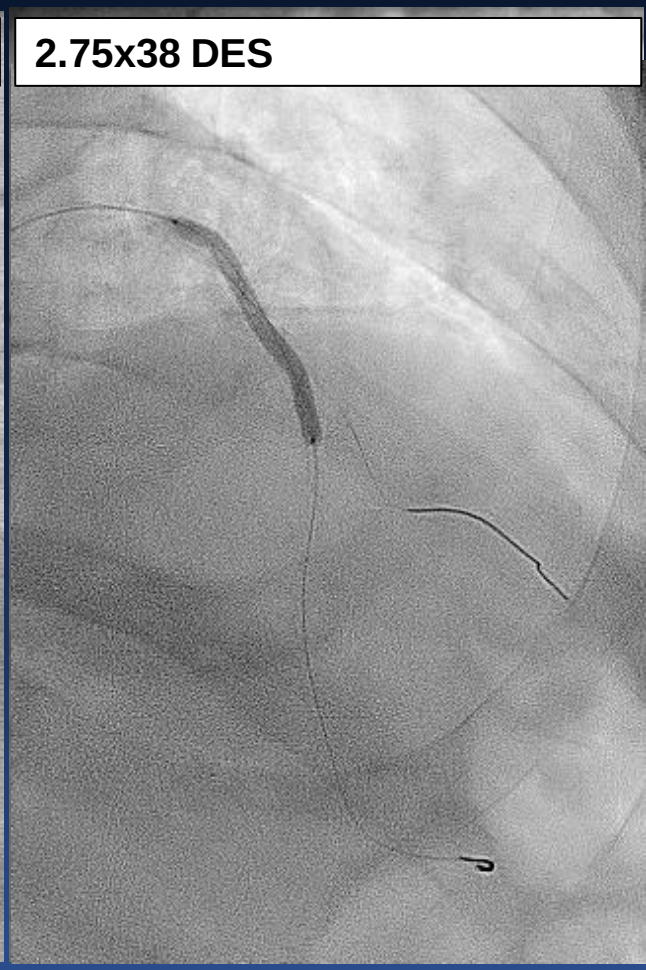




Galougahi and Ali. CCI. 2017;90(4):E85-E89

# Zero-contrast CTO-PCI

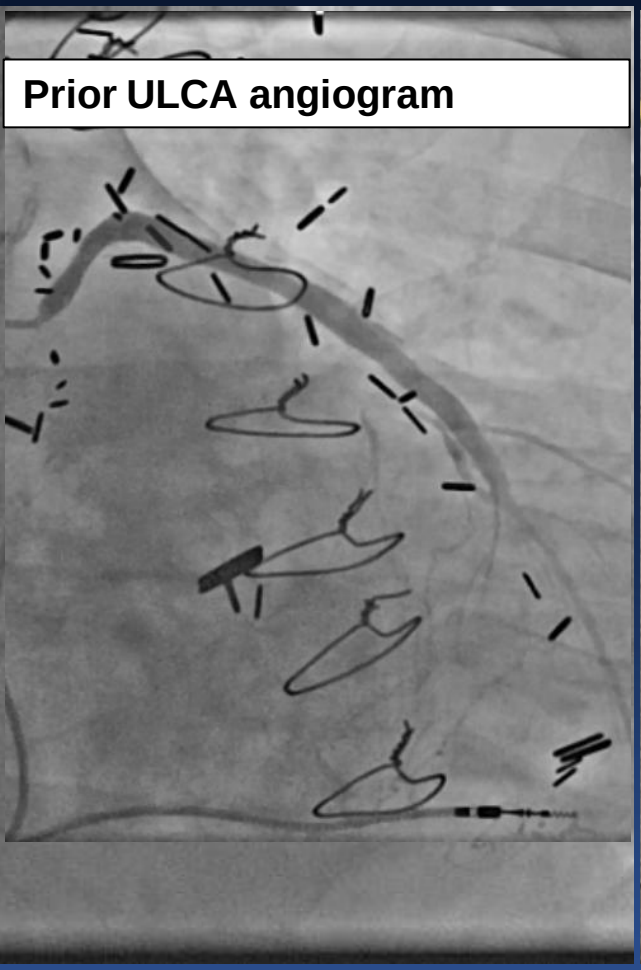


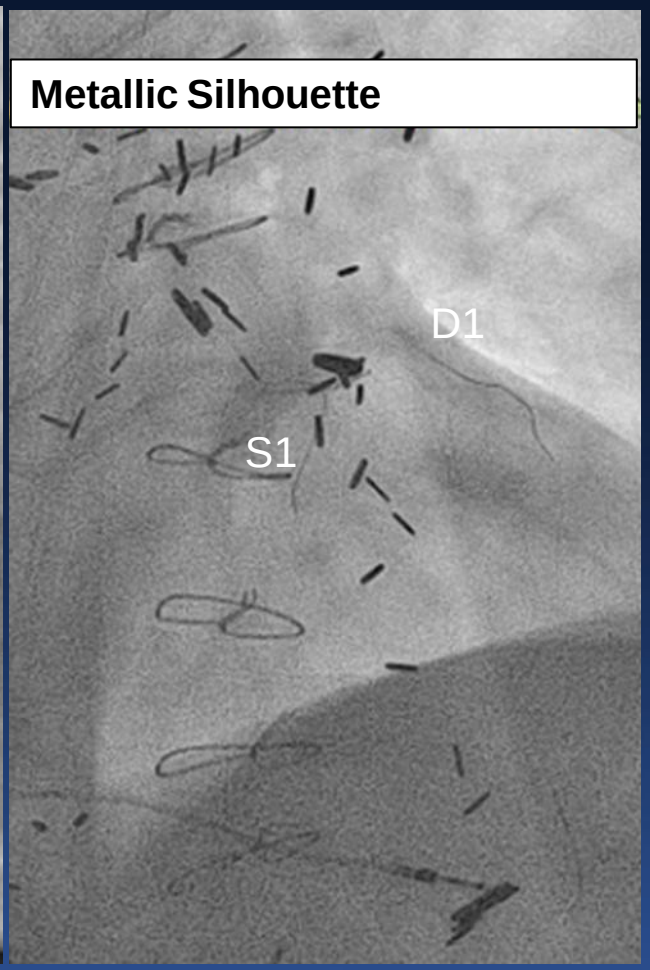





Karmpaliotis and Ali. EHJ Case Rep. 2018 Apr 2;2(2):1-5.

# Zero contrast Vein Graft PCI

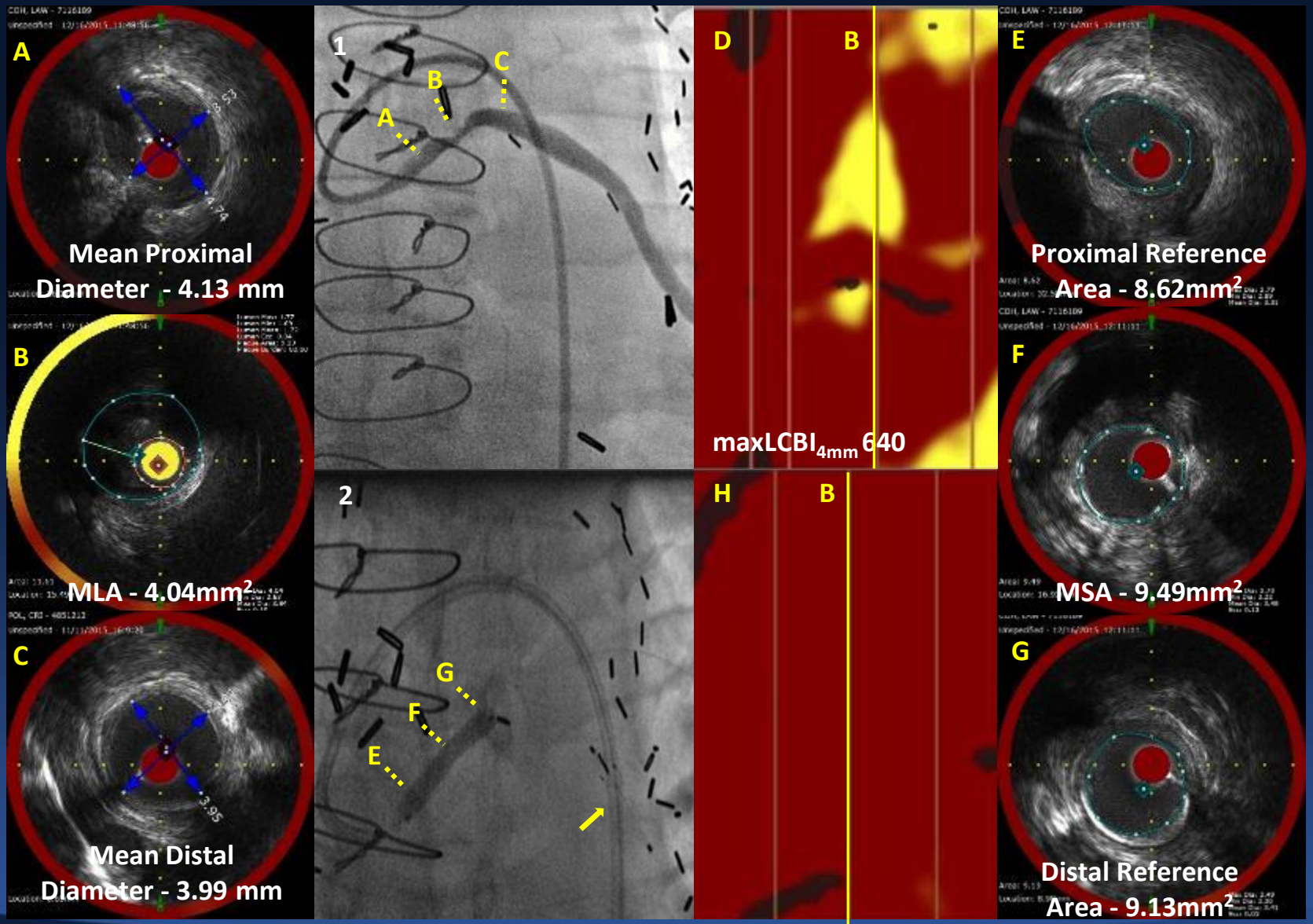


Parvis and Ali. J Invasive Cardiol. 2017 Nov;29(11):E163-E165

# Zero contrast CHIP PCI


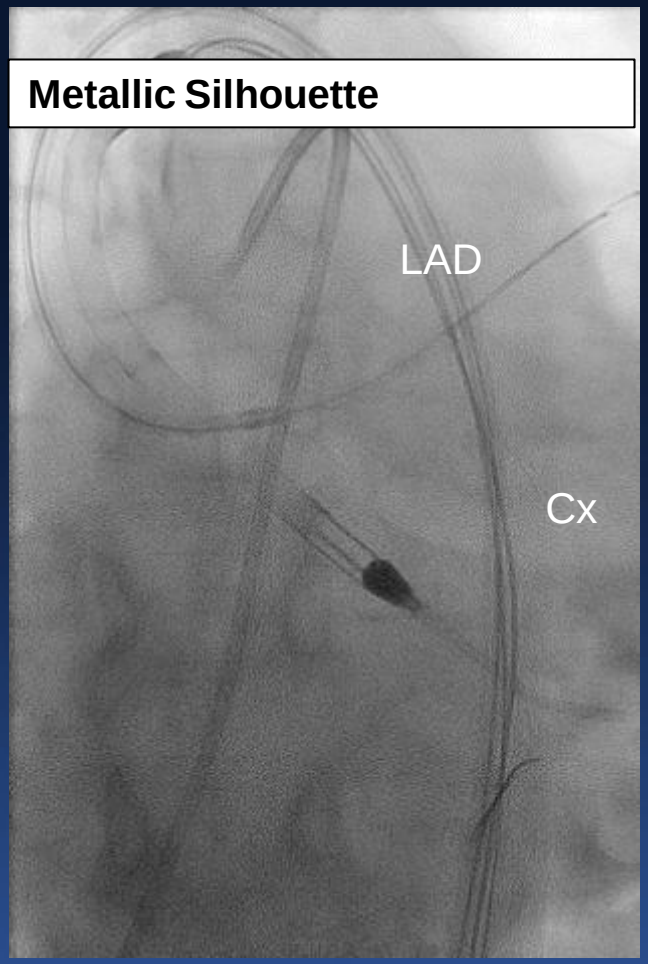


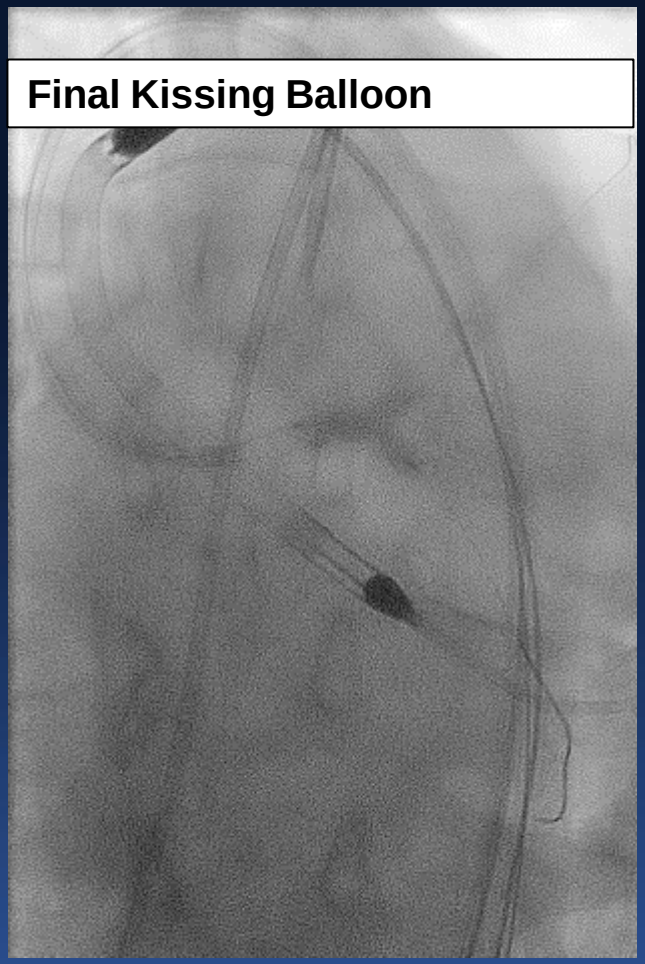

# Zero contrast PCI: Step-by-Step

Karmpaliotis and Ali. TCT 2018, https://www.tctmd.com/videos/54077.5842942059001

# What's Next?

# OCT Co-registration Guided Zero Contrast PCI

CARDIOVASCULAR FLASHLIGHT

doi:10.1093/eurheartj/ehv667
Online publish-ahead-of-print 18 December 2015

## Optical coherence tomography-guided percutaneous coronary intervention in pre-terminal chronic kidney disease with no radio-contrast administration

**Keyvan Karimi Galougahi[1,2], Adrian Zalewski[1], Martin B. Leon[1,3], Dimitri Karmpaliotis[1,3], and Ziad A. Ali[1,3]***

[1]Division of Cardiology, Center for Interventional Vascular Therapy, New York Presbyterian Hospital and Columbia University, New York, NY, USA; [2]Sydney Medical School Foundation, University of Sydney, Australia; and [3]Cardiovascular Research Foundation, New York, NY, USA

* Corresponding author. Tel: +1 212 3057060, Email: zaa2112@columbia.edu

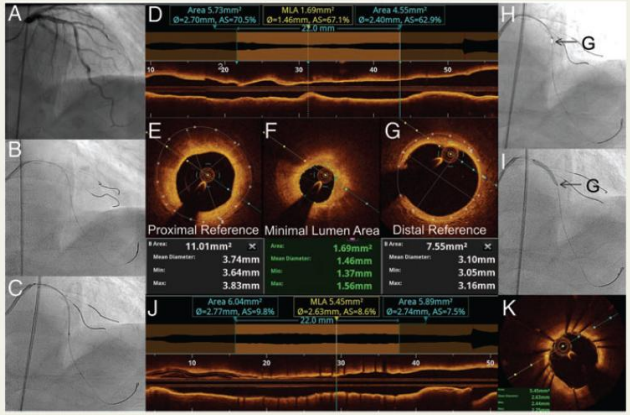


A 67-year-old man with advanced chronic kidney disease (CKD) (creatinine = 4.5 mg/dL, eGFR = 13 mL/min/1.73 $m^2$) not requiring haemodialysis presented with progressive angina. Diagnostic angiography with ultra-low radio-contrast volume (12 mL, contrast volume/eGFR ratio <1) revealed significant stenosis in the left anterior descending (LAD) artery (*Panel A*). The lesion was haemodynamically significant (fractional flow reserve: 0.77). Post-angiography, the renal function remained stable. A staged percutaneous coronary intervention (PCI) was performed without utilizing radio-contrast medium. Previous angiographic images were used to guide catheter engagement and guidewire placement in the LAD and diagonal arteries, thus creating a metallic silhouette of the artery (*Panel B*). Repeat physiological assessment confirmed haemodynamic significance [FFR: 0.78, coronary flow reserve (CFR): 1.4]. Optical coherence tomography (OCT) with angiographic co-registration (OptisI, St Jude Medical, MA) was performed using a mixture of saline and colloid infusate to displace blood (*Panels C* and *D*). Proximal (*Panel E*) and distal (*Panel G*) reference diameters determined by measuring the distance between respective external elastic laminae and minimal luminal area (*Panel F*) were used for selection of the pre-dilation balloon and stent sizes. An automated angiographic co-registered OCT pullback was used to guide the PCI (*Panels H* and *I*, *G*: distal reference = white bar). Co-registered OCT was repeated to determine minimal stent area (*Panels J* and *K*) and to guide post-dilation. Post-procedure FFR improved to 0.93 and CFR to 3.0. Post-PCI renal function remained stable. This case highlights the feasibility of radio-contrast free OCT-angiographic co-registration guided PCI to prevent contrast-induced nephropathy and requirement for renal replacement therapy in selected extremely high-risk patients with near end-stage CKD.

**Conflict of interest**: D.K. has served as a speaker or a member of the speaker's bureau for Abbott Vascular, Boston Scientific and Medtronic. Z.A.A. is a speaker for and holds grant support from St Jude Medical.



- First Report
- Co-registration
- Automatic measures

Cardiovascular Research Foundation

Ali et al. EHJ. 2016;37:1059

Columbia University Medical Center
NewYork-Presbyterian

# Non-contrast Solutions

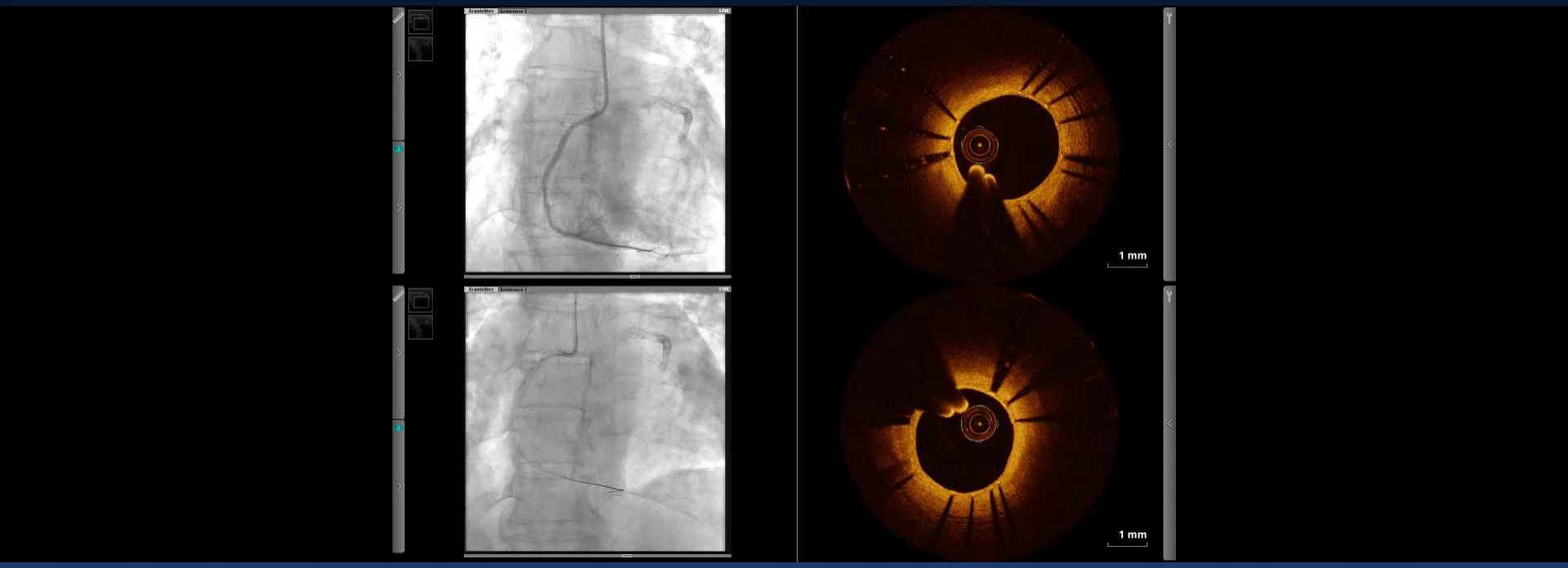


## Pre-PCI OCT – Contrast vs Saline

# Non-contrast Solutions

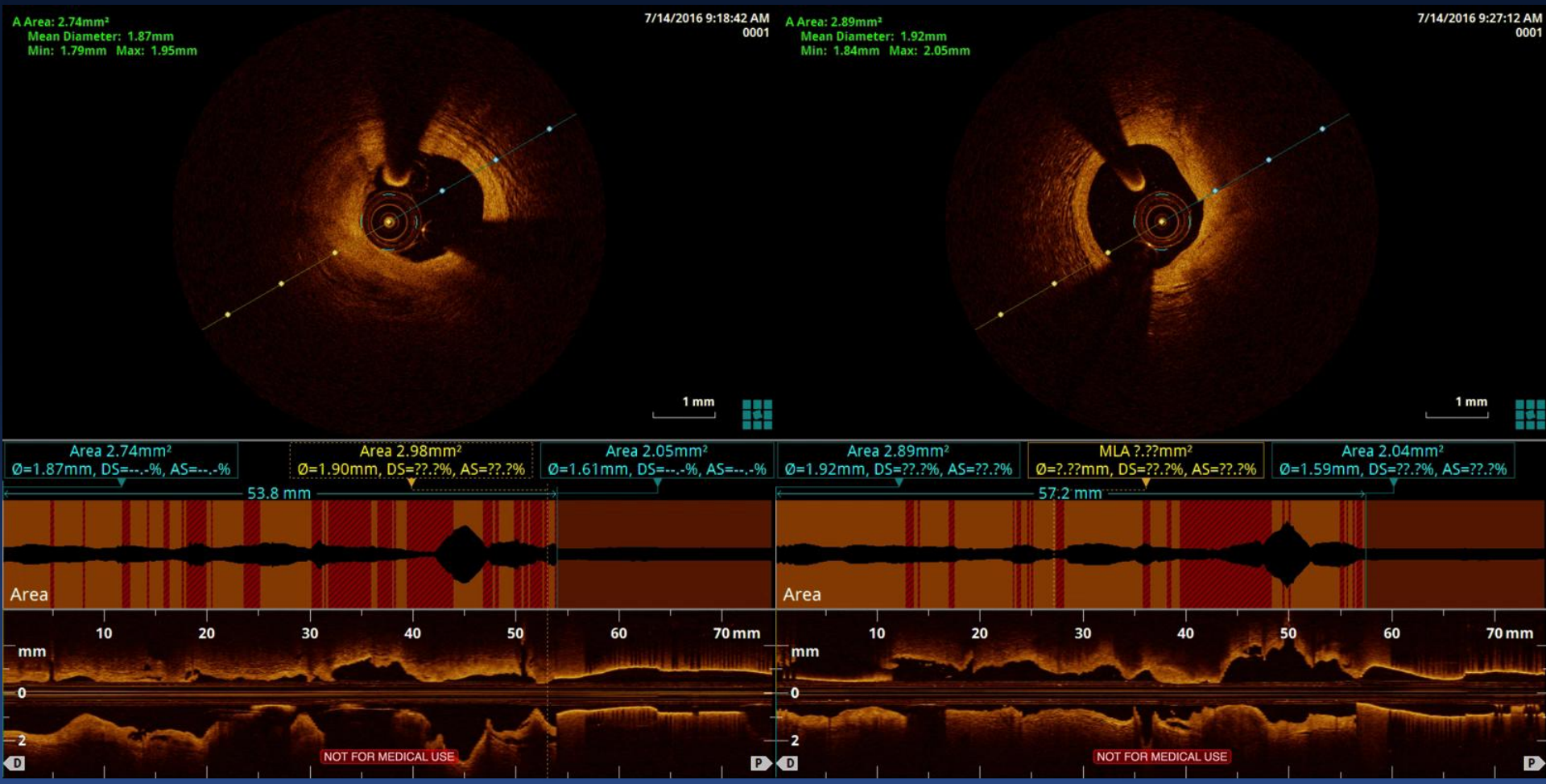


# Pre-PCI OCT – Contrast vs Solution X

# Zero contrast revascularization

- Vessel anatomy based on non-contrast CT-CAC

# Zero Contrast Revascularization

- DynaCT/CT-CAC coregistration to fluoroscopy

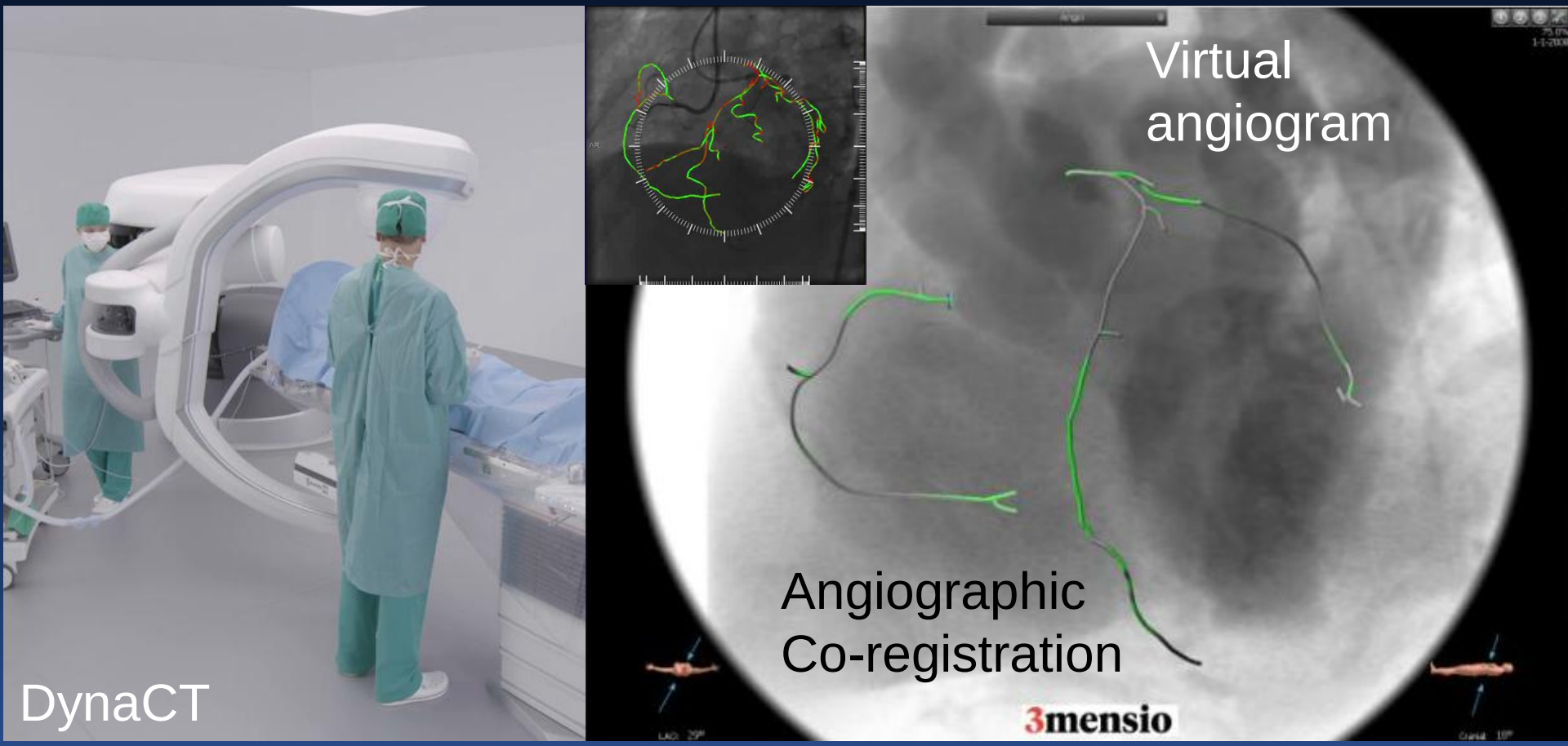

# Zero Contrast Revascularization

66 year old female with previous history of HTN, HLD, DM, CAD, CKD stage 5 presented with shortness of breath and central chest pressure on exertion. Remote history of anaphylaxis to contrast medium during CTA.

eGFRml/min/1.73 m2 =15
Creatinine = 4.07 mg/dl


# Clinical Impact

In patients with advanced CKD who require revascularization, PCI may safely be performed without contrast using imaging and physiological guidance with high procedural success and without complications.