Bifurcation Approaches:
A Step By Step Refresher

Curtiss T. Stinis, M.D., F.A.C.C., F.S.C.A.I.
Director, Peripheral Interventions
Director, Interventional Cardiology Fellowship Program
Division of Cardiology
Scripps Clinic
La Jolla, CA

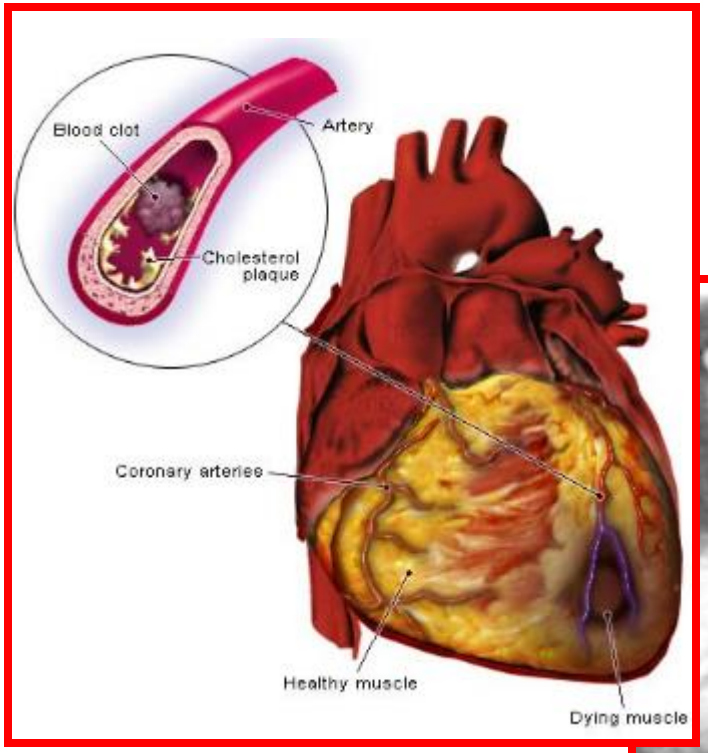

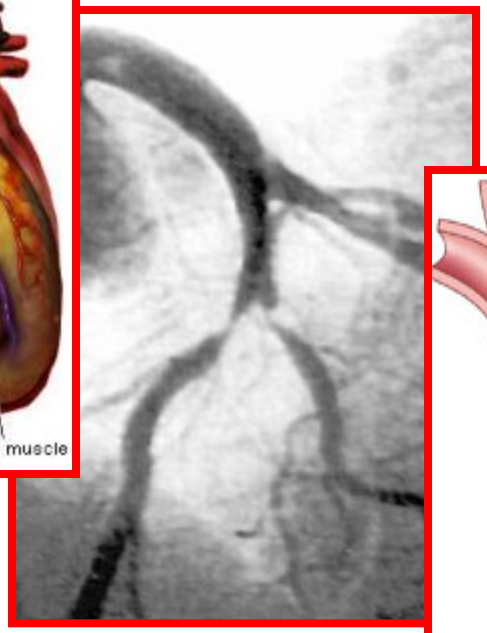

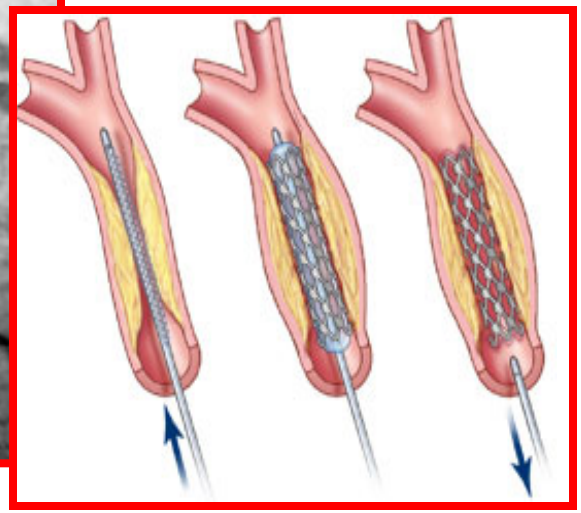

Background

- Bifurcation lesions are commonly encountered in clinical practice (up to 30% of PCIs)
- In the DES era, clinical outcomes of bifurcation PCI are very good
- Various 2-stent techniques have been devised to effectively treat bifurcations lesions
- The savvy interventional cardiologist needs to be familiar with all techniques since there are certain advantages and disadvantages to each

PCI for Bifurcation Lesions

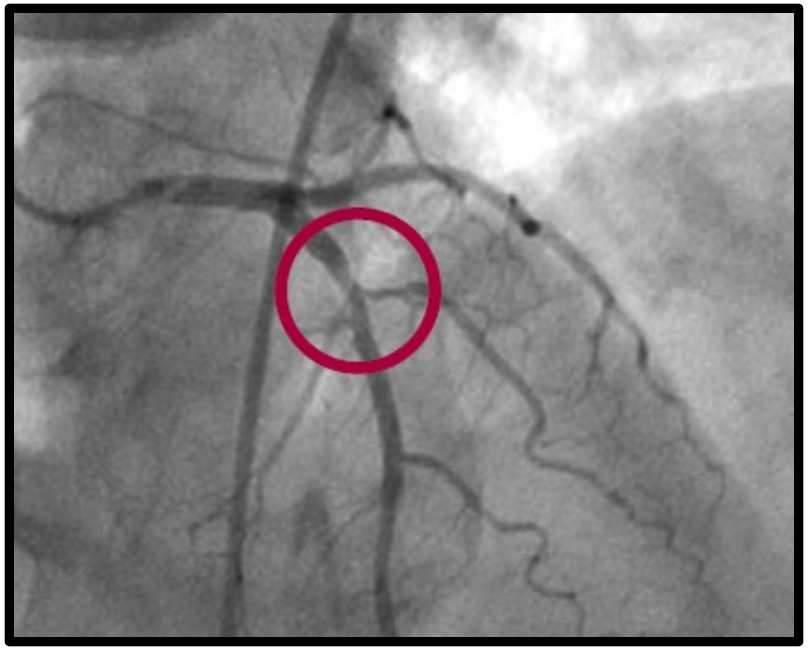

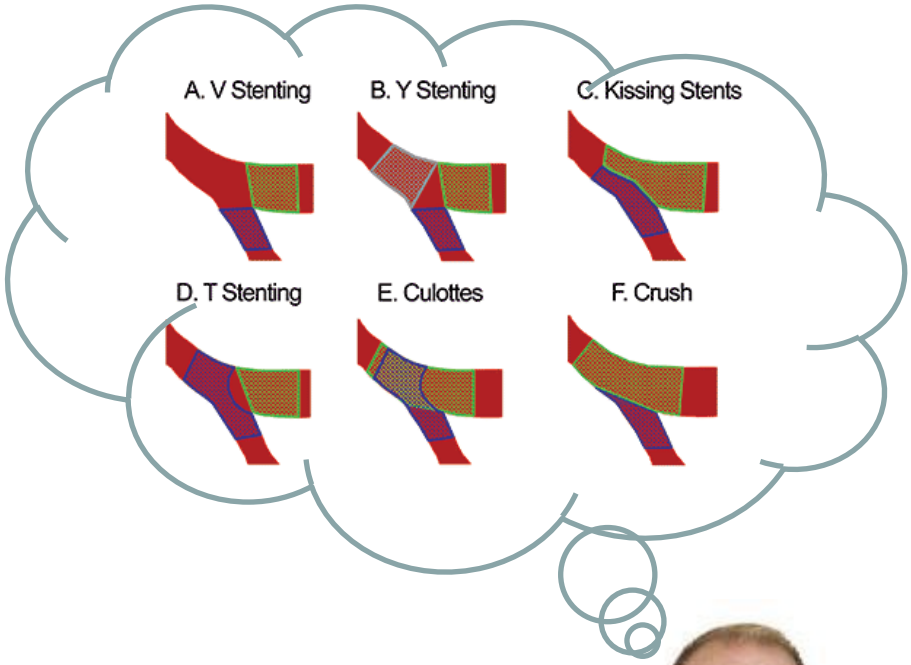

Why Do Bifurcation Lesions Pose Such a Challenge?

- When treating the main vessel, shift of plaque or thrombus can lead to sidebranch occlusion, particularly if:
  - The ostium of the sidebranch itself is diseased
  - The sidebranch is of small diameter
  - Thrombus from ACS is present

- Clinical consequences of loss of the sidebranch are dependent on vessel size and amount of myocardium

Bifurcation Intervention:

The Problem of Plaque Shift ("Snow Plow")

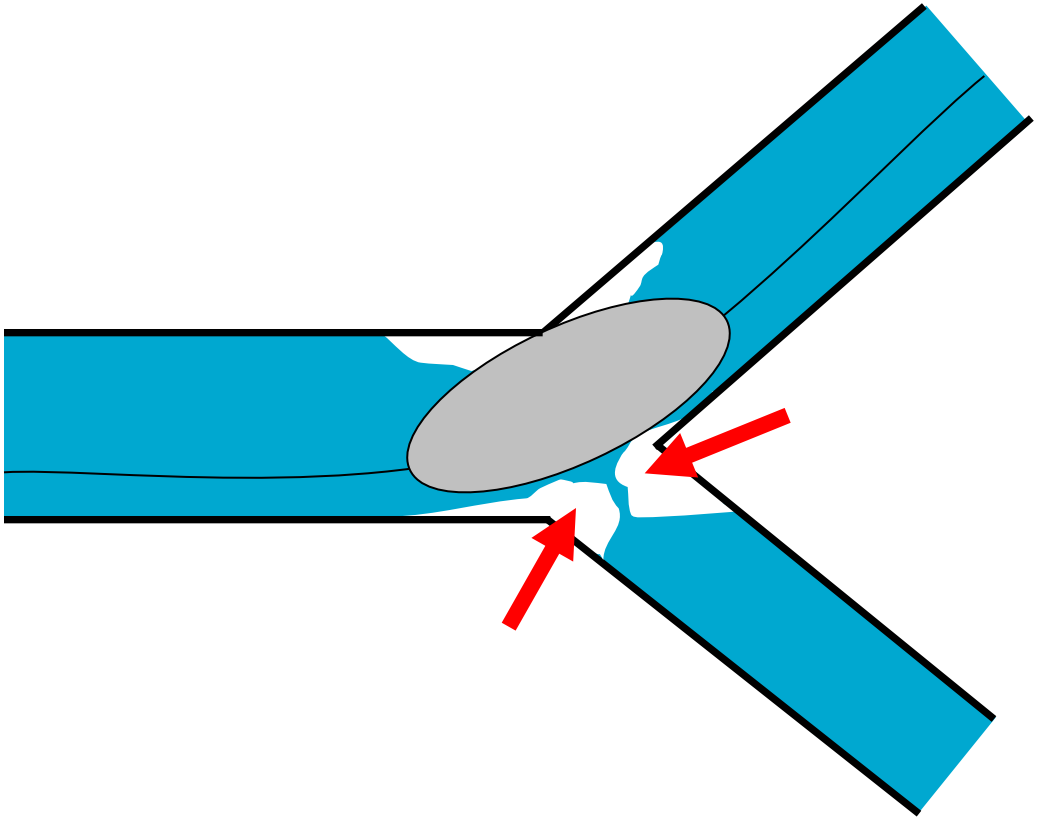

Commonly Used Bifurcation Techniques

- Provisional Stent Technique
- Crush Techniques
- Simultaneous Stent Techniques
- T Stent Techniques
- Culotte Technique

Provisional Stent Technique:

The 'simplest' way to treat a bifurcation lesion

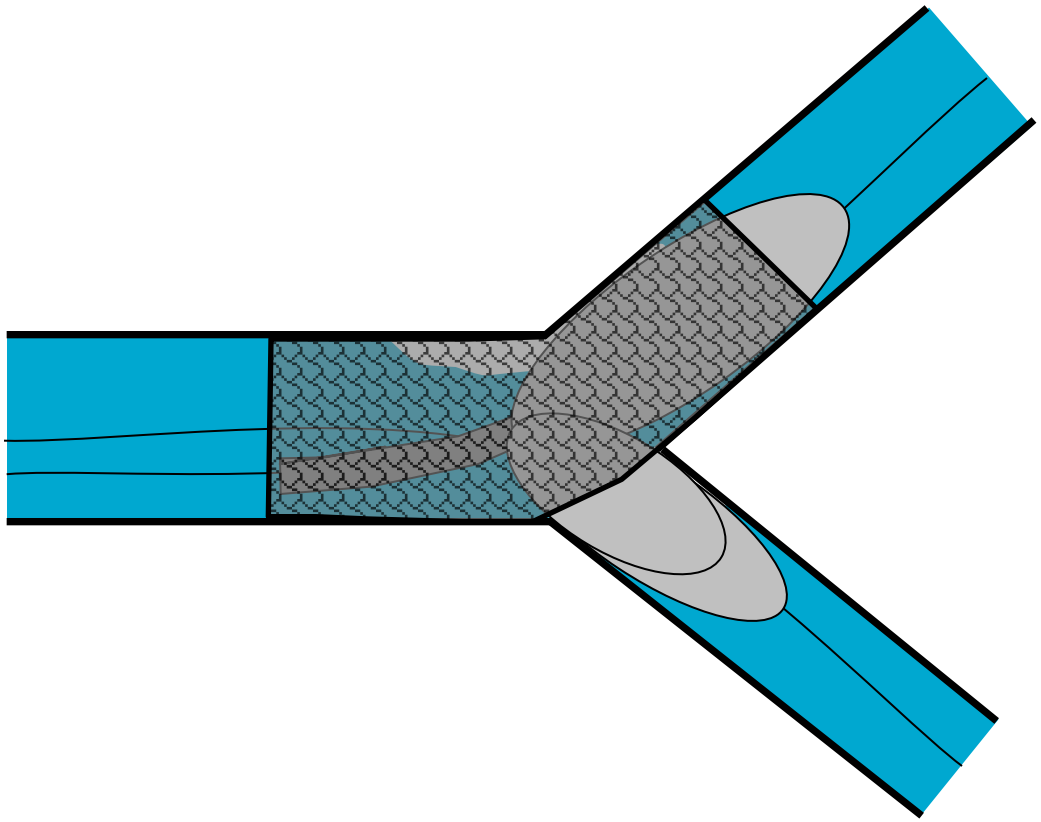

Wire both vessels (if needed)

Pre-dilate as needed

Stent main branch

Rewire and balloon side branch (+/- kissing balloon inflation)

Side branch closure after PCI

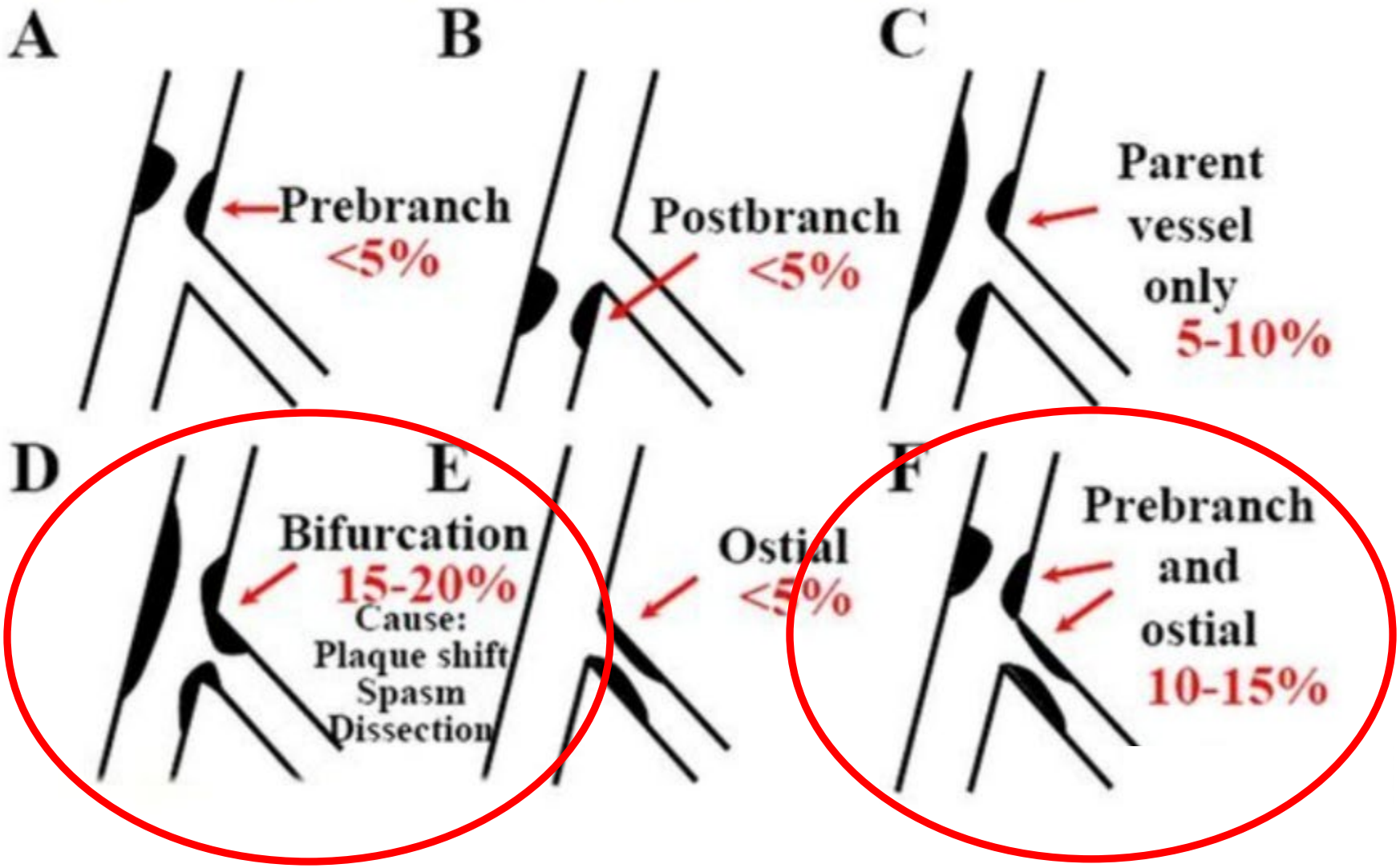

Provisional Stent Technique: Plan B

- If a second stent is needed after provisional stenting is performed (ie: dissection or compromise of the sidebranch) the following techniques can be used:

- Culotte Technique
- Reverse Crush Technique
- TAP Technique

Provisional Stent Technique

ADVANTAGES:

- Simple
- Less Metal
- Potentially easier to treat restenosis
- Less thrombosis?

DISADVANTAGES:

- Residual stenosis at side branch
- If side branch stent needed, it can be more difficult to insert it through first stent

If I Use a One Stent Strategy, Do I Need to do a Final Kissing Inflation?

Published online 2018 Jun 27. doi: 10.1371/journal.pone.0197580 PMID: 29949587

Should kissing balloon inflation after main vessel stenting be routine in the one-stent approach? A systematic review and meta-analysis of randomized trials

Ming Zhong, Conceptualization, Data curation, Formal analysis, Funding acquisition, Investigation, Methodology, Project administration, Writing – original draft, Writing – review & editing, Biao Tang, Data curation, Methodology, Qiang Zhao, Methodology, Jian Cheng, Investigation, Supervision, Qiangsong Jin, Supervision, and Shenwen Fu, Conceptualization, Project administration, Writing – review & editing*

Meta-analysis of all published studies that included kissing balloon inflation vs. no kissing balloon inflation when using a single stent strategy

Kissing balloon inflation was associated with a higher restenosis rate of the main branch and no difference in overall clinical outcome

Commonly Used Bifurcation Techniques

- Provisional Stent Technique
- Crush Techniques
- Simultaneous Stent Techniques
- T Stent Techniques
- Culotte Technique

The Classic Crush Technique

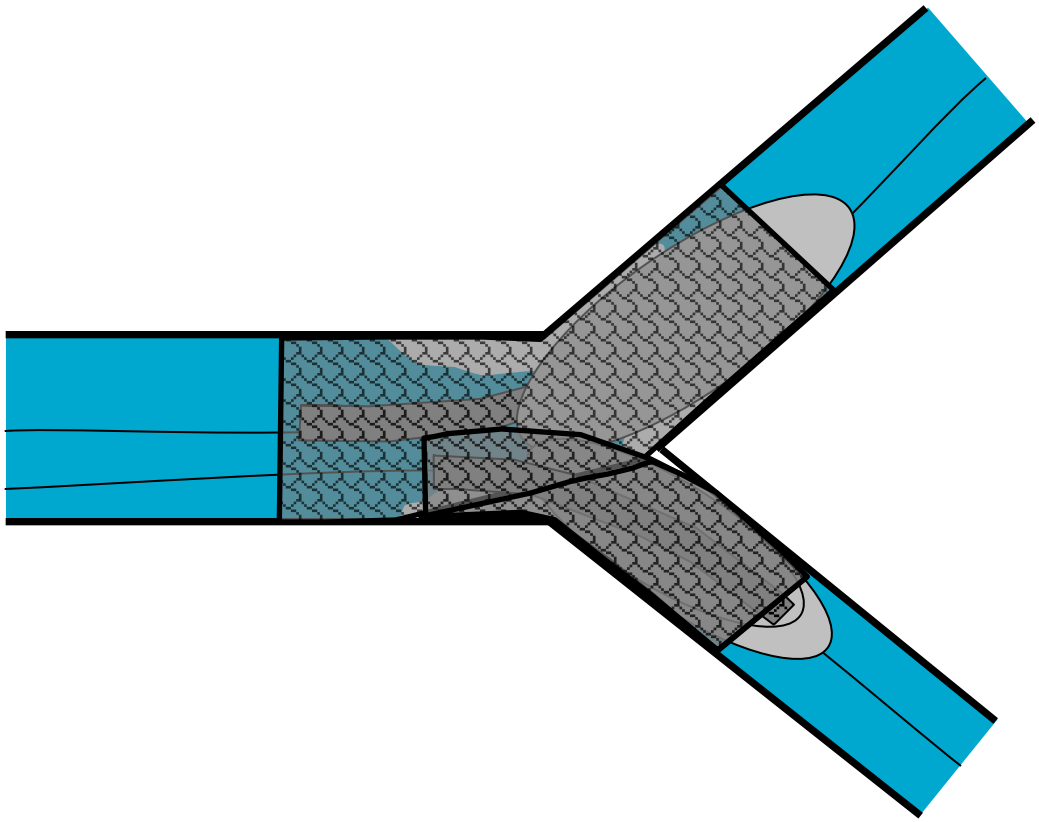

Wire both vessels

Pre-dilate as needed

Position stents

Deploy side branch stent, remove balloon/wire

Deploy main branch stent- 'crushes' side branch stent

Rewire side branch and perform kissing balloon inflation

The Crush Technique

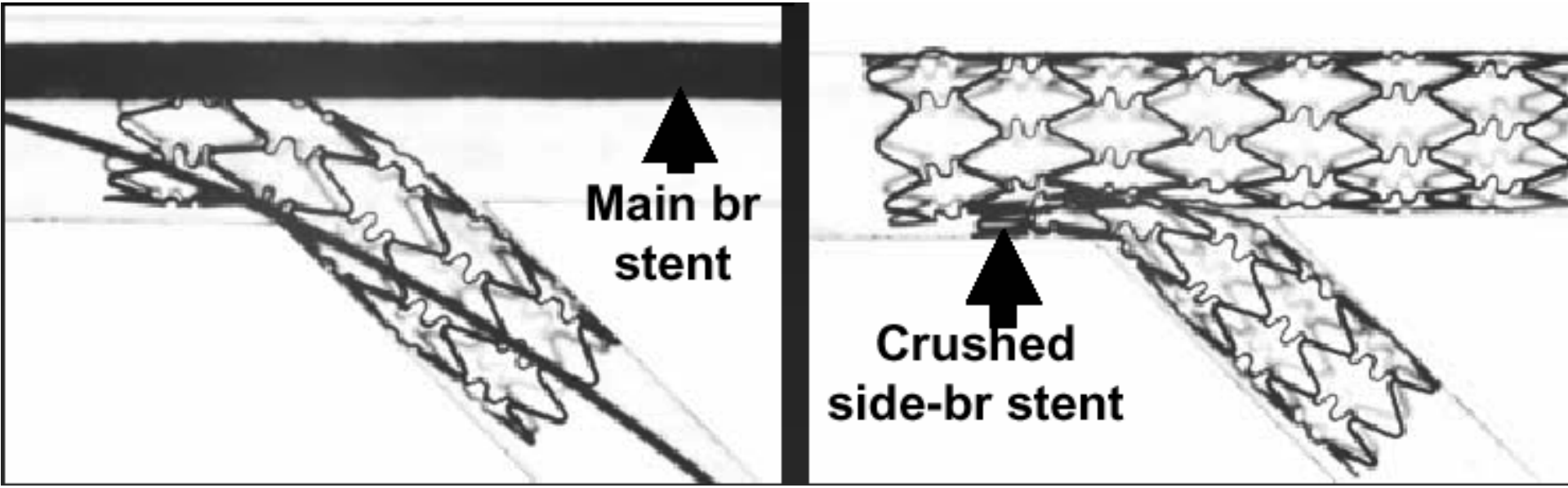

The Evolution of the 'Crush' Technique: Post-Crush Kissing Balloon Inflation

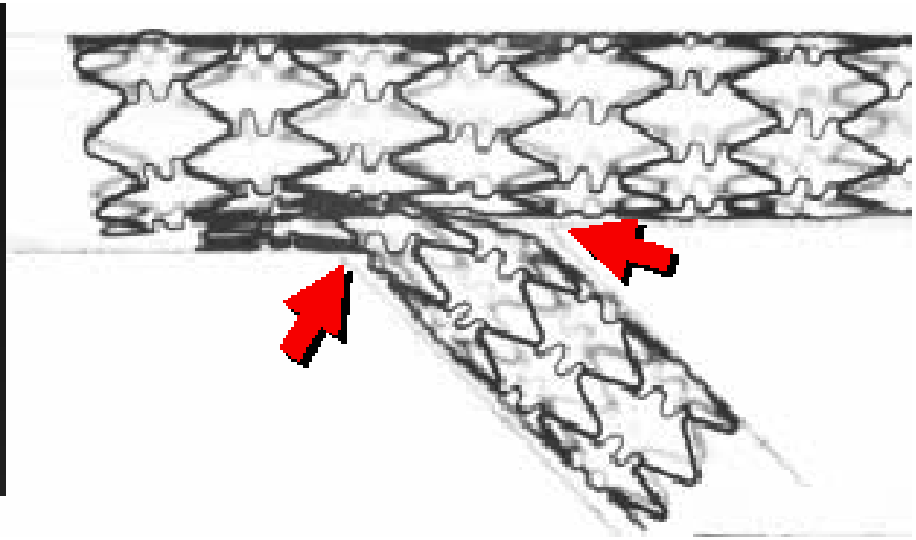

After Kissing Balloon Inflation

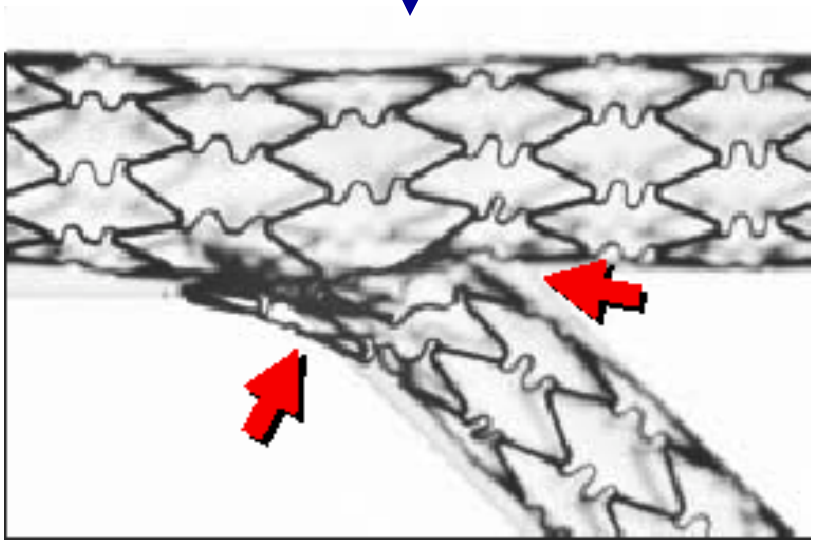

Before Kissing Balloon Inflation

Crush Technique: Variations

- Classic Crush
- Mini Crush
- Double Kissing Crush (DK Crush)
- Reverse Crush
- Step Crush

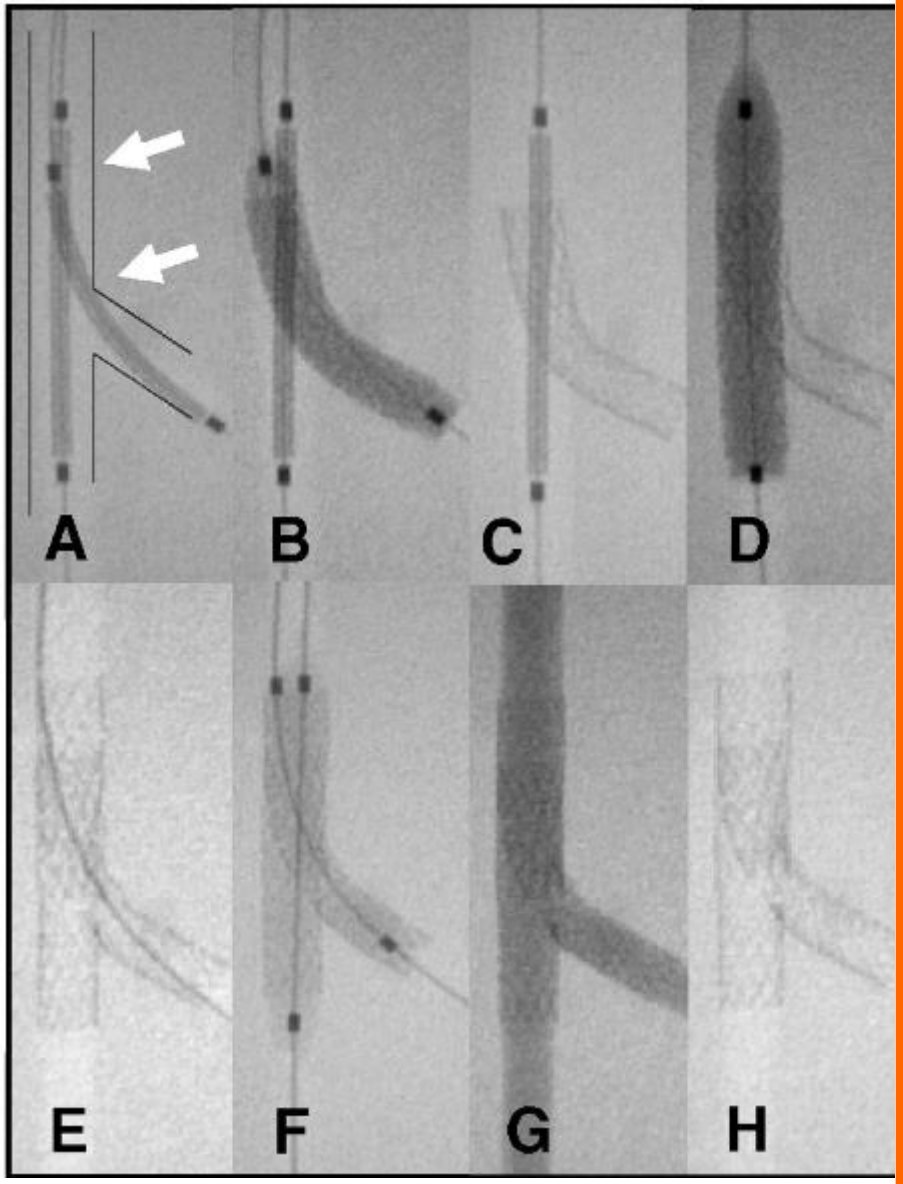

Classic Crush Technique

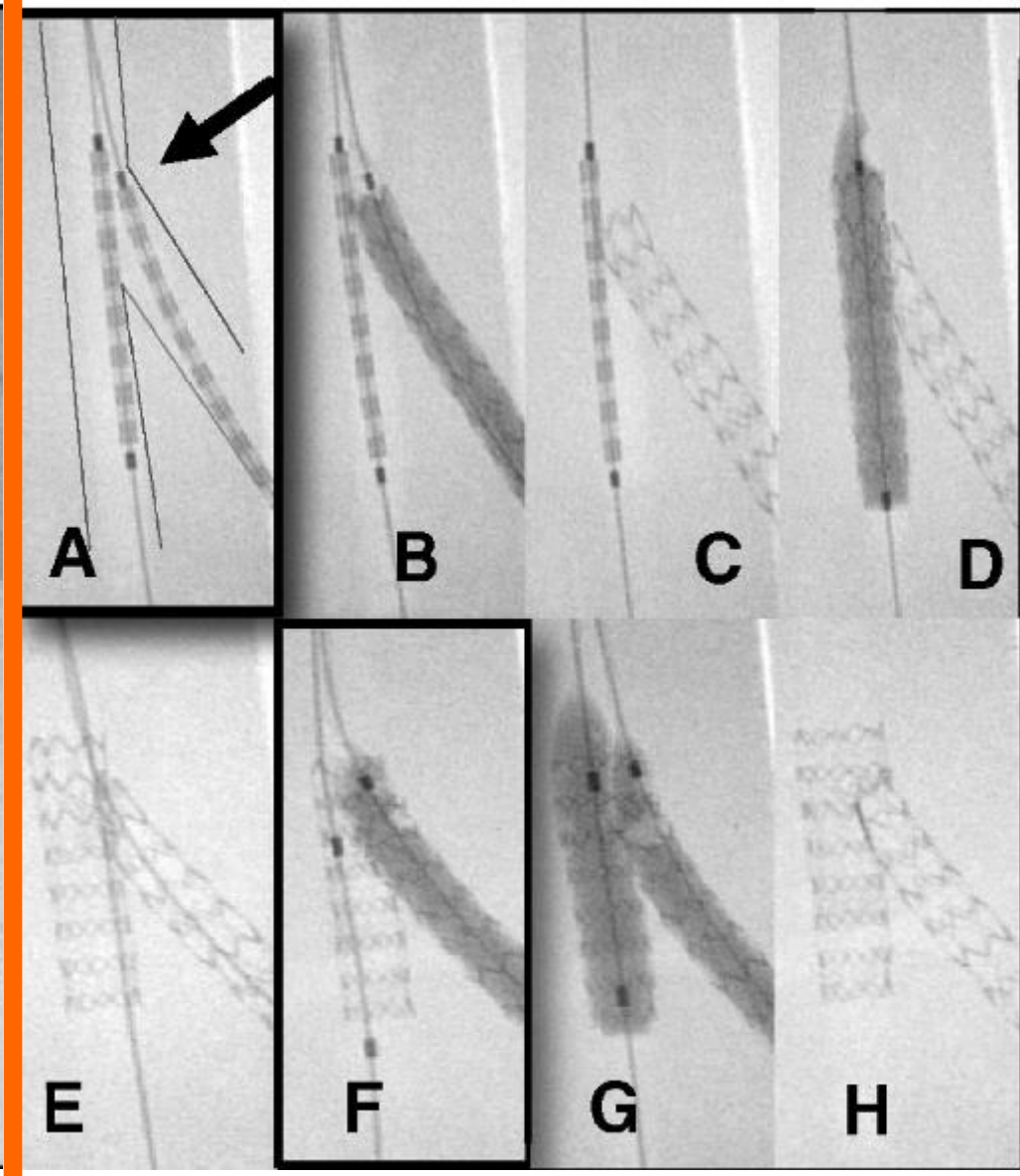

Mini Crush Technique

DK Crush Technique

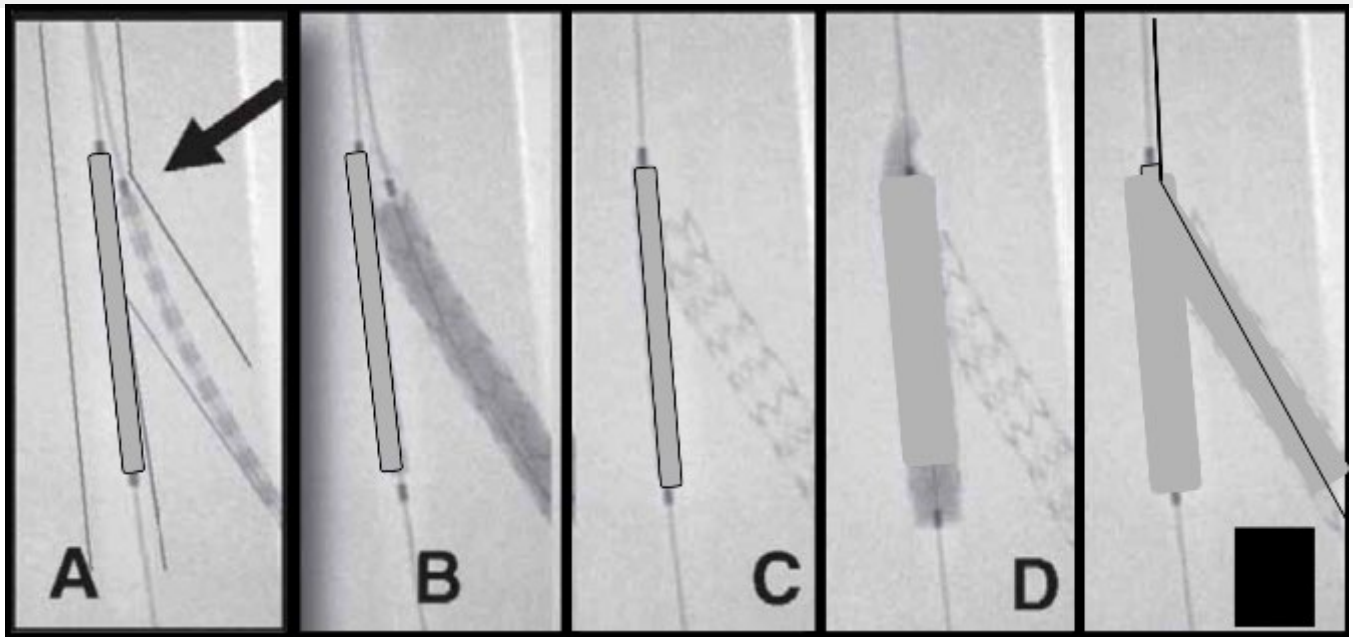

- Position sidebranch stent as if performing a Mini Crush, in conjunction with a balloon in the mainbranch
- Deploy sidebranch stent, withdraw sidebranch stent balloon slightly, then reinflate to high pressures to “flare” the proximal sidebranch stent
- Remove sidebranch balloon and wire
- Crush sidebranch stent with mainbranch balloon
- Rewire sidebranch and perform a kissing balloon inflation

DK Crush Technique

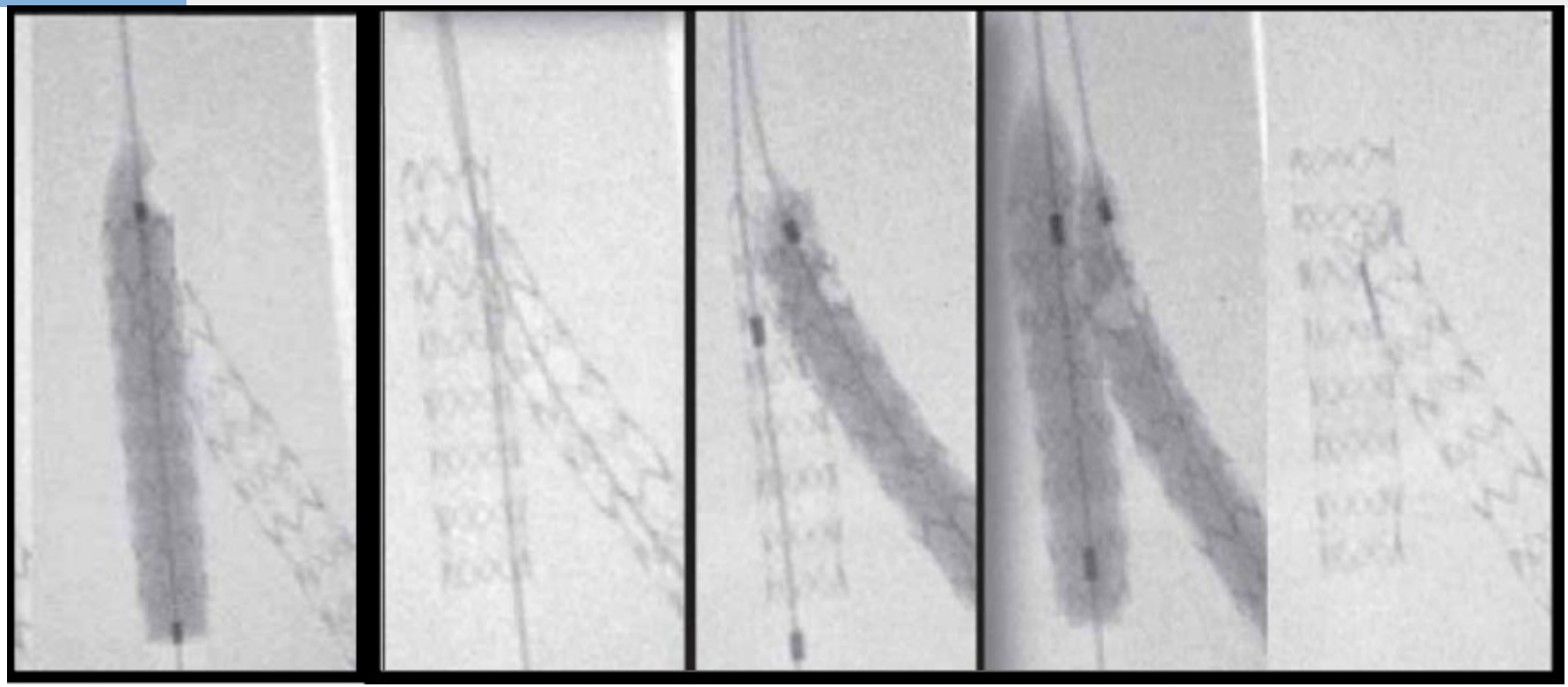

- Remove sidebranch wire and balloon
- Position stent in the mainbranch and deploy it
- Rewire sidebranch and perform final kissing balloon inflation

Reverse Crush Technique

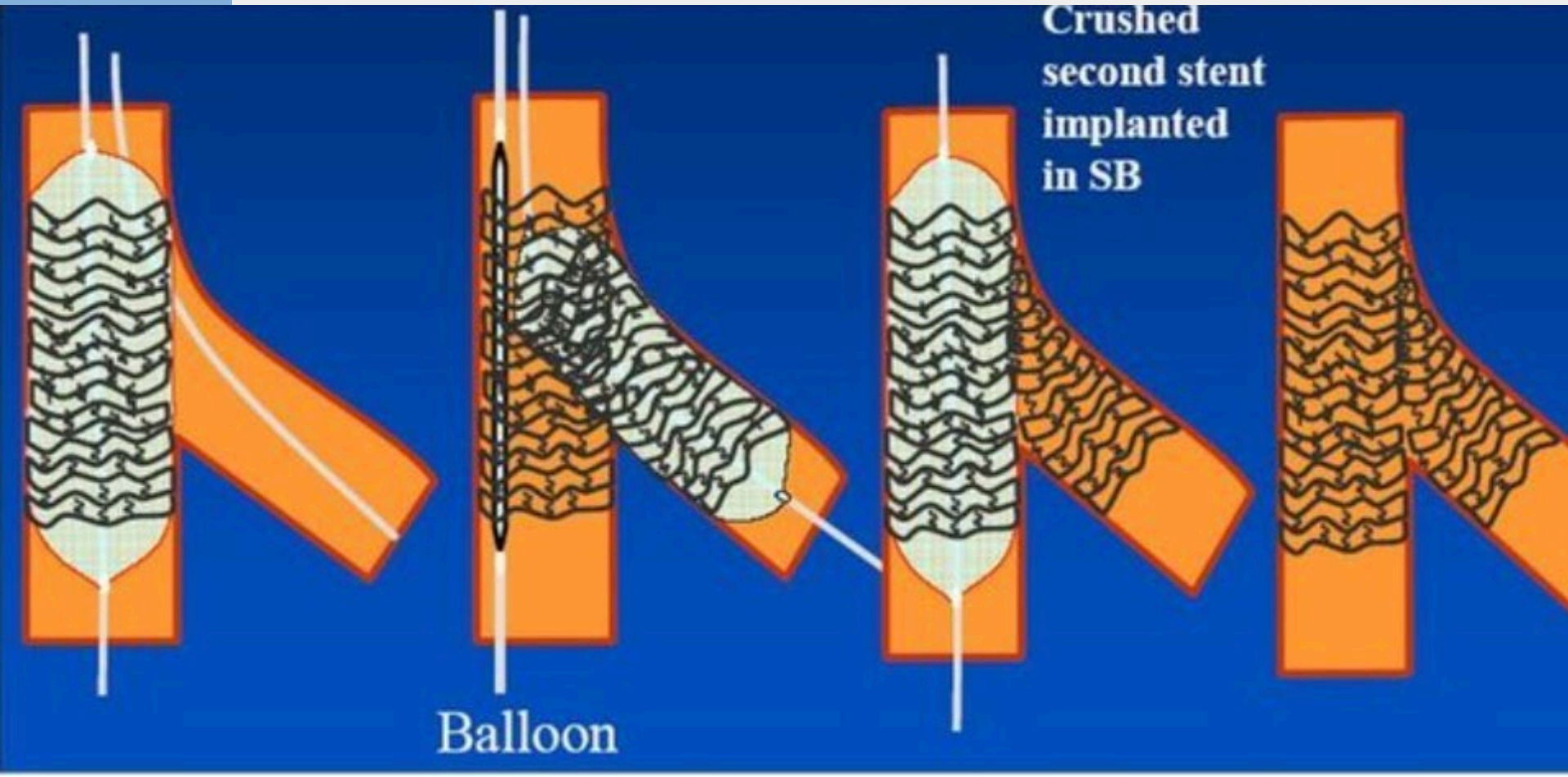

Performed as a bailout strategy if provisional stenting of the mainbranch is suboptimal

Crush Stent Technique

ADVANTAGES:

- Assures coverage of side branch ostium
- Prevents loss of side branch
- Can be used if side branch and main branch are of significantly different sizes

DISADVANTAGES:

- More complex
- Time consuming
- More costly (additional wires/balloons)
- Sometimes unable to perform the final kiss-destined for a worse outcome
- More difficult to treat restenosis

Commonly Used Bifurcation Techniques

- Provisional Stent Technique
- Crush Techniques
- Simultaneous Stent Techniques
- T Stent Techniques
- Culotte Technique

The Simultaneous Kissing Stent (SKS) Technique

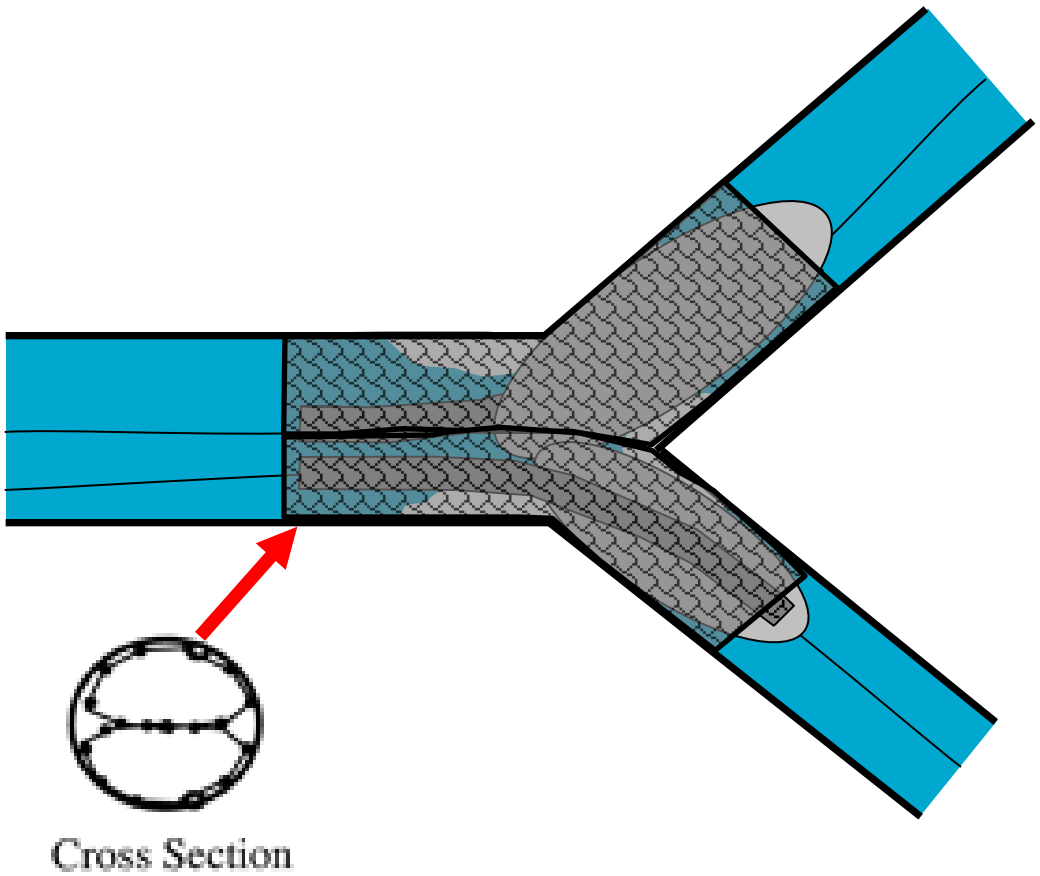

- Wire both vessels
- Pre-dilate as needed
- Position stents
- Deploy stents simultaneously
- Perform kissing balloon post-dilatation

Simultaneous Kissing Stent Technique (SKS)

ADVANTAGES:

- Simple
- Maintain wire access to both branches at all times
- Minimal ischemic time

DISADVANTAGES:

- Can be difficult to rewire/retreat later due to neocarina
- Requires larger vessels of similar size
- Higher restenosis rates reported

Simultaneous V Stenting Technique

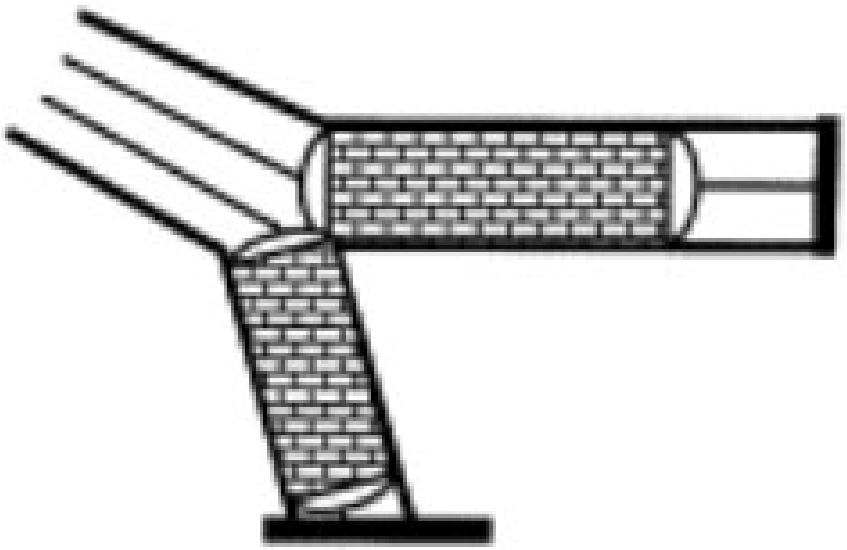

- **Identical to the SKS technique, but without the creation of a new carina**

Simultaneous V Stenting Technique

ADVANTAGES:

- Simple
- Maintain wire access to both branches at all times
- Minimal ischemic time

DISADVANTAGES:

- Only works if proximal main branch is free of disease
- Plaque shift more proximally can be difficult to treat:

Add a stent proximally and potentially leave a gap vs. convert to SKS

Commonly Used Bifurcation Techniques

- Provisional Stent Technique
- Crush Techniques
- Simultaneous Stent Techniques
- T Stent Techniques
- Culotte Technique

Traditional T Stent Technique

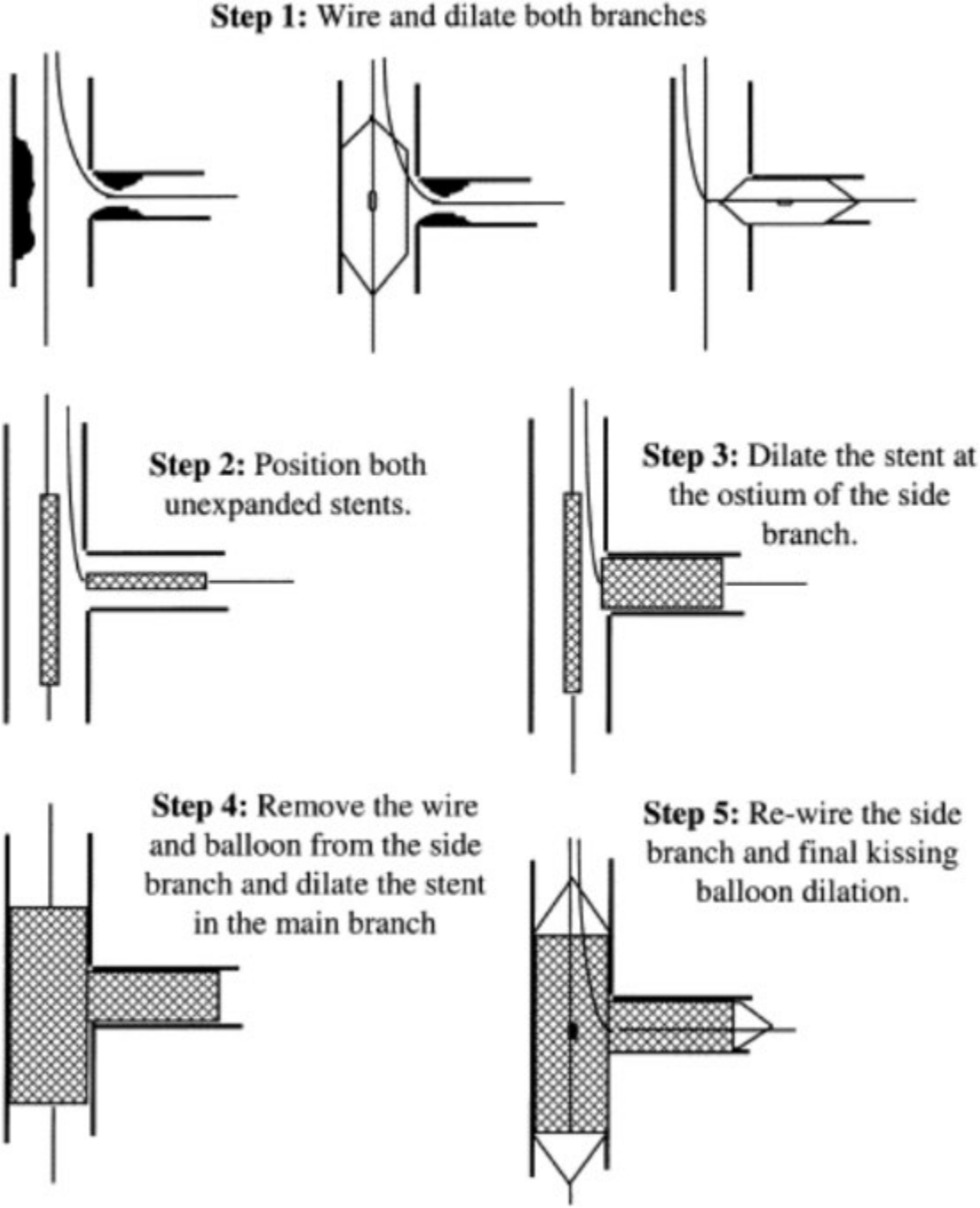

PROBLEM:

Almost NEVER is there a perfect 90 degree angle between mainbranch and sidebranch!

Use of the traditional T stent technique is associated with high risk of missing the sidebranch ostium

The TAP Technique

T stent And Protrusion

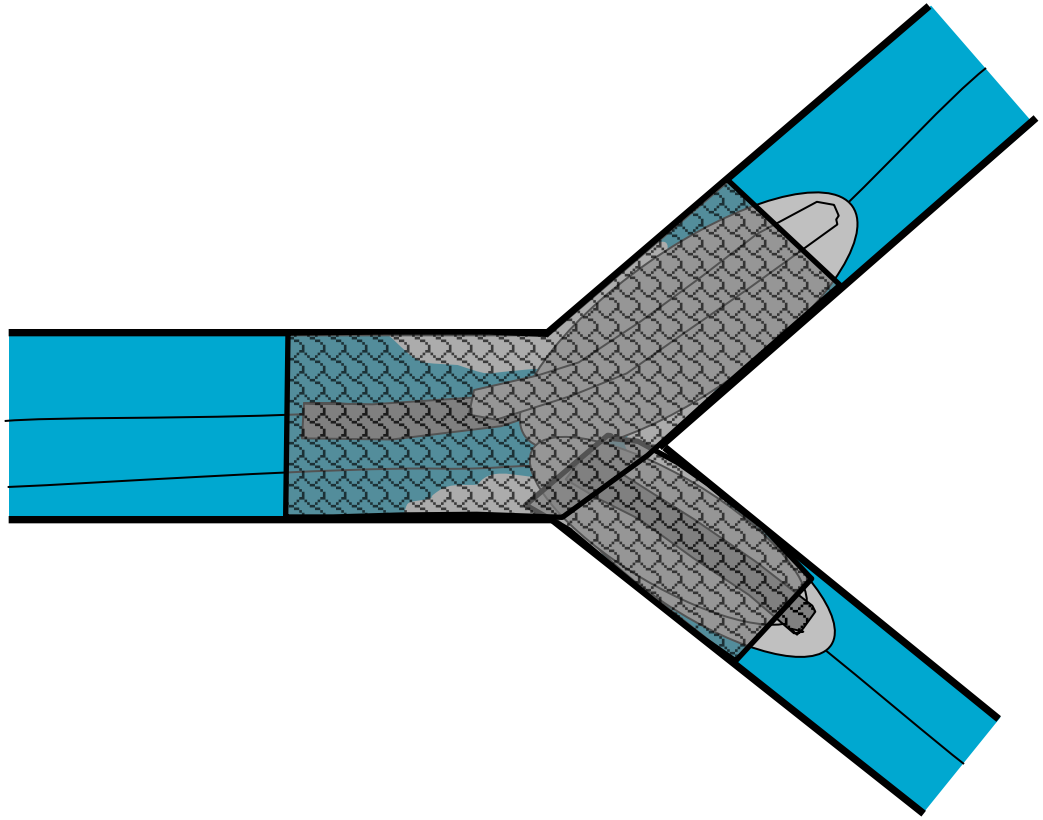

- Wire both vessels
- Pre-dilate as needed
- Position and deploy main branch stent
- Rewire side branch and balloon dilate
- Position side branch stent so proximal edge protrudes slightly into main branch, ‘backstop’ balloon in main branch
- Deploy side branch stent first, then inflate main branch balloon to kiss

TAP Technique

ADVANTAGES:

- Relatively simple
- Assures coverage of side branch ostium
- Less metal at side branch ostium compared to Crush technique
- Works when vessels are different sizes

DISADVANTAGES:

- Excessive stent protrusion can lead to trouble accessing distal main branch in the future

Commonly Used Bifurcation Techniques

- Provisional Stent Technique
- Crush Techniques
- Simultaneous Stent Techniques
- T Stent Techniques
- Culotte Technique

The Culotte Technique

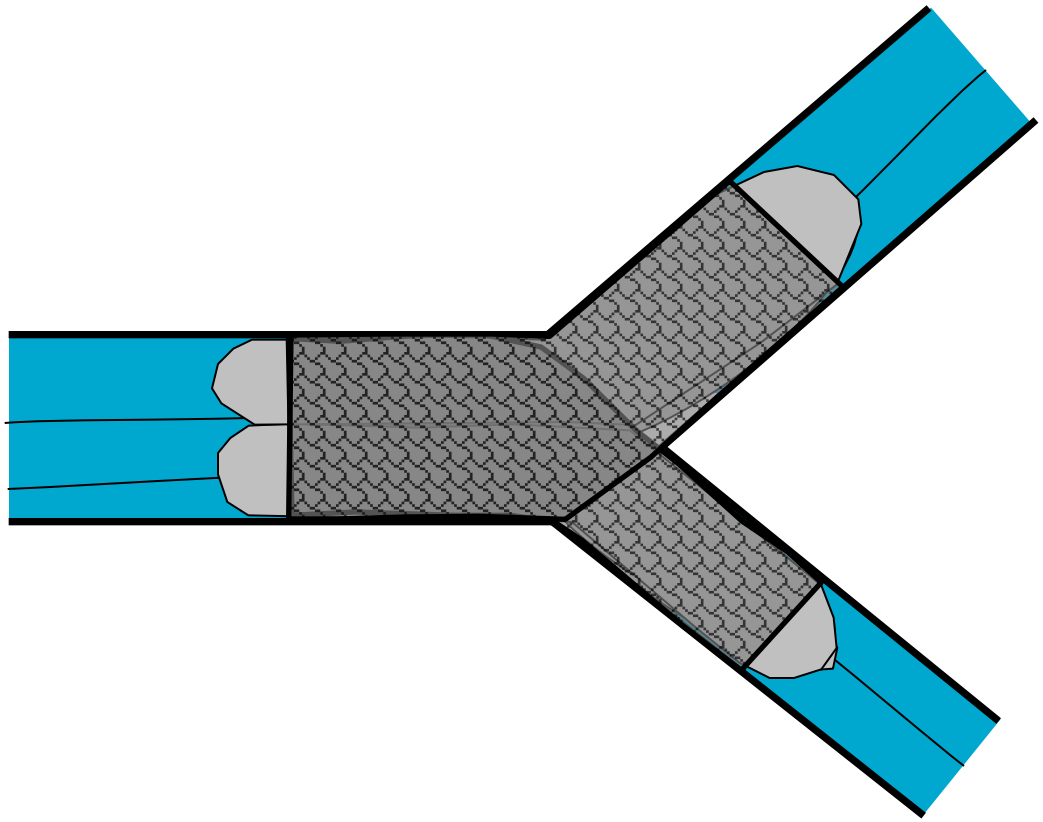

- Wire both vessels
- Pre-dilate as needed
- Position and deploy stent in most angulated branch
- Remove first wire, wire second branch and balloon dilate
- Position second branch stent so proximal portion equal with previous stent edge and deploy
- Rewire initially stented branch and perform kissing post-dilitation

Culotte Technique

ADVANTAGES:

- Assures side branch ostium coverage
- Excellent radial strength in main branch

DISADVANTAGES:

- Complex
- Vessels must be of similar size
- Somewhat time consuming

What is POT?

Proximal Optimization Technique

Dilatation of the stent within the proximal vessel to an appropriate size to achieve proper apposition to avoid rewiring behind the stent and causing inadvertent crush or distortion of the stent

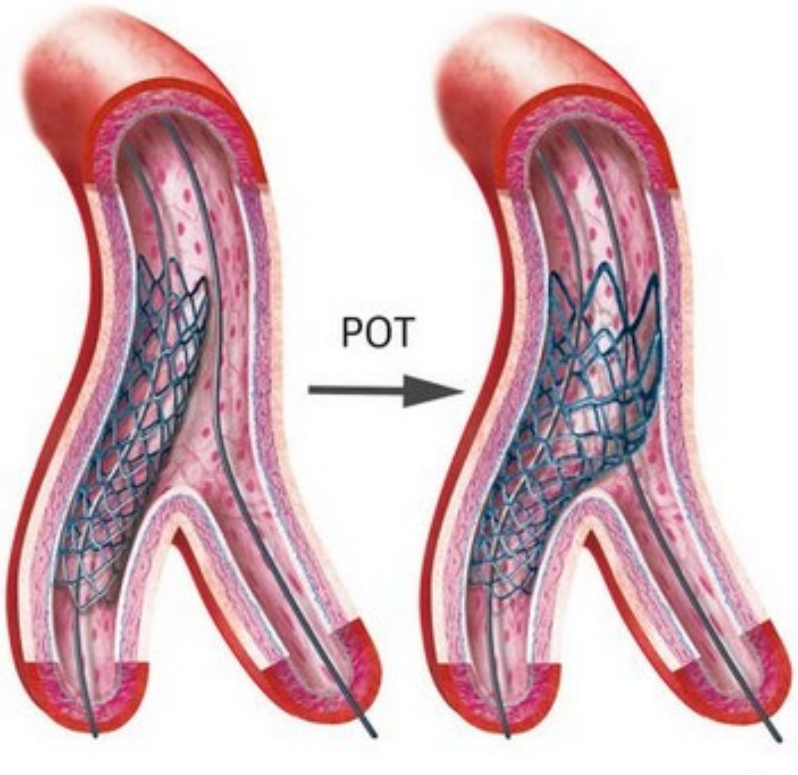

Does it Really Matter What Technique I Use?

JIC JOURNAL OF INVASIVE CARDIOLOGY

Long-Term Outcomes of Different Two-Stent Techniques With Second-Generation Drug-Eluting Stents for Unprotected Left Main Bifurcation Disease: Insights From the FAILS-2 Study

Author(s): Marco Pavani, MD[1]; Federico Conrotto, MD[1]; Enrico Cerrato, MD[2]; Fabrizio D'Ascenzo, MD[1]; Hiroyoshi Kawamoto, MD[3,4]; Ivan J. Núñez-Gil, MD[5]; Mauro Pennone, MD[1]; Roberto Garbo, MD[6]; Francesco Tomassini, MD[2]; Francesco Colombo, MD[6]; Paolo Scacciatella, MD[1]; Ferdinando Varbella, MD[2]; Alaide Chieffo, MD[4]; Antonio Colombo, MD[4]; Javier Escaned, Prof, MD[5]

Issue Number:
Volume 30 - Issue 8 - August, 2018

A registry of unprotected left main bifurcation lesions treated with T-stenting, mini-crush, and Culotte techniques

Long-Term Outcomes of Different Two-Stent Techniques With Second-Generation Drug-Eluting Stents for Unprotected Left Main Bifurcation Disease: Insights From the FAILS-2 Study

Table 3. Long-term outcomes (median follow-up, 2.27 years).

	T-Stenting (n = 66)	Mini-Crush (n = 103)	Culotte (n = 68)	*P*-Value
Long-term follow-up (years)	2.2 ± 1.5	2.1 ± 1.4	2.2 ± 1.5	.90
Planned angiographic follow-up	32 (50.0%)	69 (68.0%)	54 (79.5%)	<.01
Major adverse cardiac events	14 (22.0%)	27 (26.0%)	21 (31.0%)	.50
Death	6 (9.3%)	9 (9.0%)	3 (4.5%)	.48
Myocardial infarction	1 (1.5%)	1 (1.0%)	1 (1.4%)	.93
TVR	9 (14.0%)	20 (19.5%)	17 (25.0%)	.28
Angio-driven TVR	5 (7.8%)	9 (8.7%)	10 (14.7%)	.34
Ischemia-driven TVR	4 (6.0%)	11 (10.6%)	7 (10.3%)	.60
TLR	8 (12.5%)	18 (17.5%)	14 (20.5%)	.41
Angio-driven TLR	5 (7.8%)	8 (7.7%)	7 (10.3%)	.82
Ischemia-driven TLR	3 (4.7%)	10 (9.7%)	6 (8.8%)	.49
TLR on left main	2 (3.0%)	6 (6.0%)	2 (3.0%)	.63
TLR on left anterior descending	4 (6.2%)	4 (4.0%)	2 (3.0%)	.62
TLR on circumflex	6 (9.3%)	16 (15.5%)	11 (16.0%)	.44
Stent thrombosis (definite/probable)	0 (0.0%)	0 (0.0%)	0 (0.0%)	N/A
Possible stent thrombosis	1 (1.5%)	3 (3.0%)	0 (0.0%)	.47

TLR = target-lesion revascularization; TVR = target-vessel revascularization;

DK Crush vs. Provisional Stenting for Left Main Bifurcation Lesions

Double Kissing Crush Versus Provisional Stenting for Left Main Distal Bifurcation Lesions: DKCRUSH-V Randomized Trial

Shao-Liang Chen MD [a], Jue-Jie Zhang PhD [a], Yaling Han MD [b], Jing Kan MBBS [a], Lianglong Chen MD [c], Chunguang Qiu MD [d], Tiemin Jiang MD [e], Ling Tao MD [f], Hesong Zeng MD [g], Li Li MD [h], Yong Xia MD [i], Chuanyu Gao MD [j], Teguh Santoso MD [k], Chootopol Paiboon MD [l], Yan Wang MD [m], Tak W. Kwan MD [n], Fei Ye MD [o], Nailiang Tian MD [o] ... Gregg W. Stone MD [aa]

482 patients from 26 centers in 5 countries with true distal LM bifurcation lesions (Medina 1,1,1 or 0,1,1) randomized to provisional stenting (n = 242) or DK crush stenting (n = 240)

Chen et al. JACC Volume 70, Issue 21, 28 November 2017, Pages 2605-2617

DK Crush vs. Provisional Stenting for Left Main Bifurcation Lesions

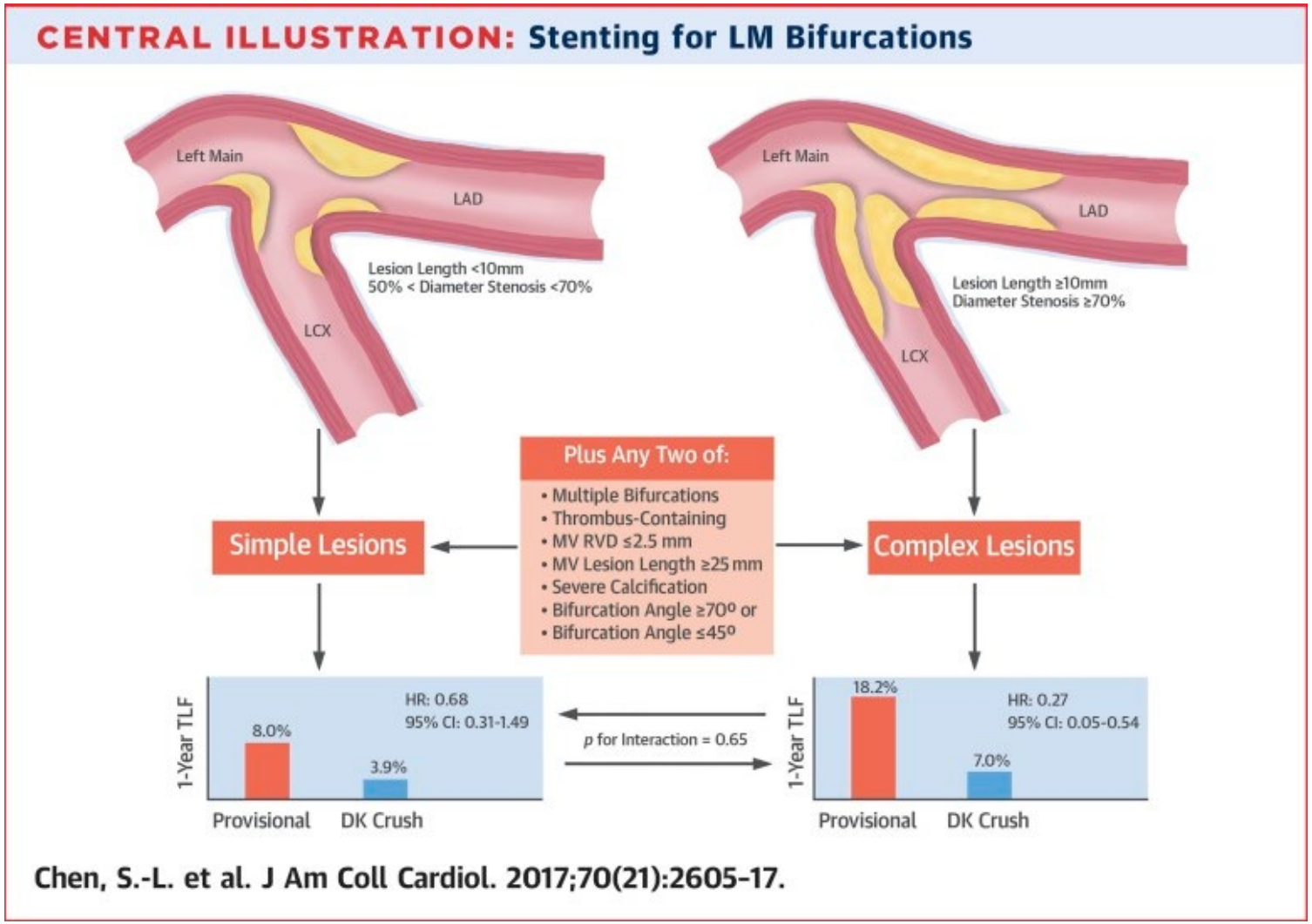

Chen, S.-L. et al. J Am Coll Cardiol. 2017;70(21):2605-17.

Conclusions

- Multiple techniques have been developed to effectively treat bifurcation lesions
- Each has unique advantages and disadvantages
- Being proficient with multiple techniques will assure that you are able to perform PCI regardless of varying patient anatomy with excellent technical success

Thank You