Weill Cornell Medicine New York-Presbyterian

Use of Near Infrared Spectroscopy (NIRS) for Monitoring Spinal Cord Perfusion During Endovascular Repair of Complex Aortic Aneurysms

Darren B. Schneider, MD
Associate Professor of Surgery
Chief, Vascular and Endovascular Surgery

February 16, 2018



Relevant Disclosures

W.L. Gore - research funding; consulting; medical advisory board

Cook - research funding

Medtronic - medical advisory board

Spinal Cord Perfusion

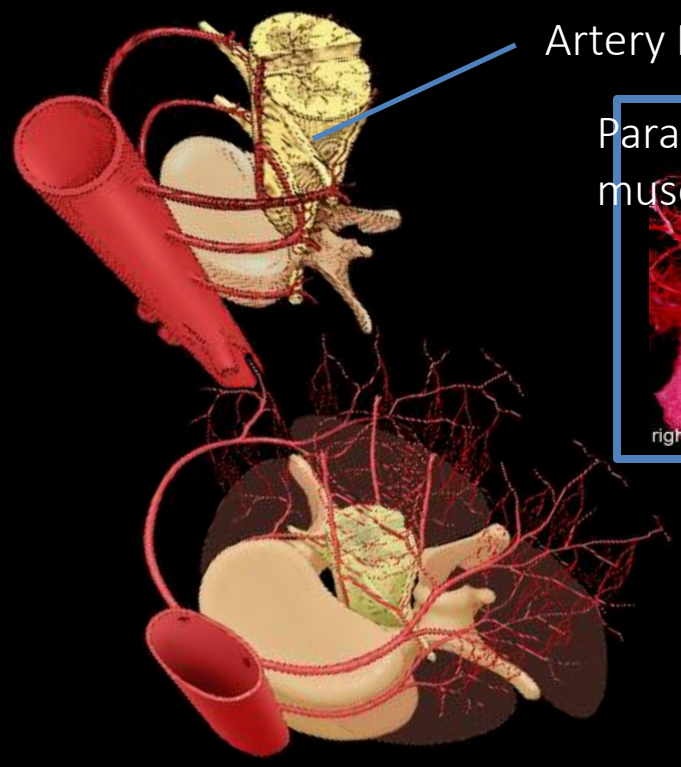

Artery Radicular Magna

Paraspinal musculature

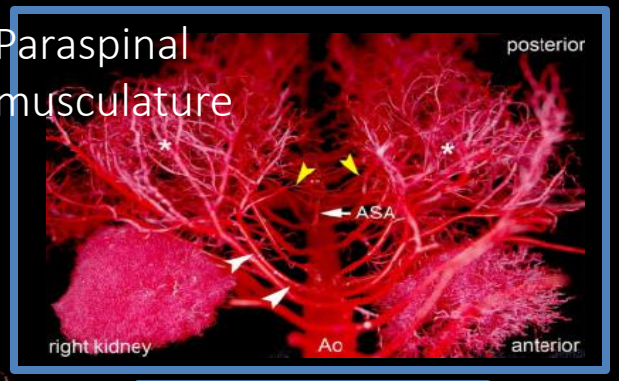

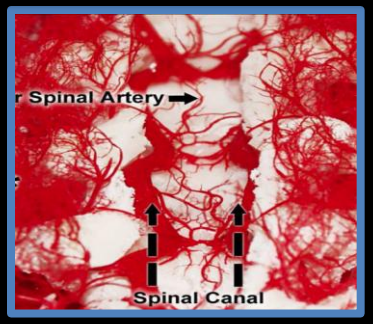

Vertebral

Anterior Spinal

Segmental arteries

Internal iliac

Randal Griepp (multiple sources)

Blood Supply To Spinal Cord Collateral Network After Complex EVAR

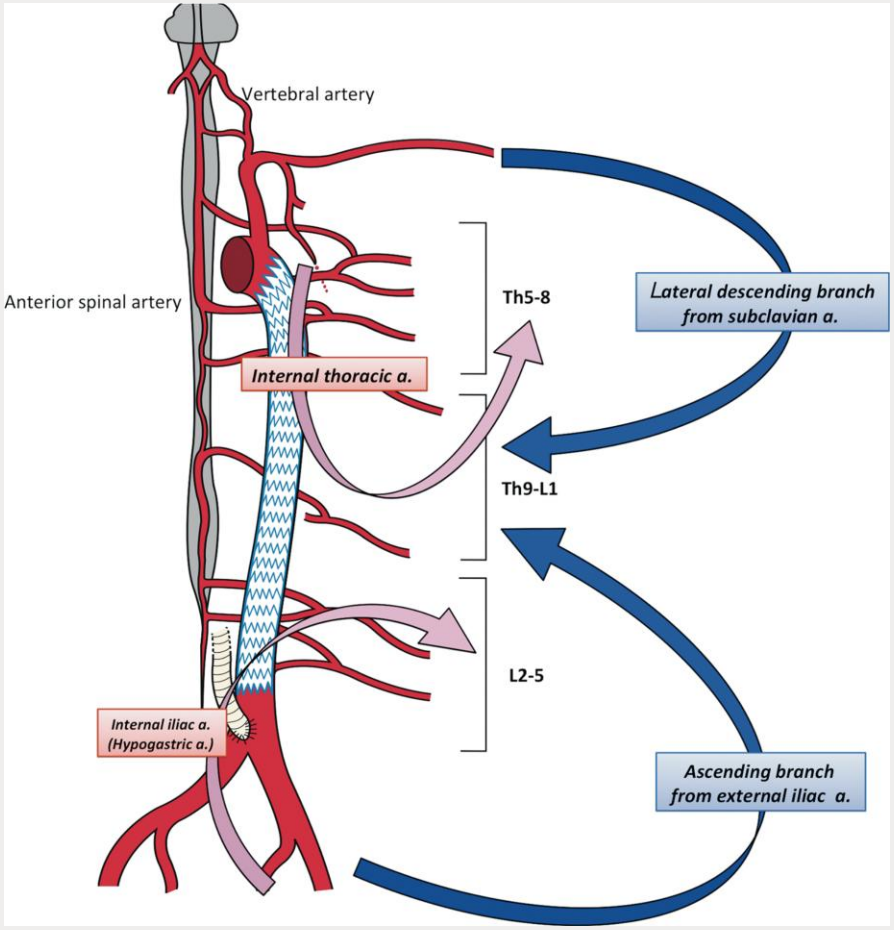

Main supply to the spinal cord collateral network after EVAR:

- » Subclavian
- » Internal iliac
- » External iliac

Shijo *Eur J Cardiothorac Surg* 2015

Segmental Arteries After Endovascular Aortic Repair

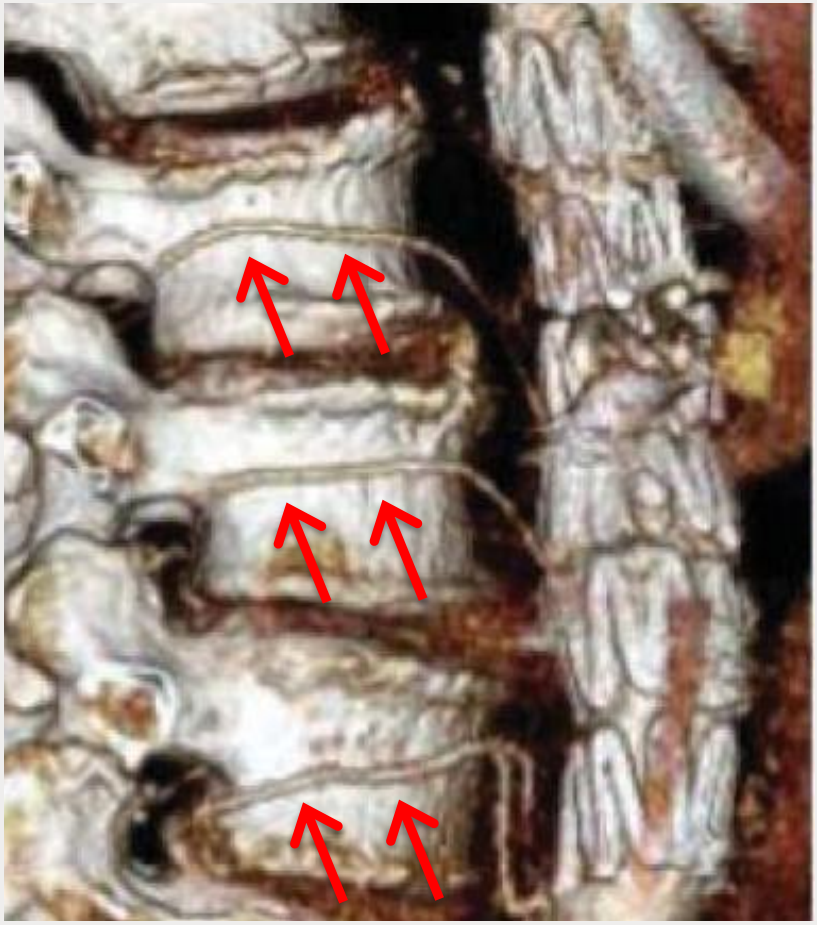

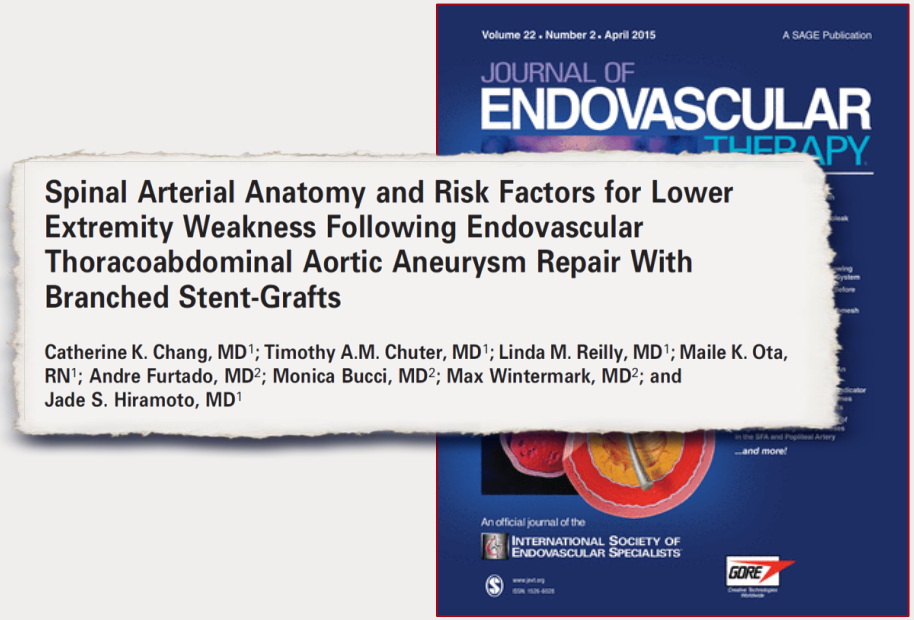

- CT scans showed no reduction in the number of segmental arteries
- Collaterals maintain arterial patency of segmental arteries

Chang et al. J Endovasc Ther 2008

Spinal Cord Protection

- CSF Drainage
- MAP > 90 mmHg
- Transfusion to Hct ≥ 30
- Early restoration of LE perfusion
- Staged Procedures

CSF Drainage

Staging and Temporary Aneurysm Sac Perfusion (TASP)

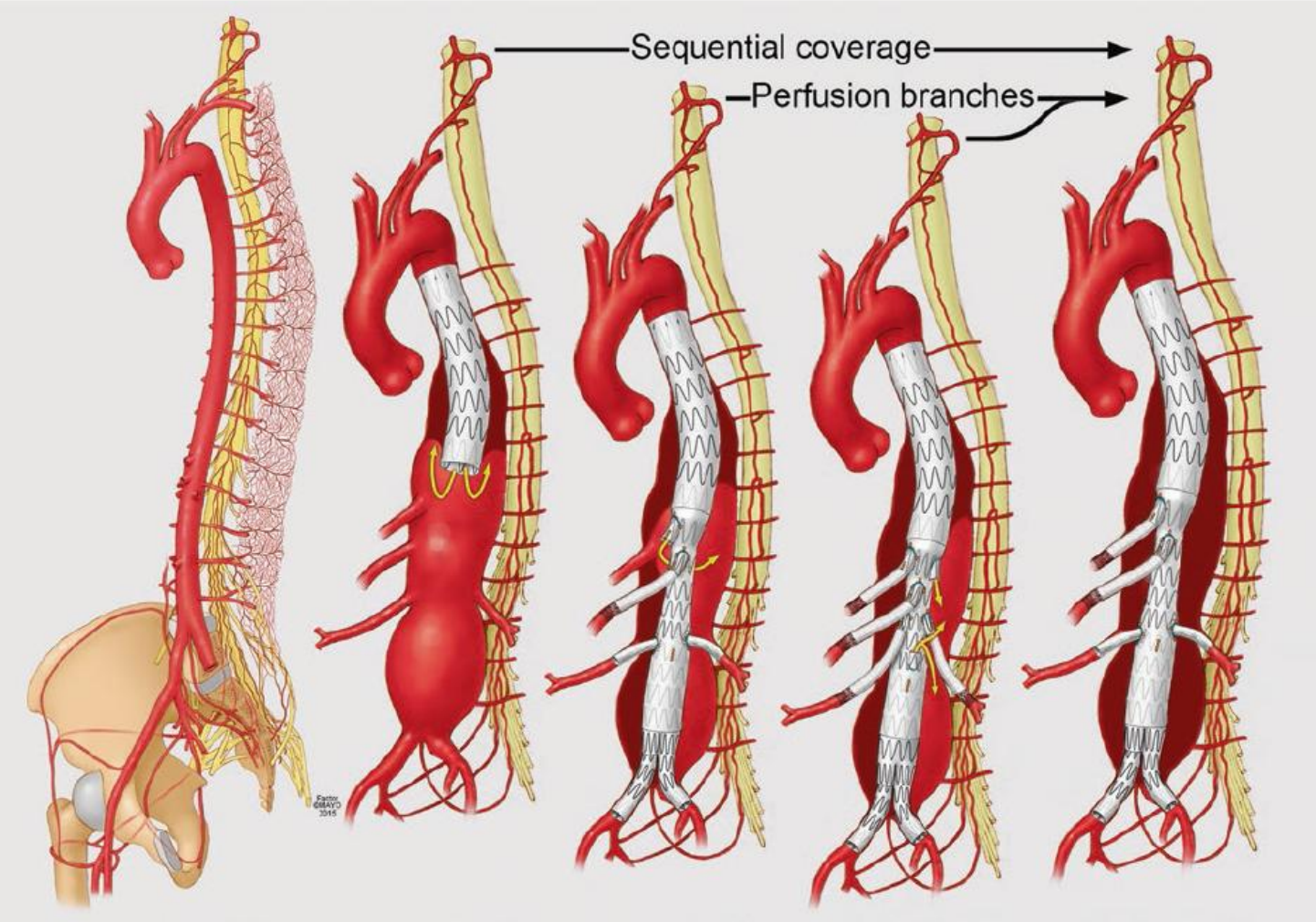

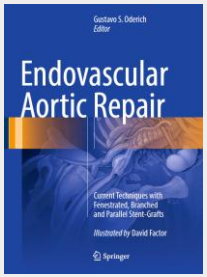

Oderich 2017

Evoked Potentials (MEP and SSEP) Monitoring

MEP monitoring has been successfully used to detect SCI during TAAA repair and to reduce the incidence of neurologic complications

Jacobs MJ J Vasc Surg 2006

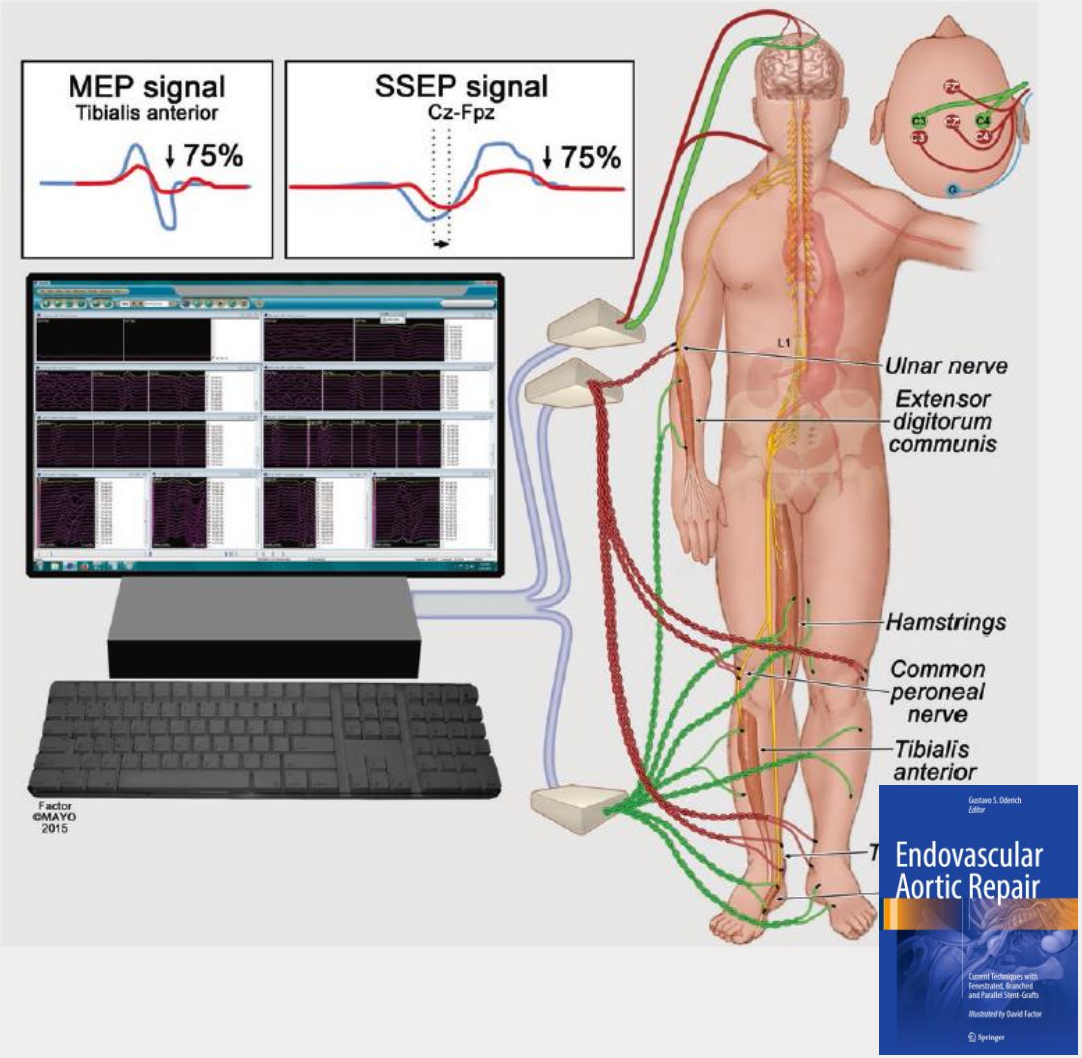

Oderich 2017

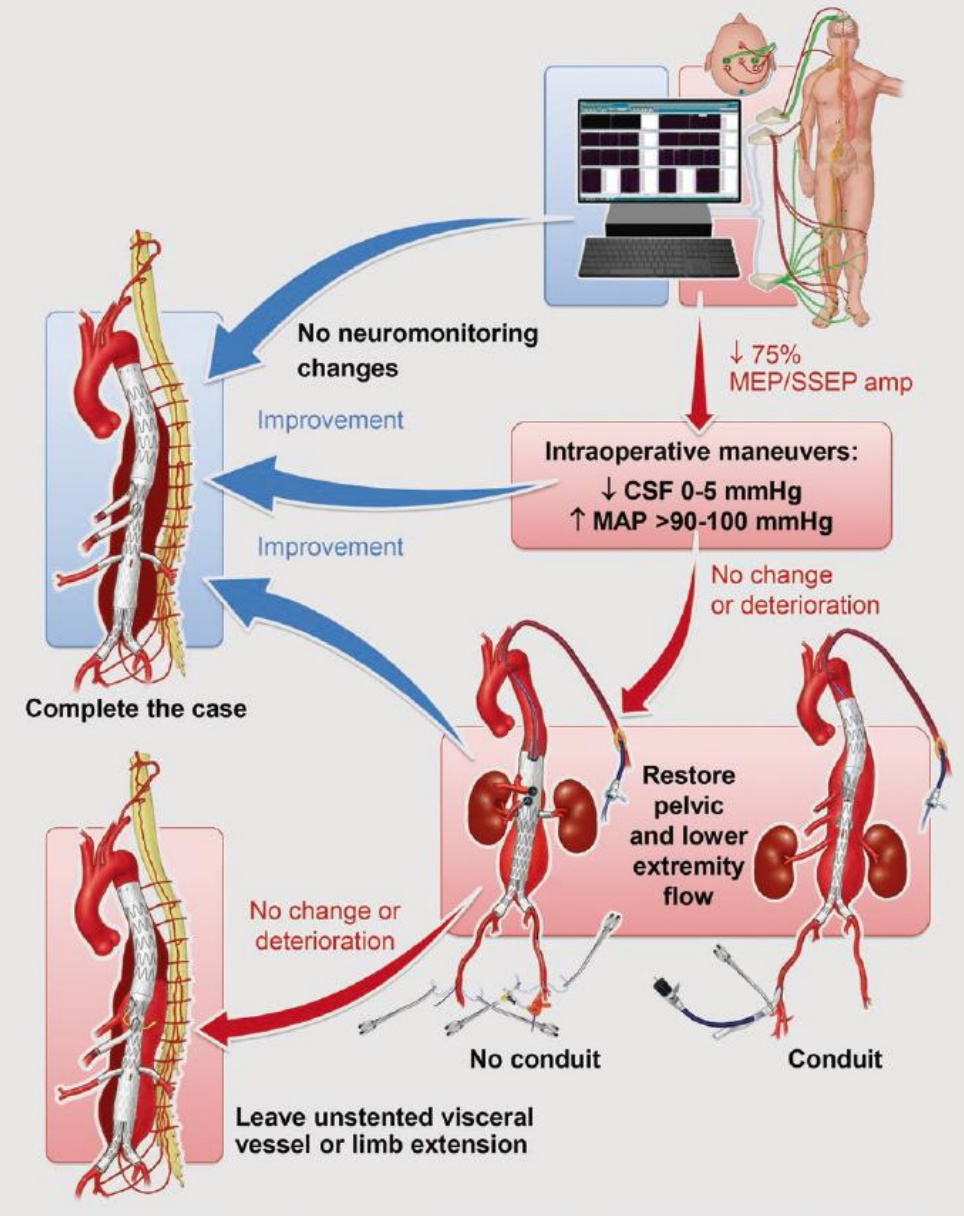

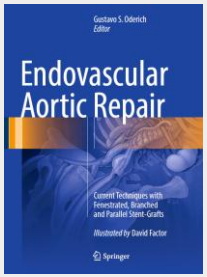

Oderich 2017

Collateral Network Concept

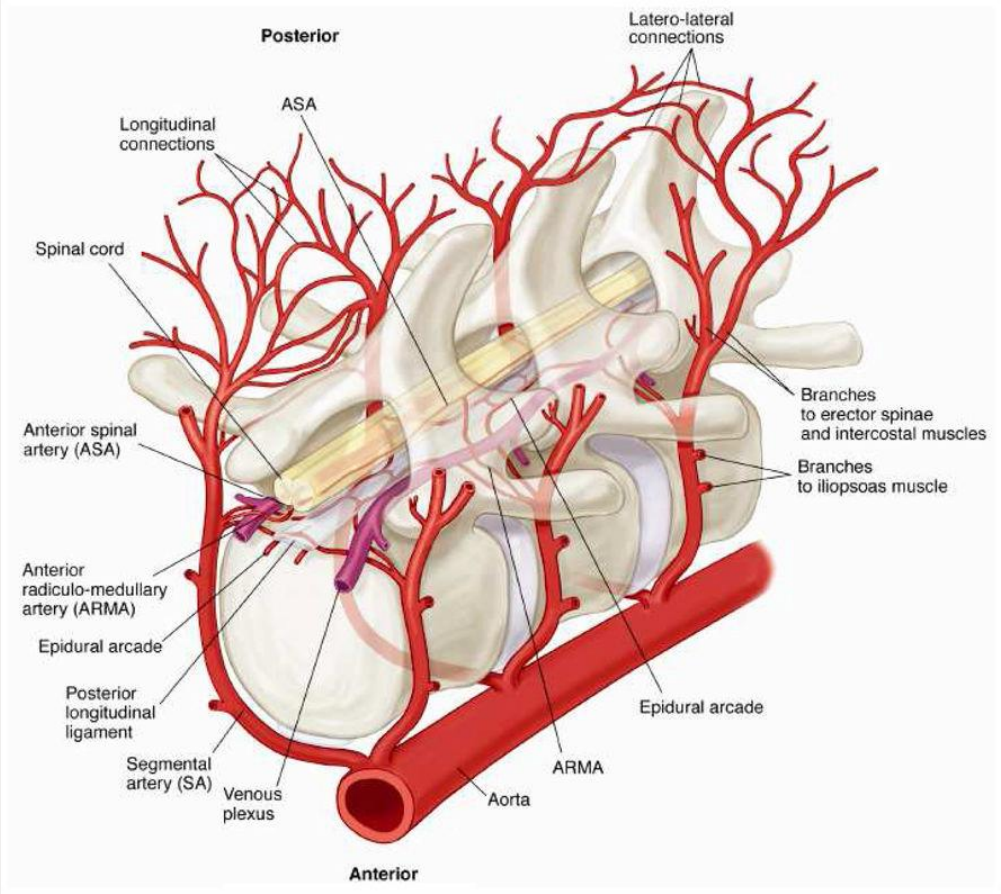

Paraspinal Muscles

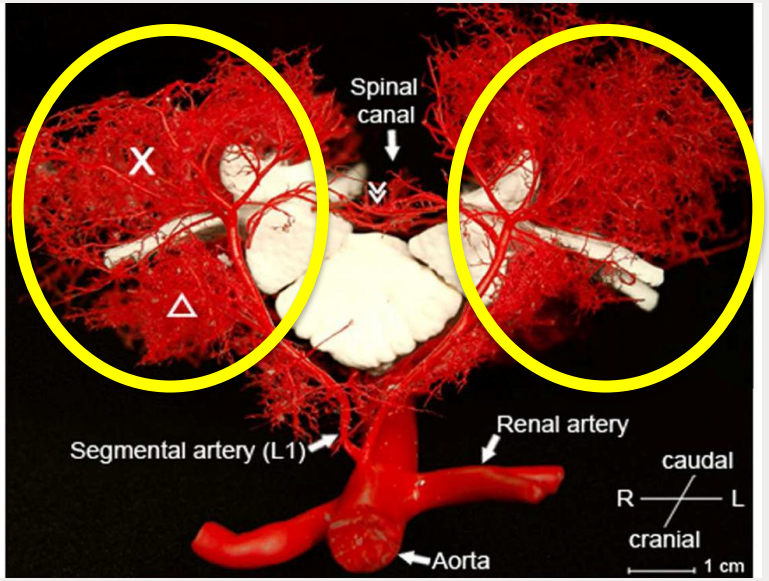

Etz, et al. *J Thorac Cardiovasc Surg* 2011

Collateral Network Near-infrared spectroscopy (cnNIRS)

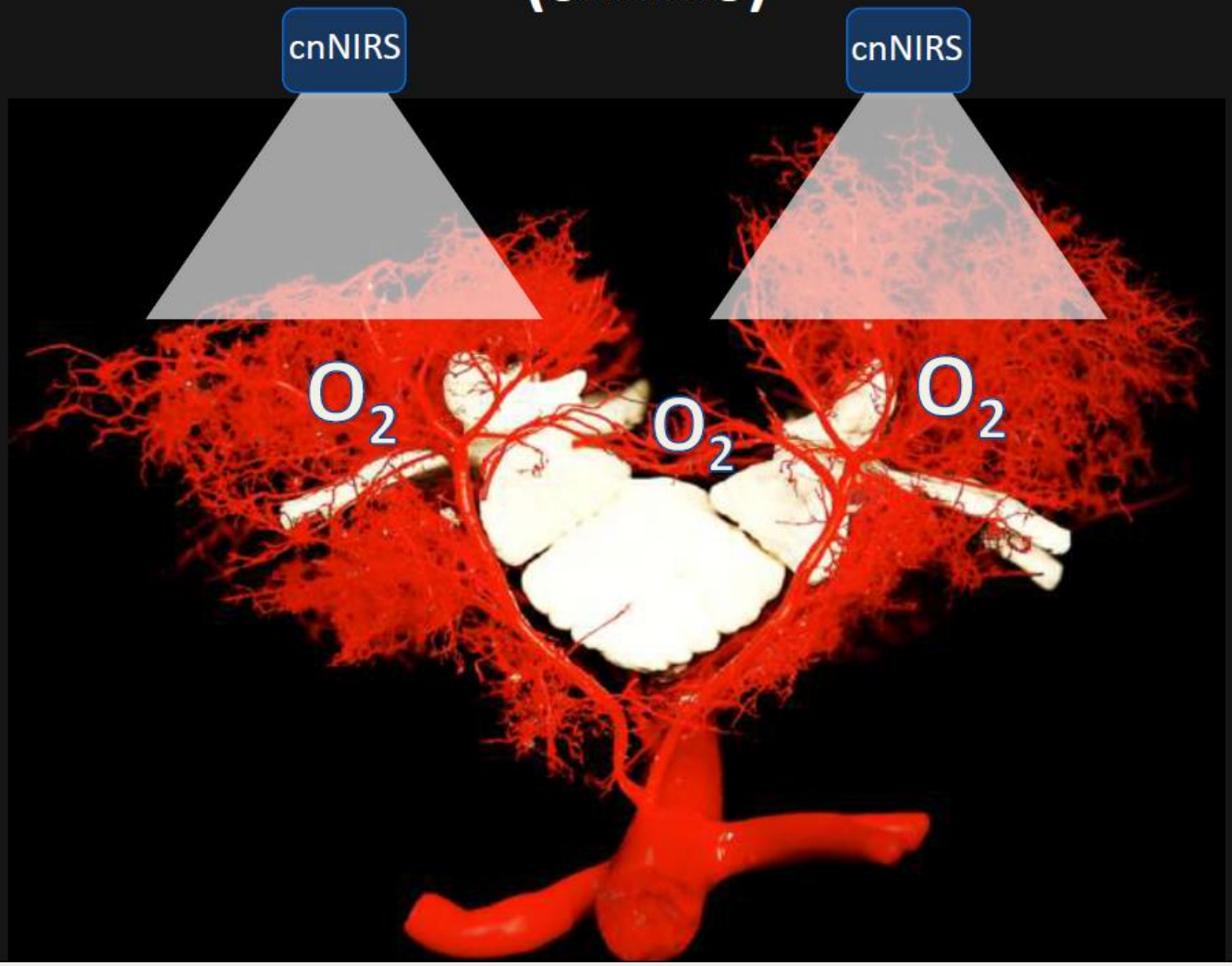

Etz *LINC meeting* 2018

Potential Benefits of NIRS

- LE ischemia and anesthetics don’t interfere with measurements
- Widely available and inexpensive
- Non-invasive
- Minimal technical requirements
- Can be easily continued post-operatively

Non-invasive cnNIRS

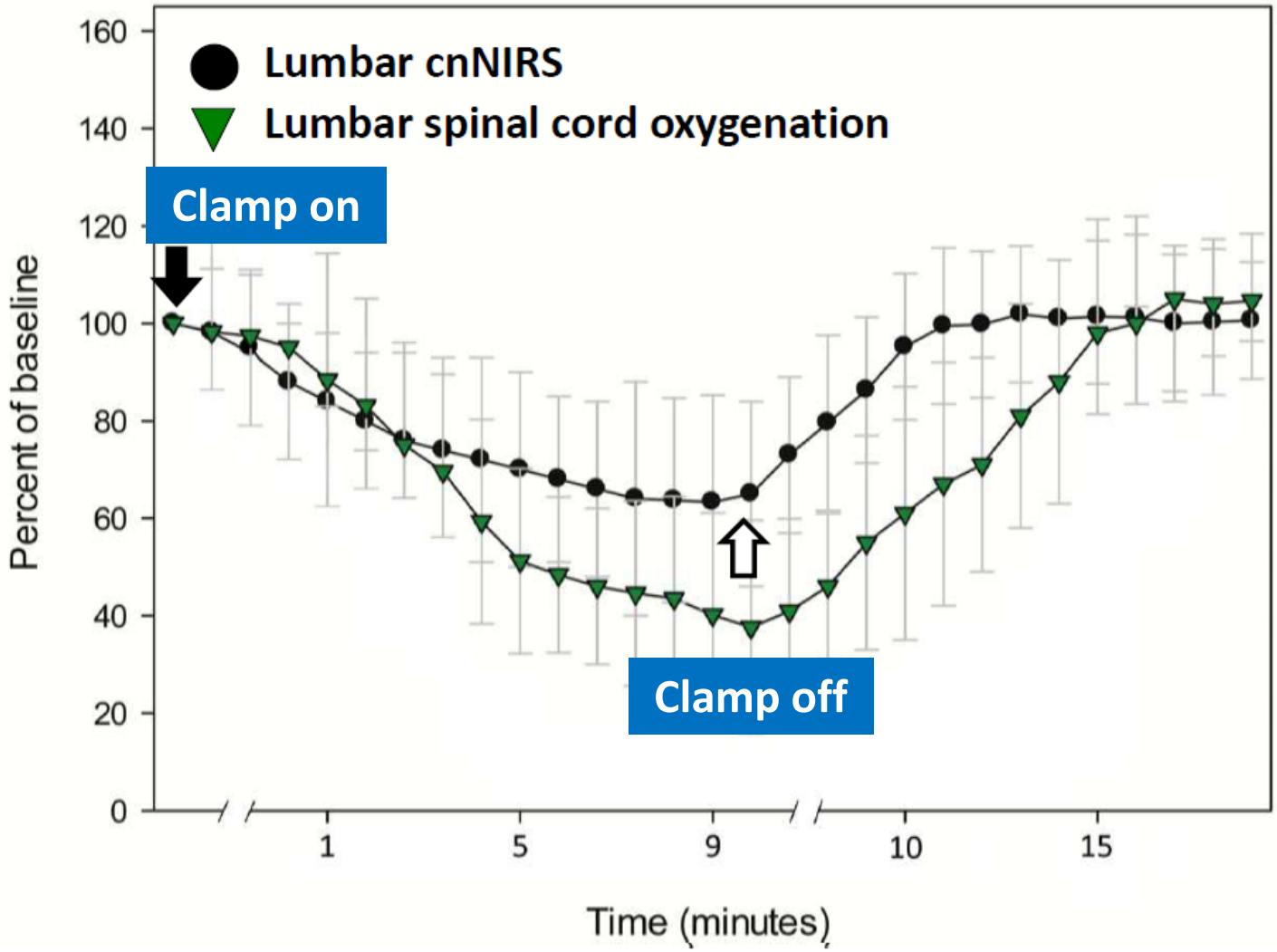

Question: lumbar **cnNIRS** = **Spinal cord** oxygenation? ☑

Etz *LINC meeting* 2018

Lumbar cnNIRS and Spinal Cord Oxygenation

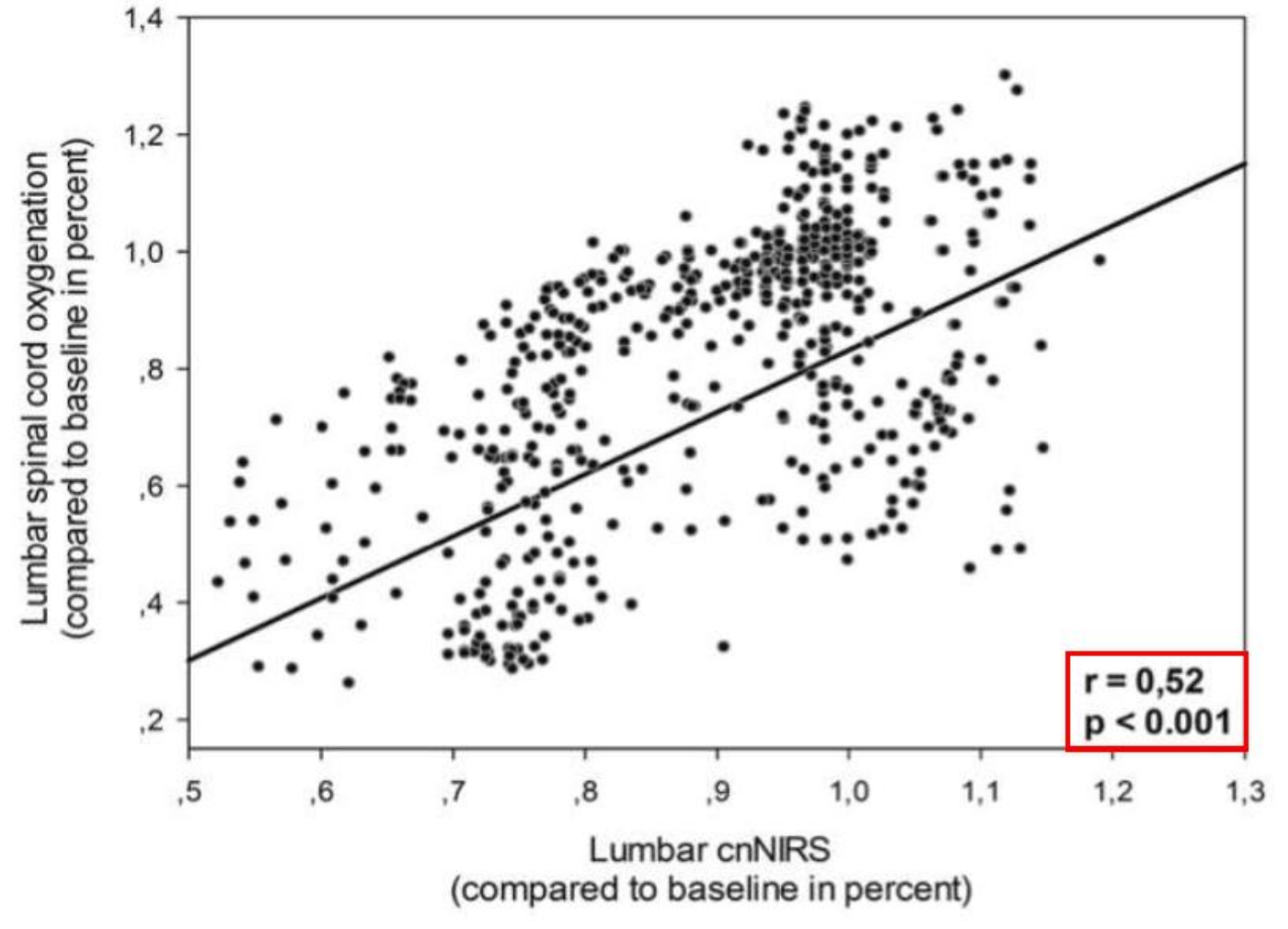

Etz *LINC meeting* 2018

NIRS Monitoring of Spinal Cord Collateral Network Perfusion

Near-infrared Spectroscopy Monitoring of the Collateral Network Prior to, During, and After Thoracoabdominal Aortic Repair: A Pilot Study

C.D. Etz [a,b,*,d], K. von Aspern [a,d], S. Gudehus [c], M. Luehr [a], F.F. Girrbach [a], J. Ender [c], M. Borger [a], F.W. Mohr [a]

[a] Department of Cardiac Surgery, University of Leipzig, Heart Center Leipzig, Saxony, Germany
[b] Department of Cardiothoracic Surgery, Mount Sinai School of Medicine, New York, NY, USA
[c] Department of Anesthesiology, University of Leipzig, Heart Center Leipzig, Saxony, Germany

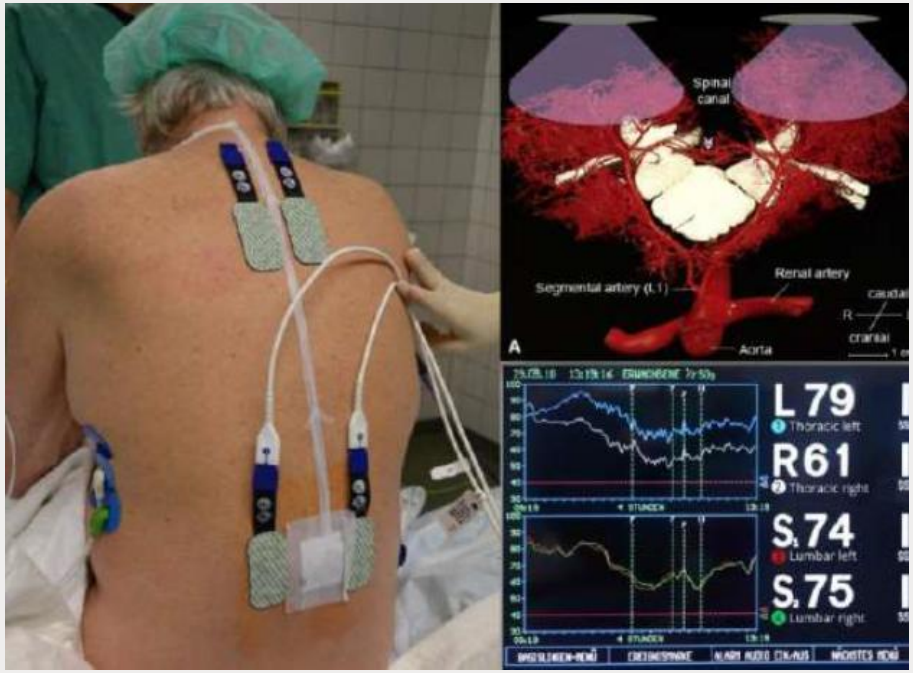

Etz, et al. *Eur J Vasc Endovasc Surg* 2013

NIRS Monitoring of Spinal Cord Collateral Network Perfusion

Near-infrared Spectroscopy Monitoring of the Collateral Network Prior to, During, and After Thoracoabdominal Aortic Repair: A Pilot Study

C.D. Etz [a,b,*,d], K. von Aspern [a,d], S. Gudehus [c], M. Luehr [a], F.F. Girrbach [a], J. Ender [c], M. Borger [a], F.W. Mohr [a]

[a] Department of Cardiac Surgery, University of Leipzig, Heart Center Leipzig, Saxony, Germany
[b] Department of Cardiothoracic Surgery, Mount Sinai School of Medicine, New York, NY, USA
[c] Department of Anesthesiology, University of Leipzig, Heart Center Leipzig, Saxony, Germany

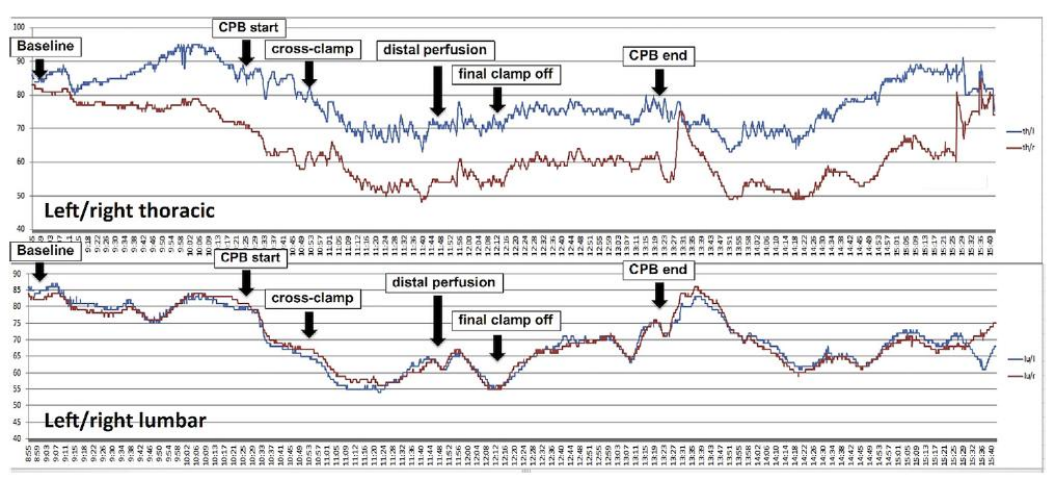

- Aortic cross clamp and CPB change lumbar CN perfusion
- SCI associated with greater reduction in saturations

Etz, et al. *Eur J Vasc Endovasc Surg* 2013

NIRS Monitoring of Spinal Cord Collateral Network Perfusion

Near-infrared Spectroscopy Monitoring of the Collateral Network Prior to, During, and After Thoracoabdominal Aortic Repair: A Pilot Study

C.D. Etz [a,b,*,d], K. von Aspern [a,d], S. Gudehus [c], M. Luehr [a], F.F. Girrbach [a], J. Ender [c], M. Borger [a], F.W. Mohr [a]

[a] Department of Cardiac Surgery, University of Leipzig, Heart Center Leipzig, Saxony, Germany
[b] Department of Cardiothoracic Surgery, Mount Sinai School of Medicine, New York, NY, USA
[c] Department of Anesthesiology, University of Leipzig, Heart Center Leipzig, Saxony, Germany

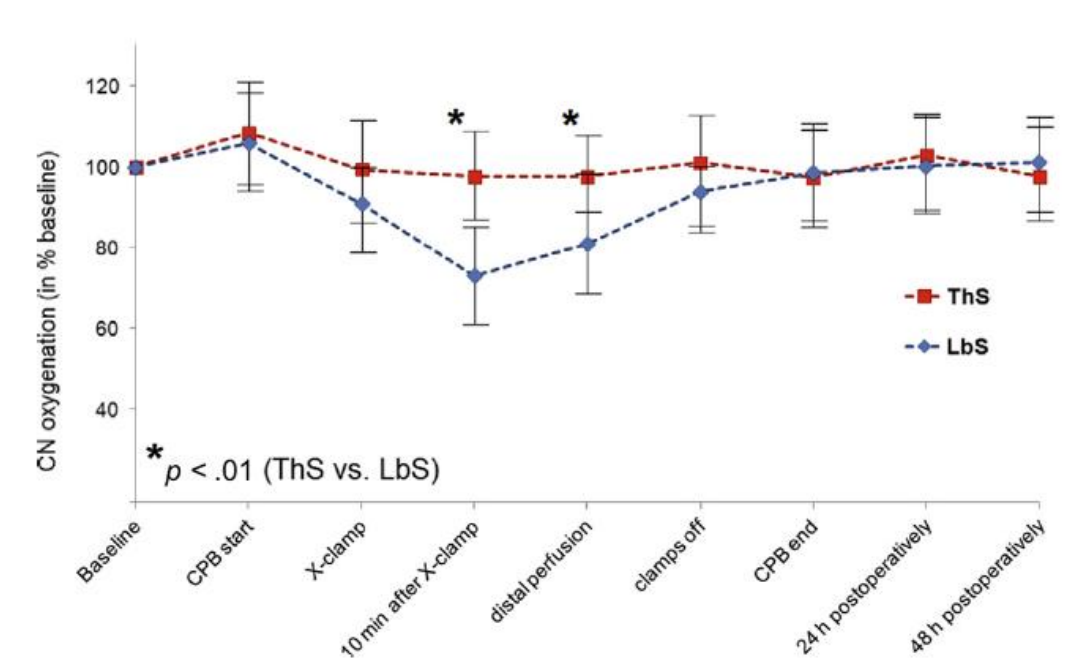

Etz, et al. *Eur J Vasc Endovasc Surg* 2013

NIRS Correlation with MEPs

Spinal Near-Infrared Spectroscopy Measurements During and After Thoracoabdominal Aortic Aneurysm Repair: A Pilot Study

Reinout P. E. Boezeman, MD, Eric P. van Dongen, MD, PhD, Wim J. Morshuis, MD, PhD, Uday Sonker, MD, Eduard H. J. F. Boezeman, MD, PhD, Frans G. J. Waanders, ECCP, and Jean-Paul P. M. de Vries, MD, PhD

Departments of Vascular Surgery, Anesthesiology and Intensive Care, Cardiothoracic Surgery, Clinical Neurophysiology, and Perfusion, St. Antonius Hospital, Nieuwegein, the Netherlands

15 patients; open TAAA repair

All had NIRS + MEP monitoring

No patients suffered SCI

- NIRS changes correlated with MEP changes ($p = 0.037$)

Boezeman, et al. *Eur J Vasc Endovasc Surg* 2015

Spinal Cord Protection – Role of NIRS?

CSF Drainage

NIRS Monitoring

- CSF Drainage
- MAP > 90 mmHg
- Transfusion to Hct ≥ 30
- Early restoration of LE perfusion
- Staged Procedures
- **NIRS monitoring**

Test Occlusion of Last Branch

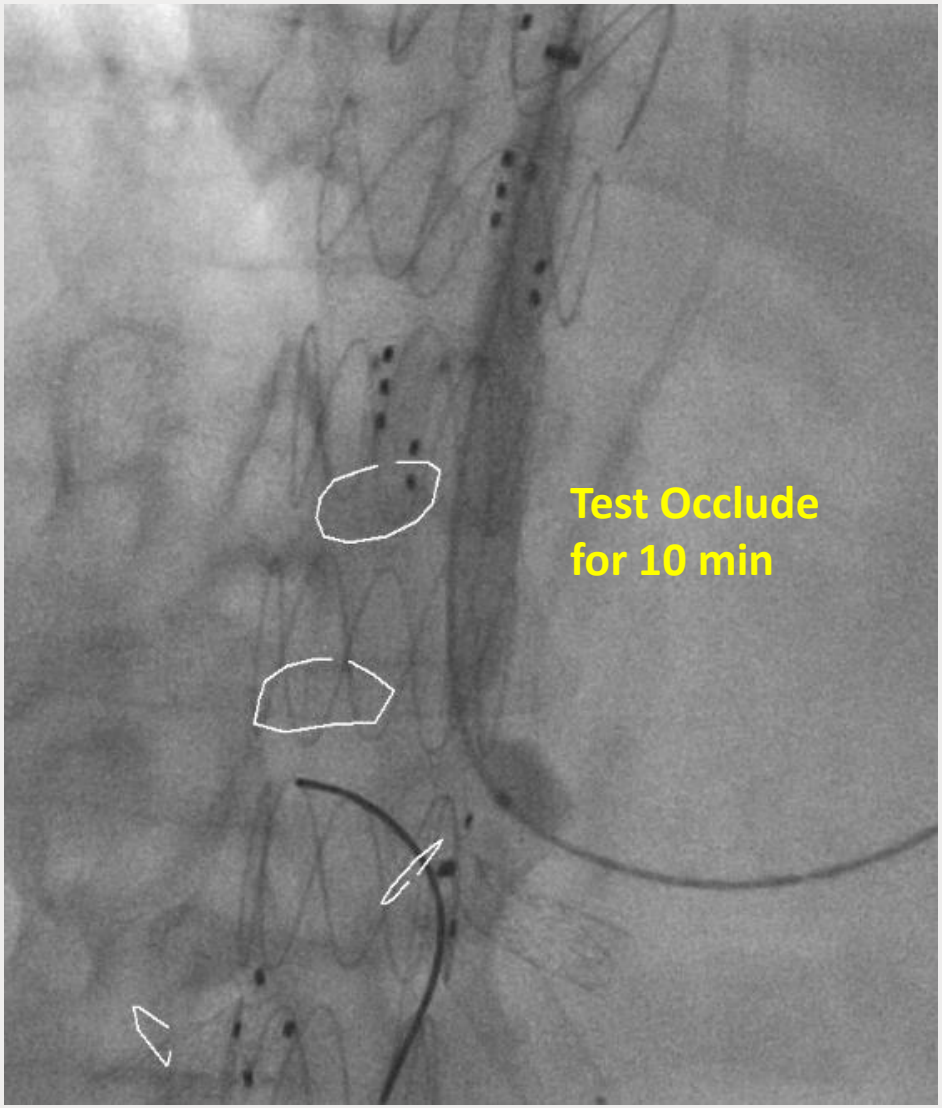

NIRS no Δ → Complete repair

NIRS ↓ Lb sat → Leave branch open (TASP)

Cornell Experience: Complex EVAR and NIRS

- Physician-sponsored IDE study
- Endovascular TAAA repair with F/B-EVAR
- NIRS last 25 consecutive patients
- No cases SCI
- Study ongoing

Intraoperative NIRS Monitoring

Thoracic

Lumbar

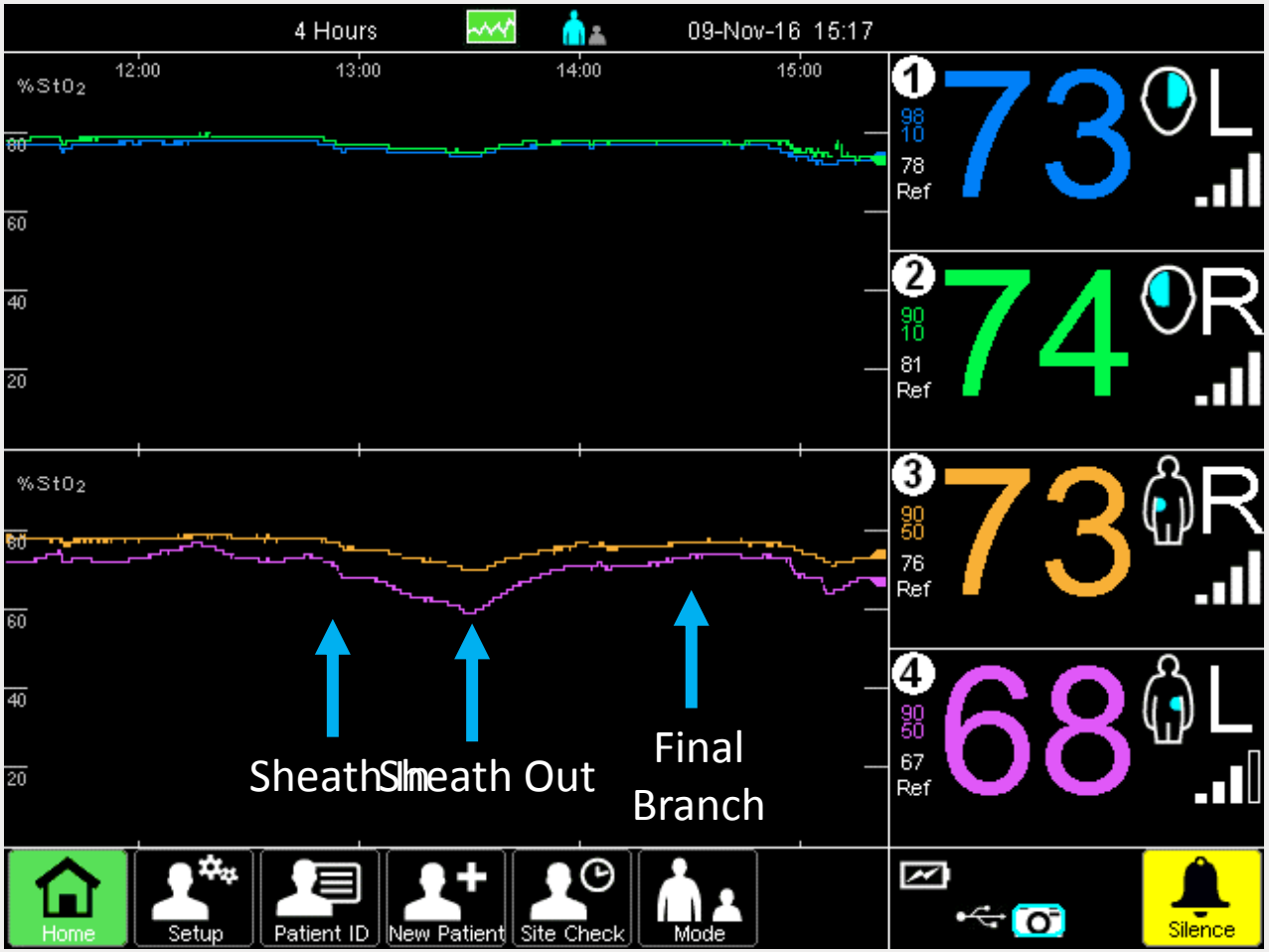

Impact of Early Pelvic & Extremity Reperfusion on SCI

The Impact of Early Pelvic and Lower Limb Reperfusion and Attentive Peri-operative Management on the Incidence of Spinal Cord Ischemia During Thoracoabdominal Aortic Aneurysm Endovascular Repair

B. Maurel [a], N. Delclaux [a], J. Sobocinski [a], A. Hertault [a], T. Martin-Gonzalez [a], M. Moussa [a], R. Spear [a], M. Le Roux [a], R. Azzaoui [a], M. Tyrrell [b], S. Haulon [a,*]

[a] Aortic Centre, Hôpital Cardiologique, CHRU de Lille, INSERM U1008, Université Lille Nord de France, 59037 Lille Cedex, France
[b] King's Health Partners, London, UK

- CSF drainage, MAP > 90, aggressive blood transfusion
- <u>Early withdrawal of large femoral sheaths to reperfuse pelvis and LE</u>
- > 10-fold drop in SCI incidence:
  - 14% prior to protocol (43 patients)
  - 1.2% after protocol (161 patients)

Warein *Eur J Vasc Endovasc Surg* 2016

Conclusions

Spinal cord perfusion monitoring with NIRS during complex EVAR remains investigational

Preliminary clinical data suggests NIRS may be a useful adjunct to monitor spinal cord collateral network perfusion during open TAAA repair

Study of NIRS during complex EVAR is ongoing

DIVISION OF VASCULAR AND ENDOVASCULAR SURGERY

AMAZING THINGS ARE HAPPENING HERE

Weill Cornell Medical College

NewYork-Presbyterian
Weill Cornell Medical Center