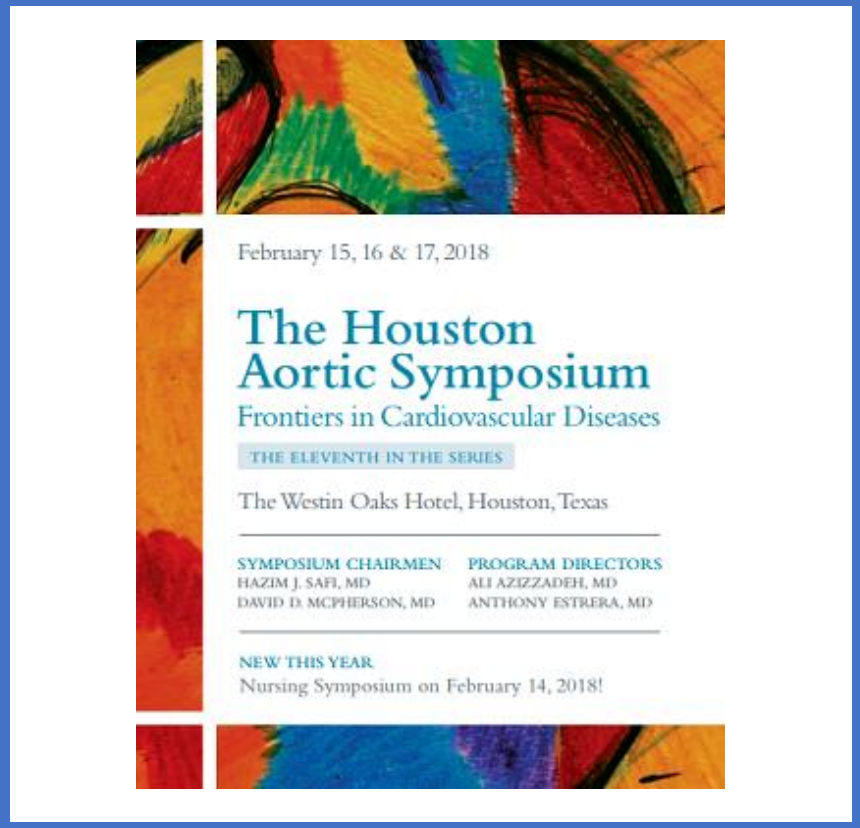

UNIVERSITY OF CALGARY

Transperitoneal Reversed Elephant Trunk Technique

RD Moore MD FRCSC FACS
Kenton Rommens MD FRCSC

UNIVERSITY OF CALGARY

No disclosures

Peter Lougheed Centre

Thoraco-abdominal aneurysm repair

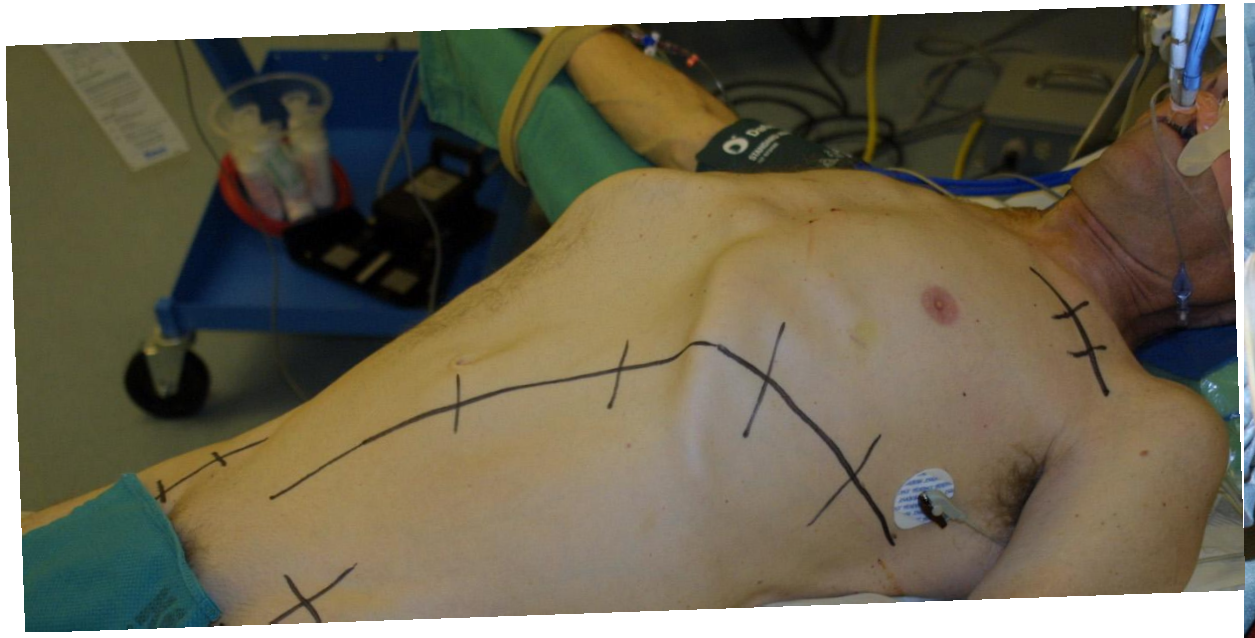

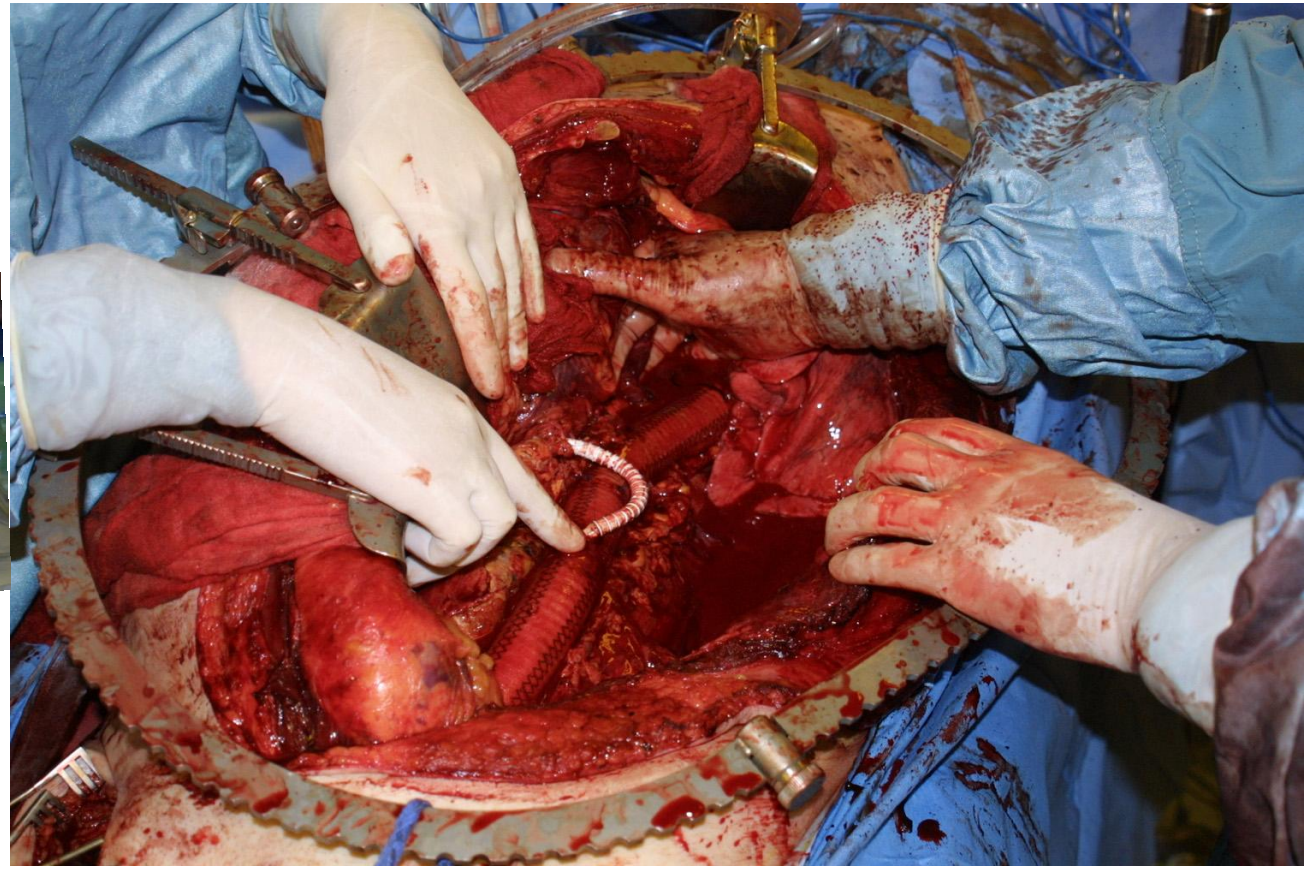

High morbidity and mortality rates even in high volume centres

Increasing Mortality Trends for Open Infrarenal and Thoracoabdominal Aneurysm Repairs in the Endovascular Era

Journal of Vascular Surgery
September 2017Volume 66, Issue 3, Page e73

Reduced risks with hybrid techniques

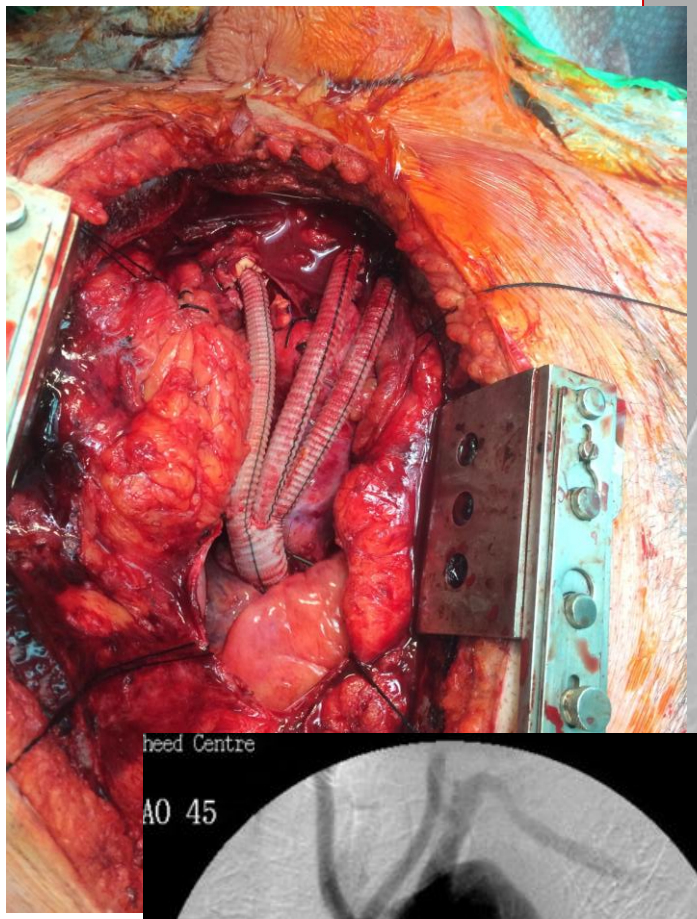

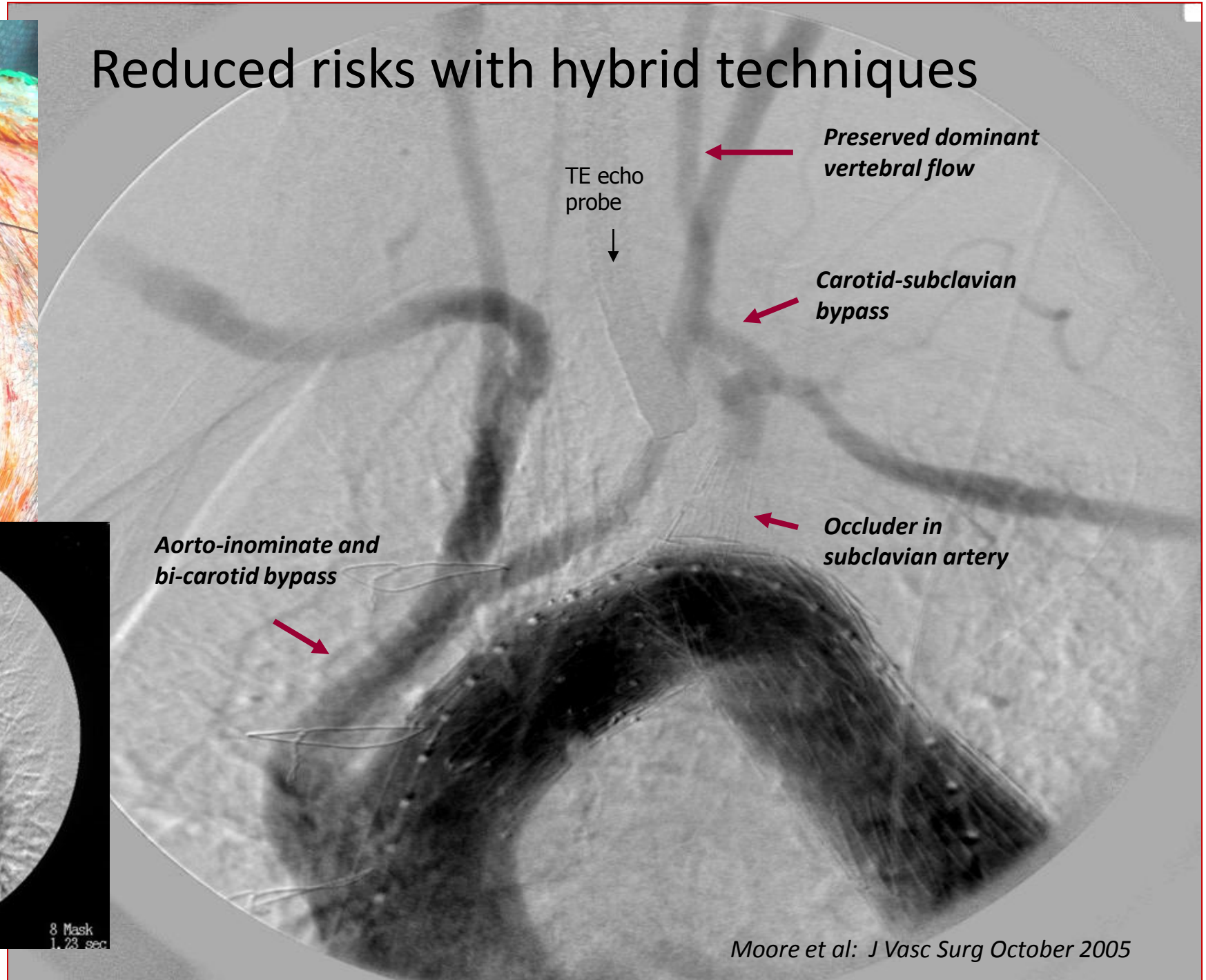

Moore et al: J Vasc Surg October 2005

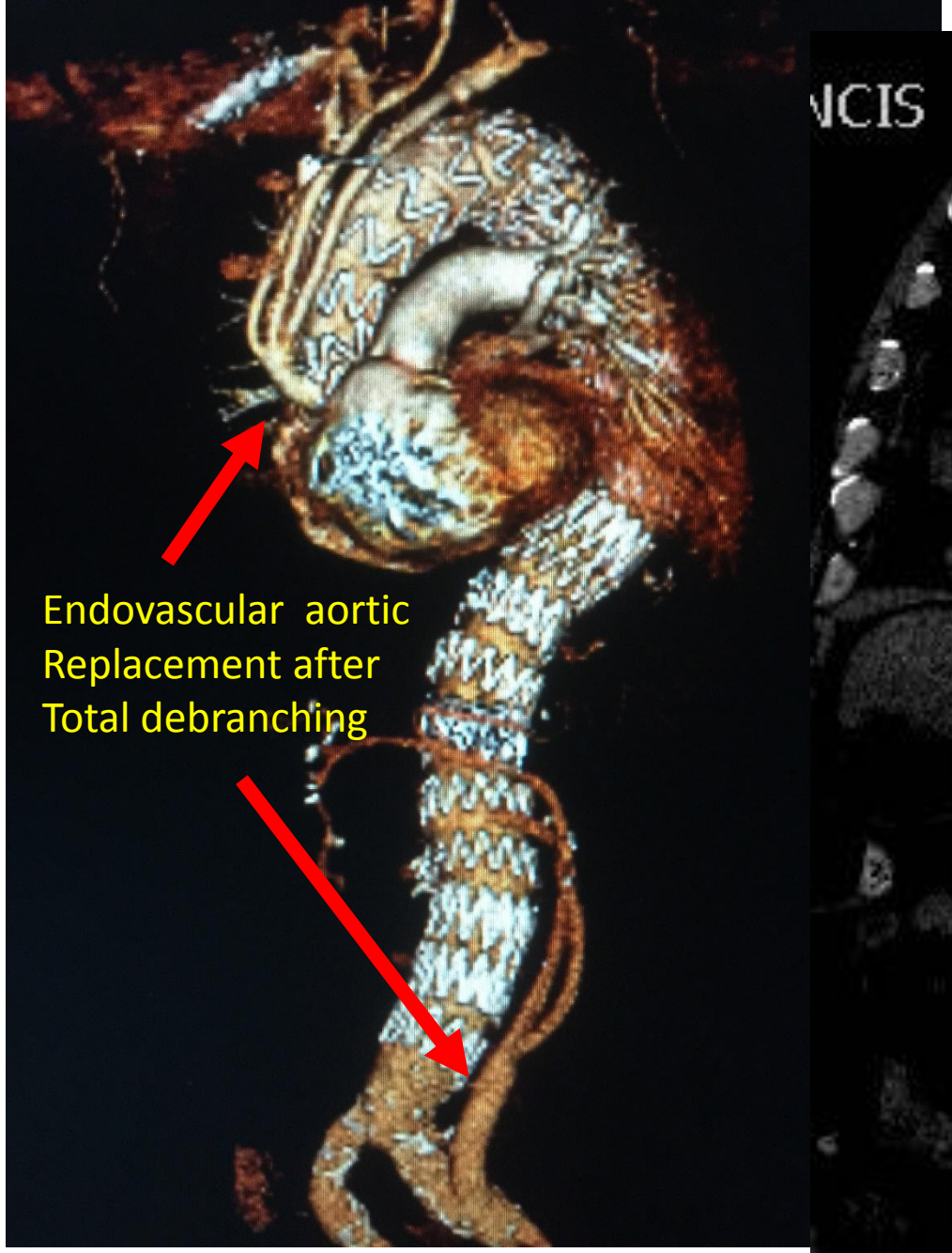
Endovascular aortic
Replacement after
Total debranching

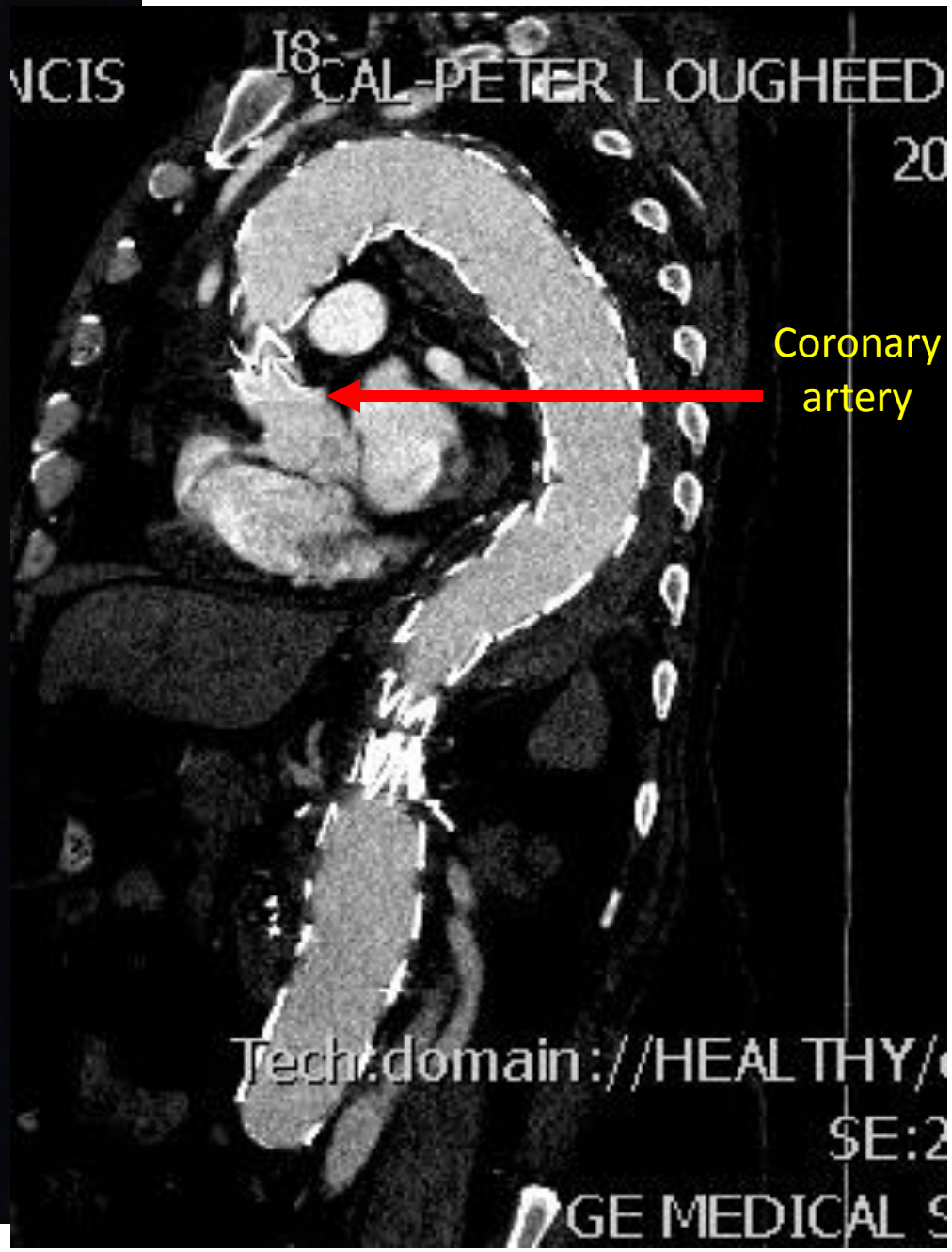
NCIS
18
CAL-PETER LOUGHEED
20
Coronary
artery
Tech:domain://HEALTHY/
SE:2
GE MEDICAL S

Endovascular Reconstructions - Branched and Fenestrated Technology:

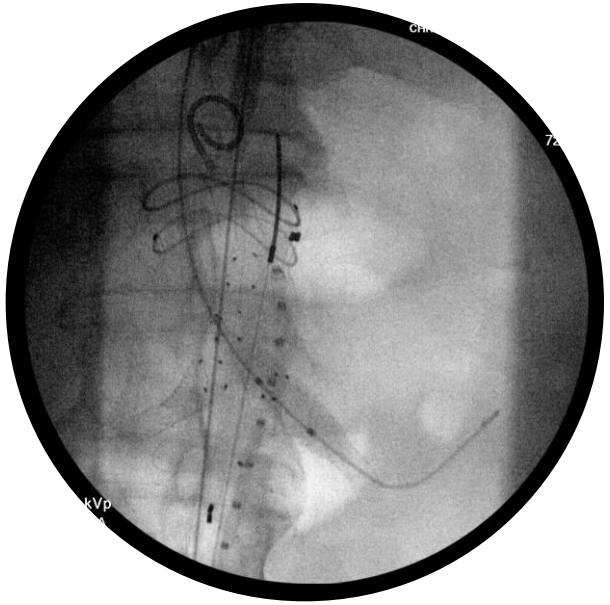

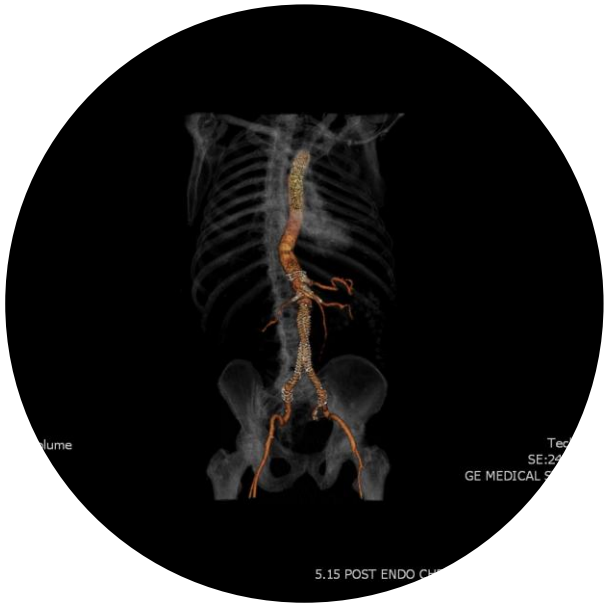

- limited by the need for landing zones
- Not suitable for patients with Connective Tissue disorders
- requires specialized expertise and equipment
- branch stent failure

[Endovascular aortic repair: Current techniques with fenestrated, branched and parallel stent-grafts]
Journal of Vascular Surgery, Vol. 67, Issue 2, p676–677 February 2018

[Performance of Bridging Stent Grafts in Fenestrated and Branched Aortic Endografting]
Journal of Vascular Surgery, Vol. 62, Issue 1, p267 July 2015

CASE REPORT:

69Y female

Crawford Extent II thoracoabdominal aneurysm 7.2 cm

Severe COPD

CAD, previous PCI x2

Stage 1:
Total Thoracic Endovascular Coverage

- Cook Alpha
- 32mm x 209mm
- 34mm x 157mm

- 1 month delay to allow for cord collaterals to develop

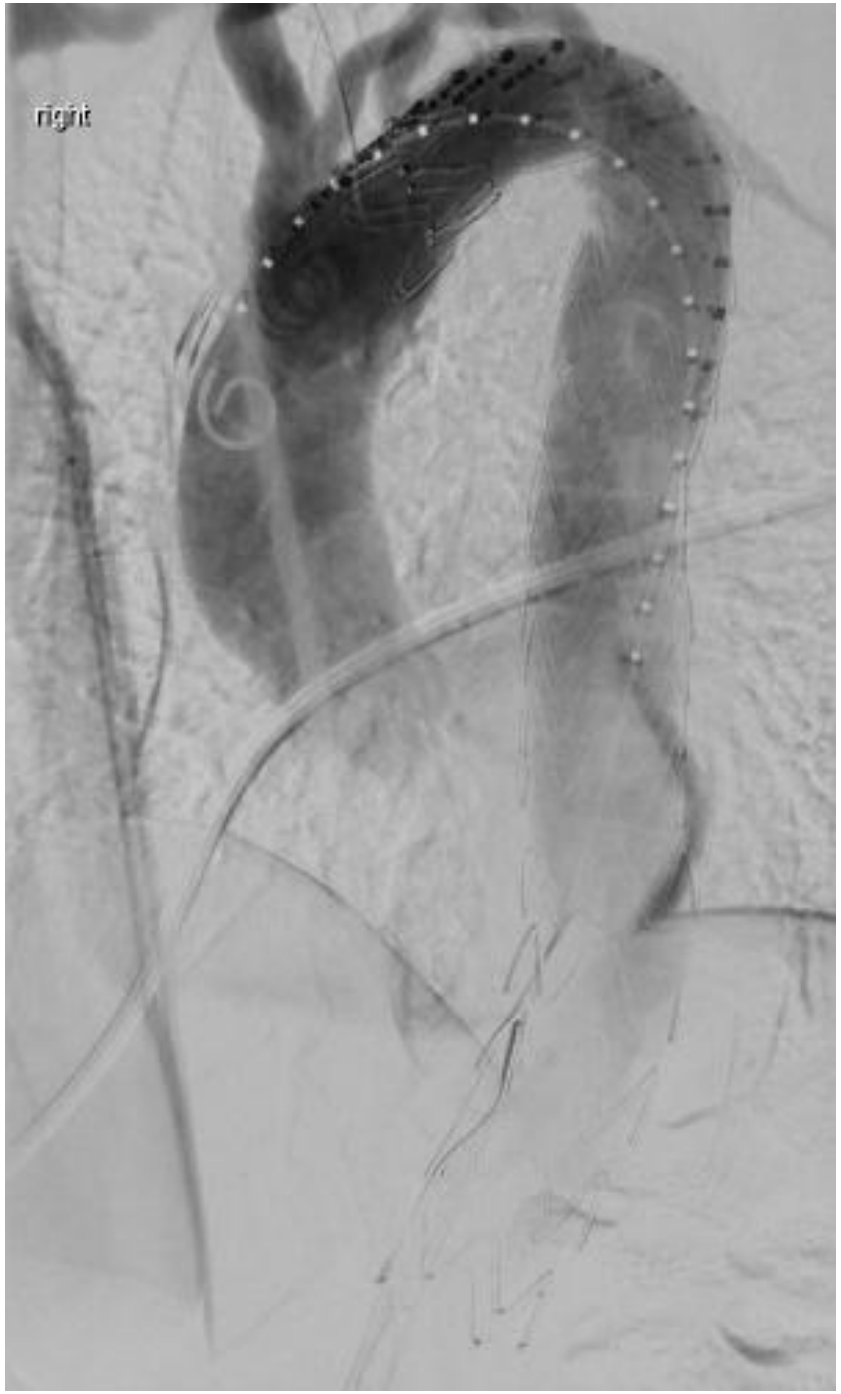

Literature Review:

Reversed Frozen Elephant Trunk Technique to Treat a Type II Thoracoabdominal Aortic Aneurysm

1–4

DOI: 10.1177/1526602816678992
www.jevt.org
SAGE

E. Sebastian Debus, MD, PhD[1], Tilo Kölbel, MD, PhD[1], Sabine Wipper, MD, PhD[1], Holger Diener, MD[1], Beate Reiter, MD[2], Christian Detter, MD, PhD[2], and Nikolaos Tsilimparis, MD, PhD[1]

- Used in a 29Y Marfan's patient with previous TEVAR for a complicated Type B dissection
- "Turned around" Anaconda Thoraflex device
- Avoided morbidity of open thoracic component and proximal clamp

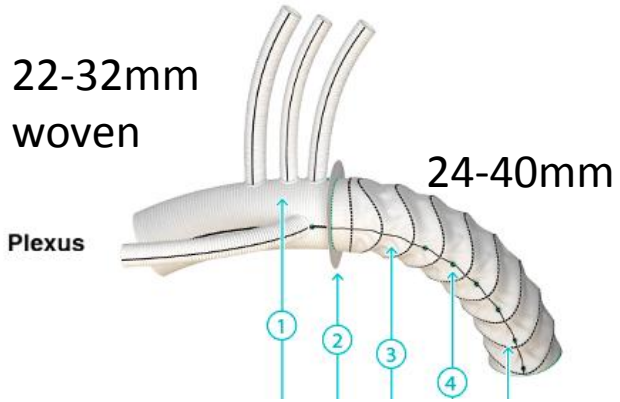

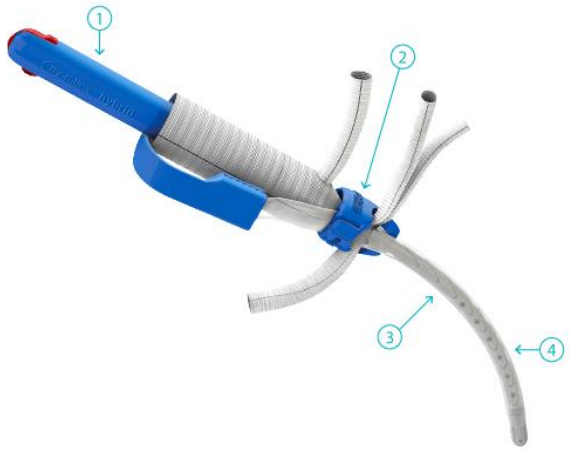

Thoraflex Hybrid

Health Canada Approved Device

Open repair combined with endovascular stent

Stage 2: Transperitoneal Retrograde Elephant Trunk Repair:

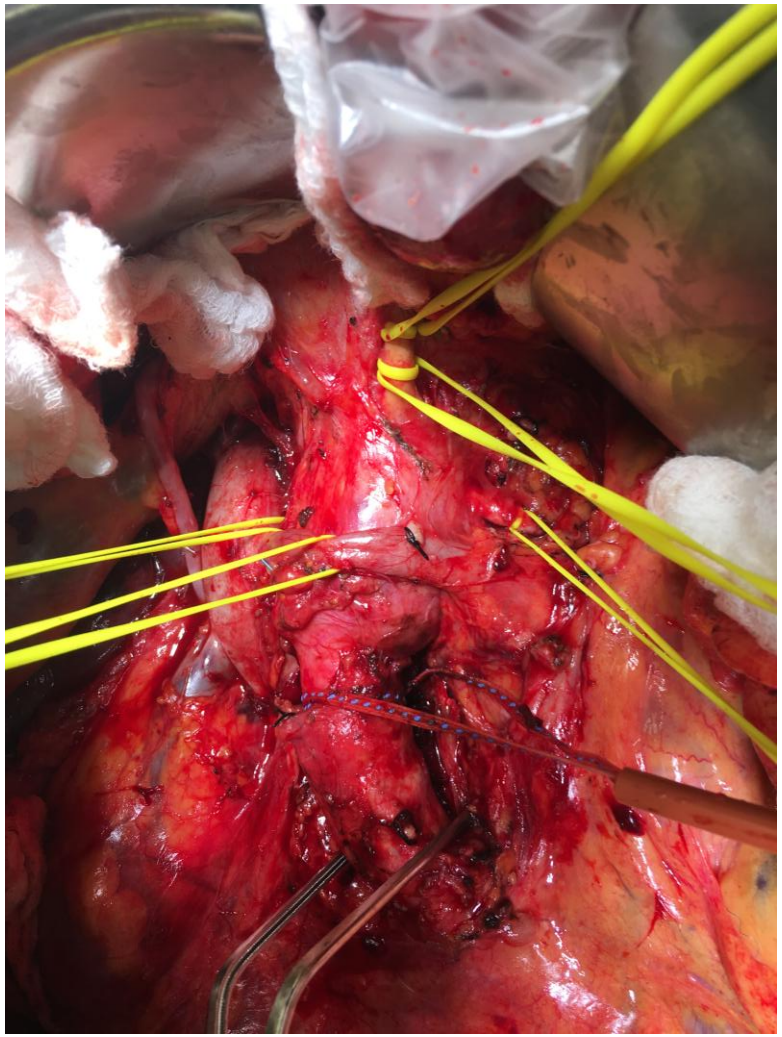

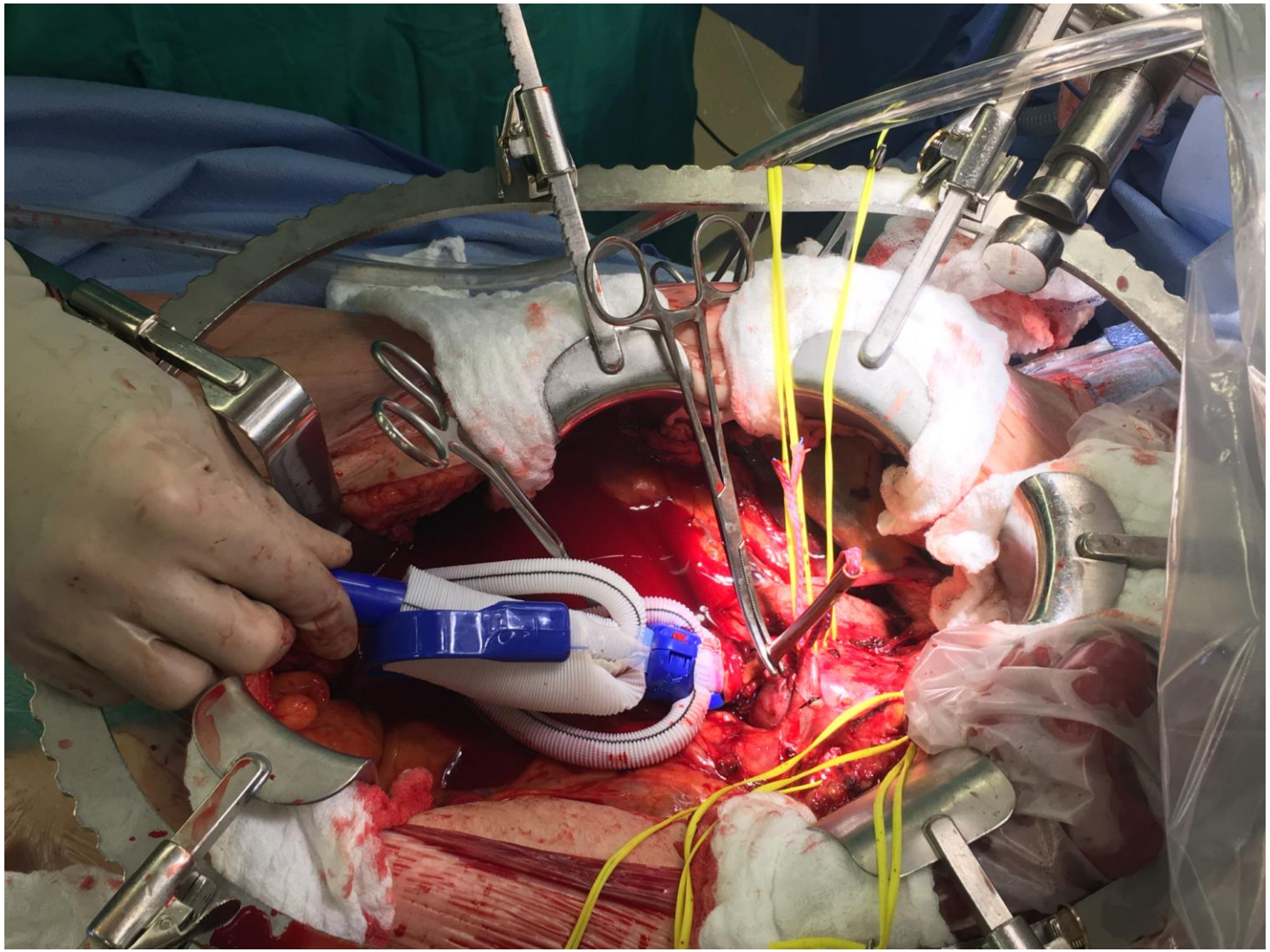

- 38 x 150mm
- Thoraflex

- 38 x 117mm
- Cook Alpha

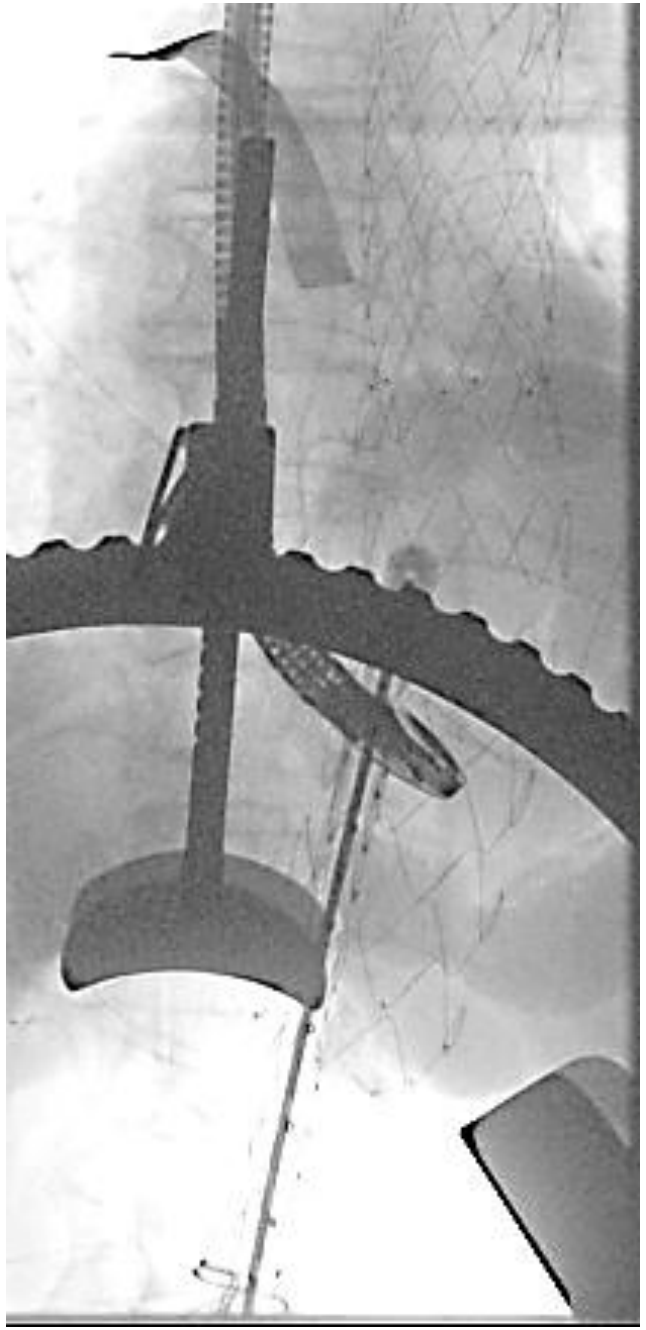

Ligation celiac axis with renal-hepatic bypass

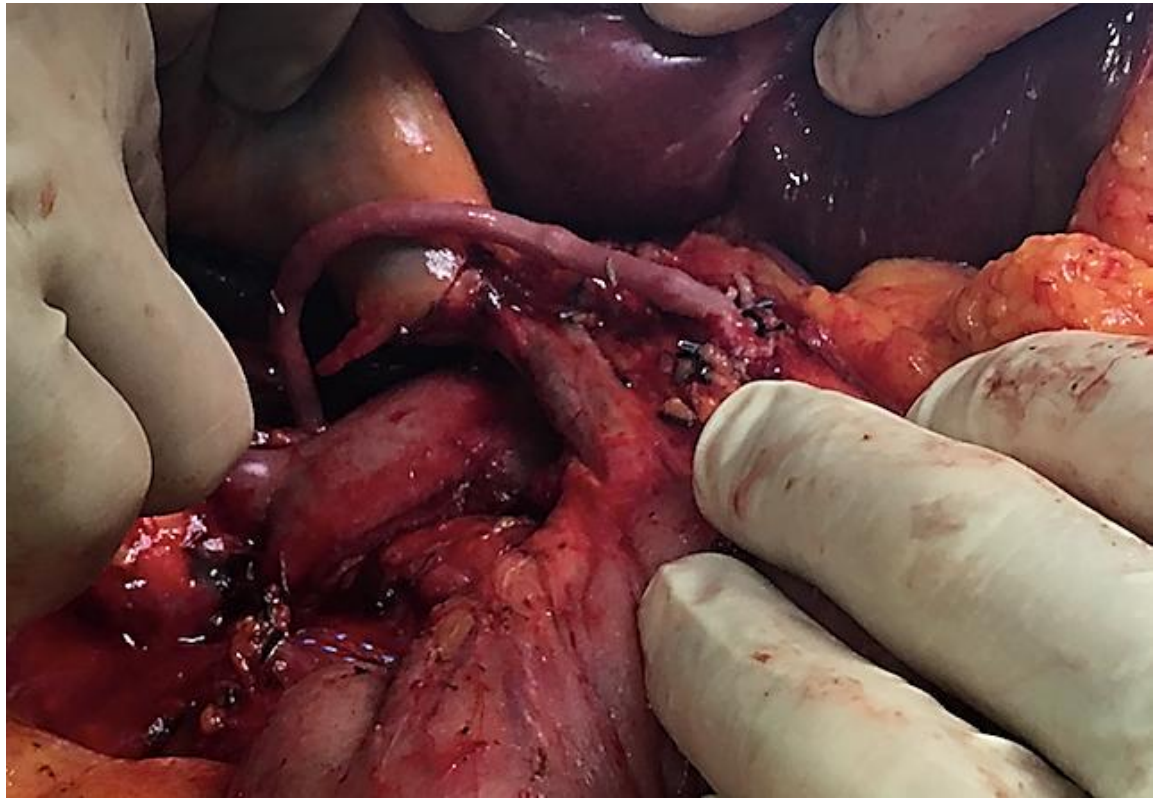

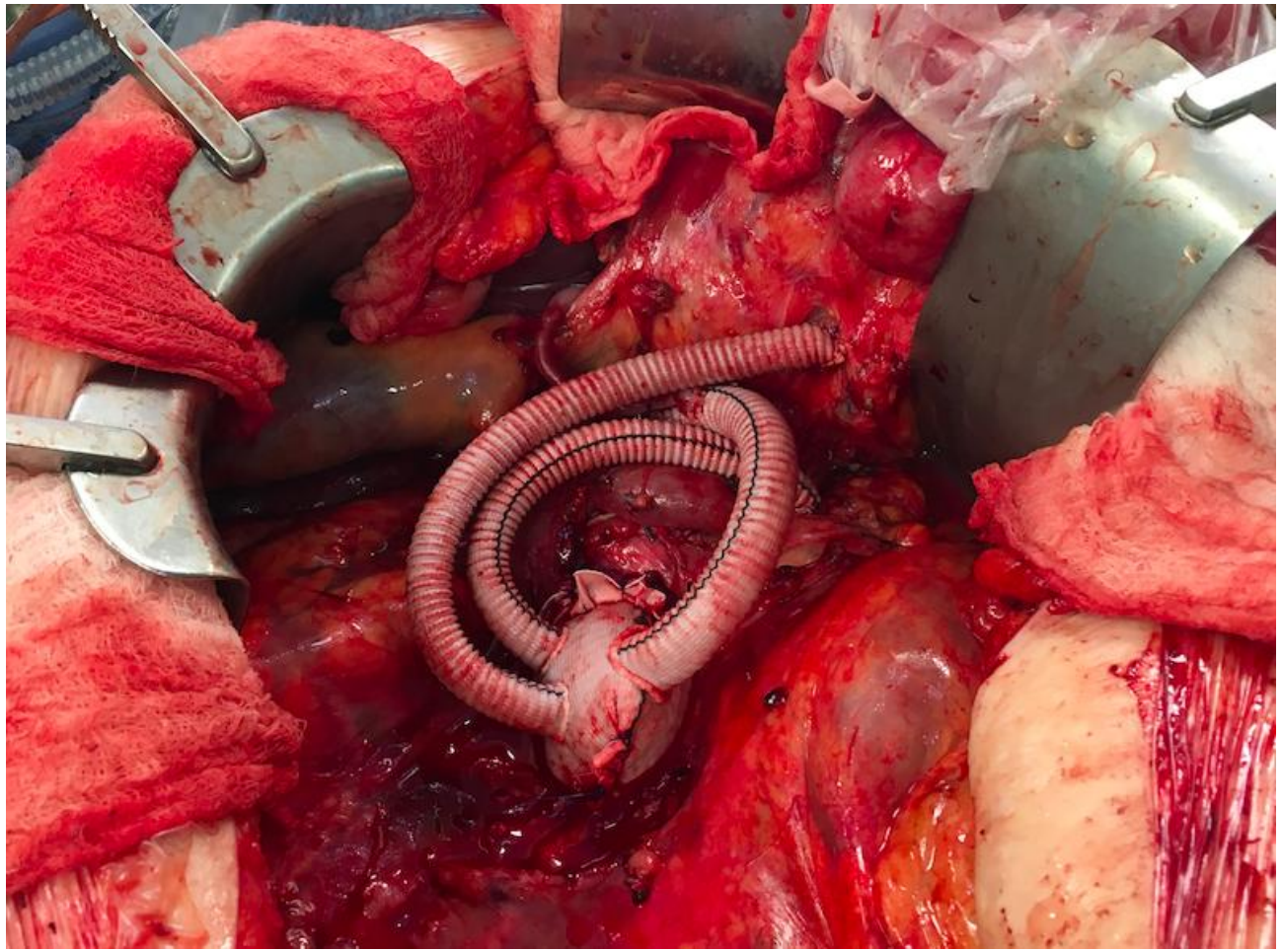

3 month Follow up:

A: reno-hepatic bypass

B: right renal branch

C: SMA branch

D: left renal branch

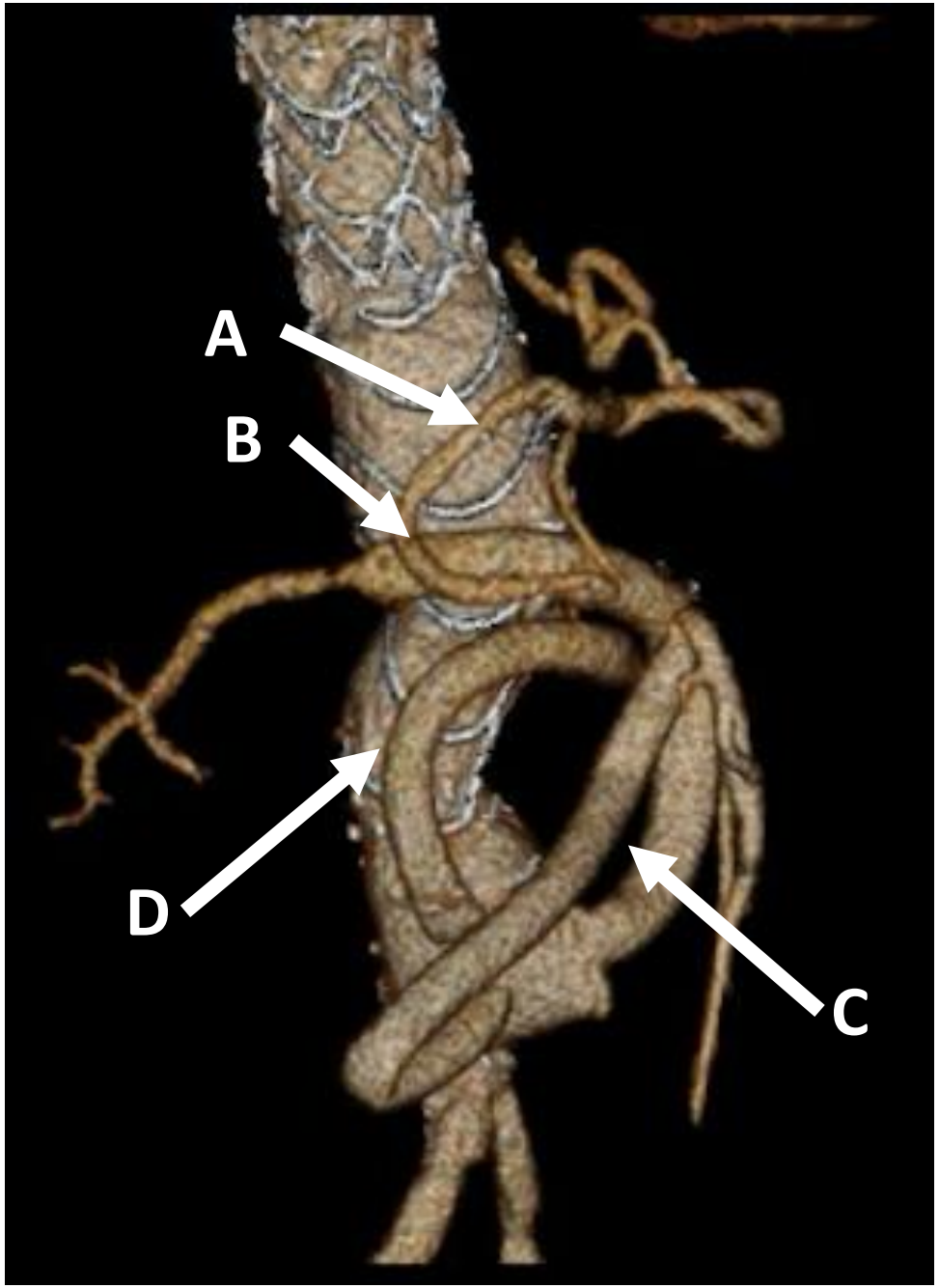

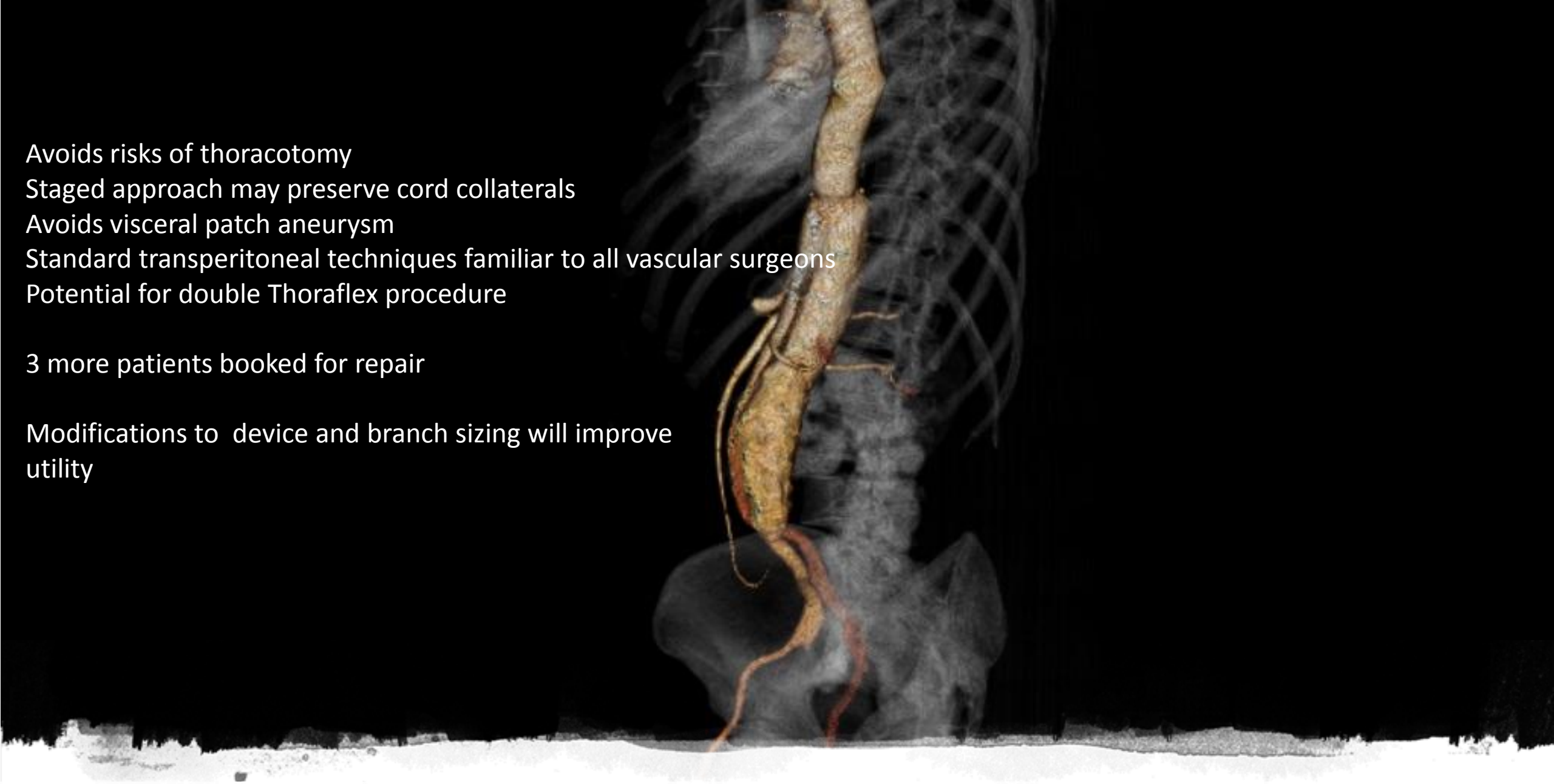

Avoids risks of thoracotomy
Staged approach may preserve cord collaterals
Avoids visceral patch aneurysm
Standard transperitoneal techniques familiar to all vascular surgeons
Potential for double Thoraflex procedure

3 more patients booked for repair

Modifications to device and branch sizing will improve utility