Lumbar Drain Management

Thoracic Aortic Aneurysm Surgery

Presented
By
Tonya L. Page MSN, APRN, ACNP-BC

What is a Lumbar drain?

A small, flexible, soft plastic tube placed in the lower back (lumbar area) to remove cerebrospinal fluid (CSF)

Used to drain some of the cerebrospinal fluid that fills the ventricles of the brain and surrounds the brain and spinal cord.

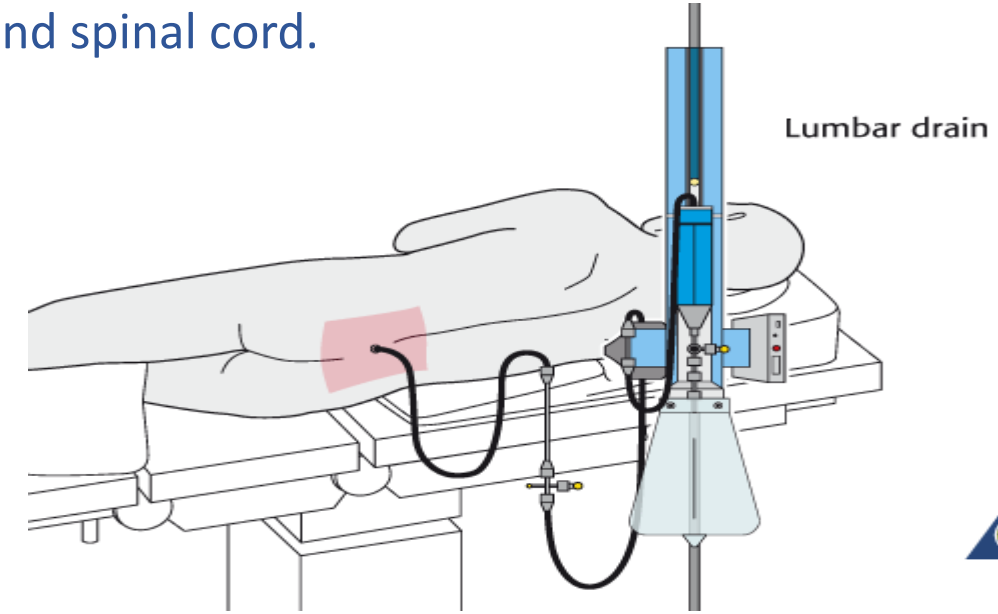

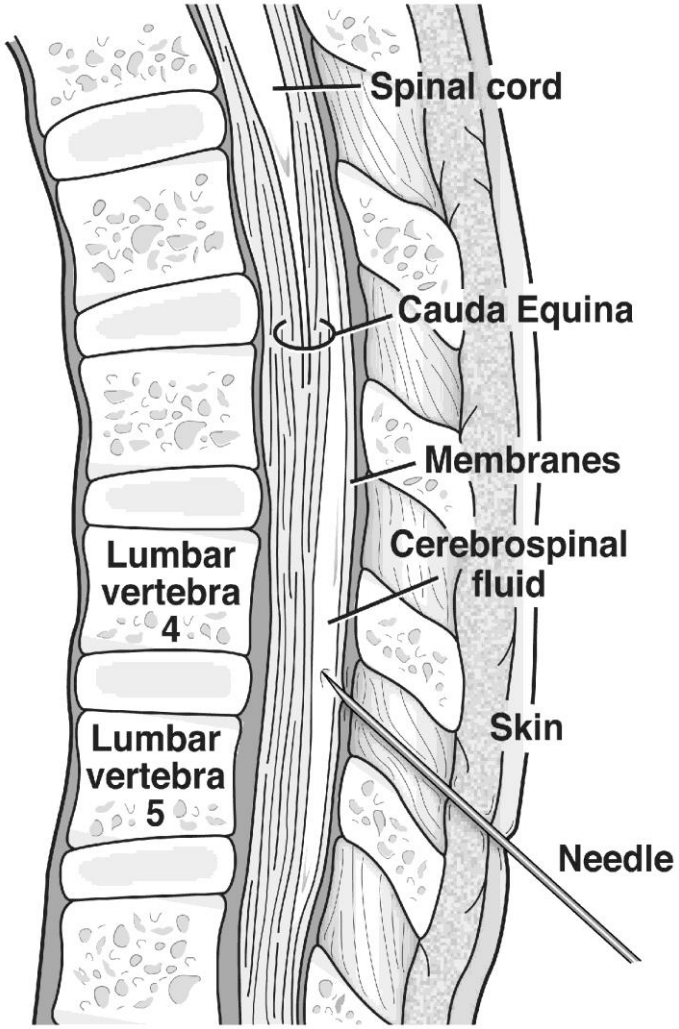

Purpose of the Lumbar drain

Draining cerebrospinal fluid(CSF) can reduce pressure in the spinal cord or brain.

↑ Increased Pressure = ↓ Reduce blood flow

↑ Confusion

↑ Headache/Pain

↑ Weakness/Paresis

↑ Paralysis

Indications in Aortic Aneurysm Surgery

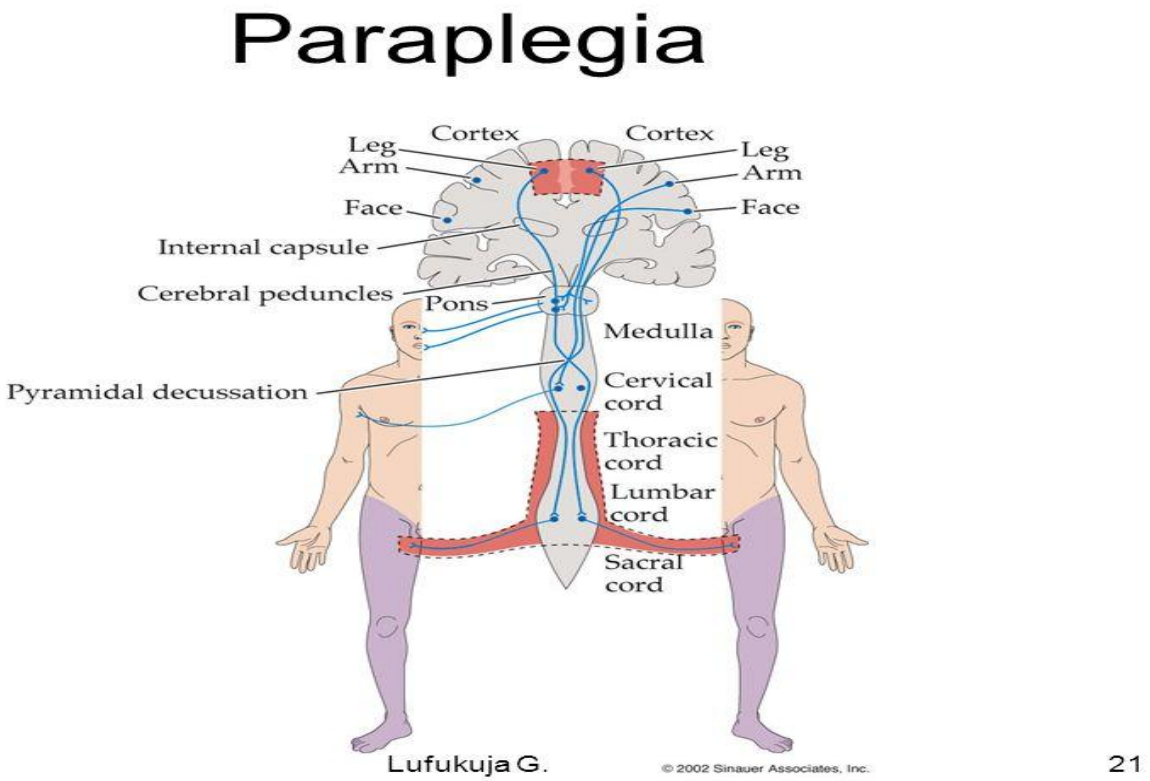

Paraplegia remains one of the most devastating complications of thoracoabdominal aortic surgery and is associated with a significant increase in both morbidity and mortality (Fedorow, et al., 2010).

Indications for cerebrospinal fluid (CSF) drain

Evidence from randomized and nonrandomized trials and from cohort studies support the use of CSF drainage as an adjunct to prevent paraplegia when this adjunct is used in centers with large experience in the management of TAAA.

Lower limb neurologic deficits occurred in 12% of patients who underwent CSF drainage and 33% of control subjects.

Cinà, C. S., Abouzahr, L., Arena, G. O., Laganà, A., Devereaux, P. J., & Farrokhyar, F. (2004). Cerebrospinal fluid drainage to prevent paraplegia during thoracic and thoracoabdominal aortic aneurysm surgery: A systematic review and meta-analysis. *Journal of Vascular Surgery, 40*(1), 36-44. 10.1016/j.jvs.2004.03.017

Why does this happen?

Intraoperative ischemia of the spinal cord is thought to be, in part, related to interruption of blood flow to the arteries that supply blood to the spinal cord during surgery.

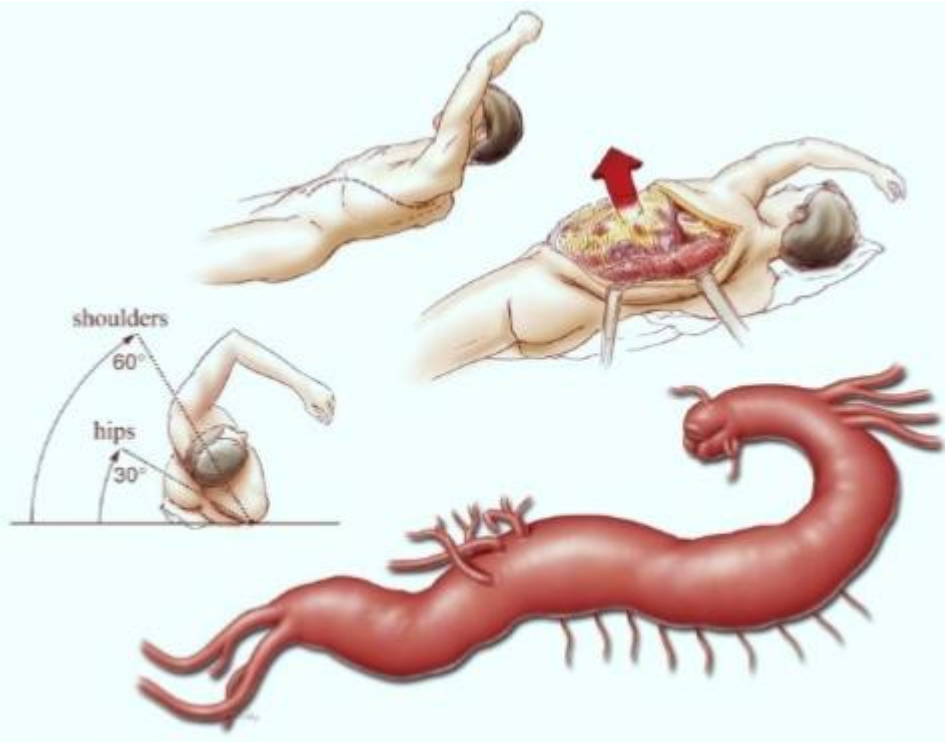

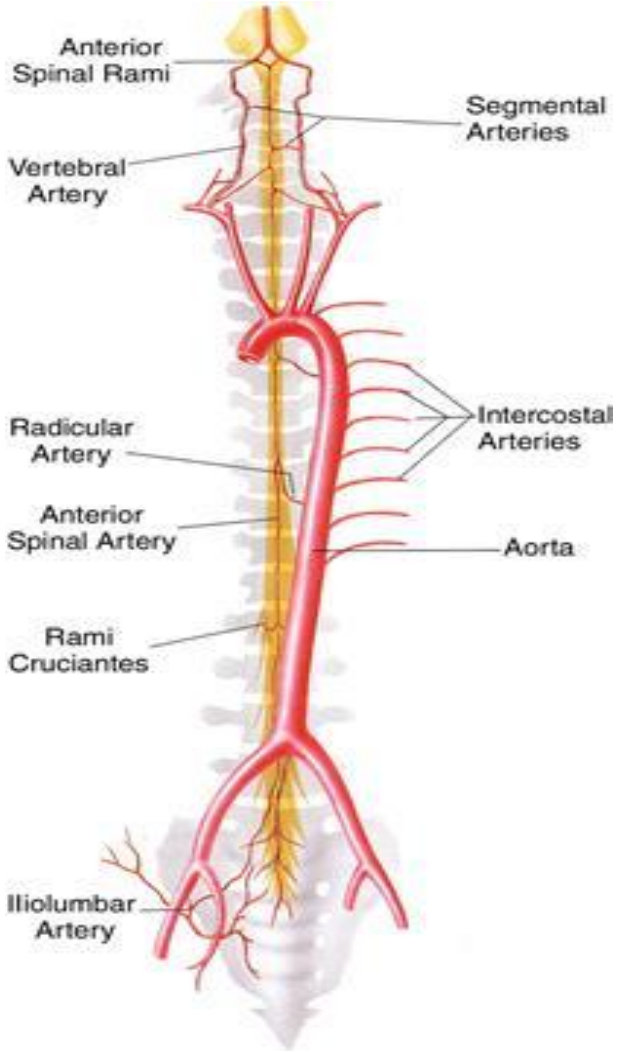

Fedorow, C. A., Moon, M. C., Mutch, W. A. C., & Grocott, H. P. (2010). Lumbar cerebrospinal fluid drainage for thoracoabdominal aortic surgery: Rationale and practical considerations for management. *Anesthesia and Analgesia, 111*(1), 46. 10.1213/ANE.0b013e3181ddddd

Why does this happen?

- Aortic cross clamping reduces the distal mean arterial pressure (MAP) and the spinal cord perfusion pressure (SCPP)
- Clamping reduces the perfusion to the spinal cord and can cause ischemia and edema
- Then end result may be partial or incomplete paresis or complete paraplegia

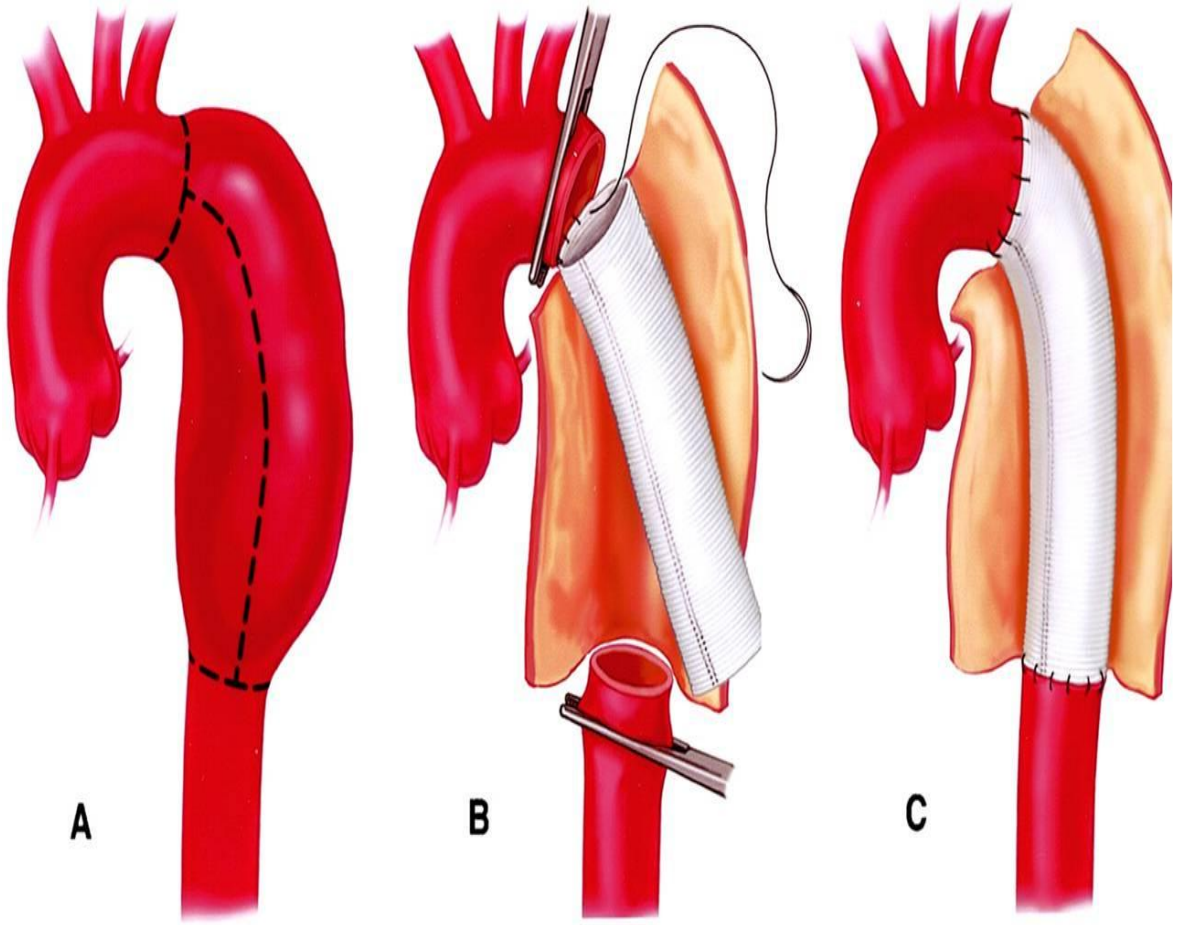

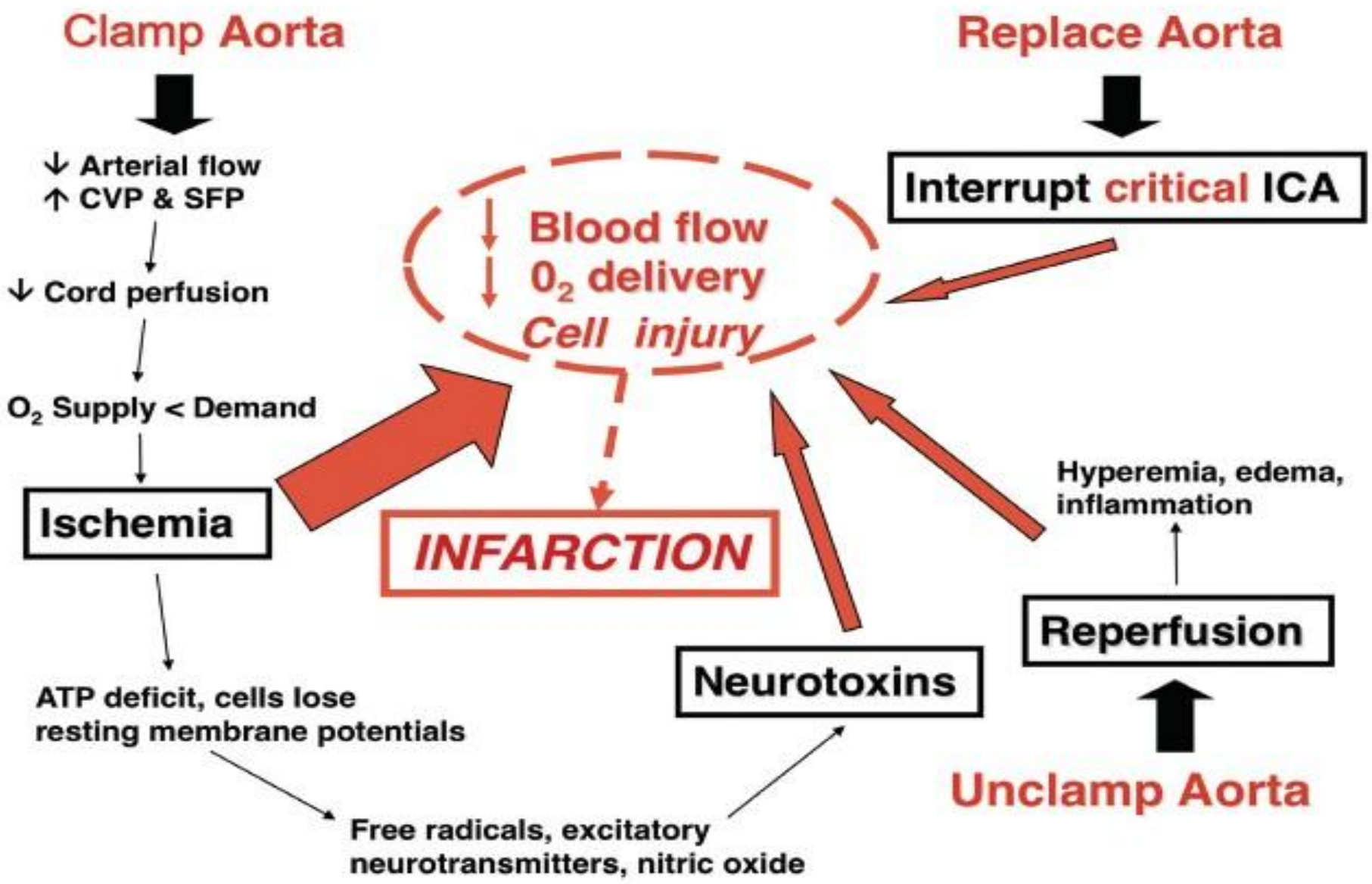
Clamp Aorta
↓ Arterial flow
↑ CVP & SFP
↓ Cord perfusion
O_2 Supply < Demand
Ischemia
ATP deficit, cells lose
resting membrane potentials
Free radicals, excitatory
neurotransmitters, nitric oxide
Blood flow
0_2 delivery
Cell injury
INFARCTION
Neurotoxins
Replace Aorta
Interrupt critical ICA
Hyperemia, edema,
inflammation
Reperfusion
Unclamp Aorta

What increases the risk?

1. Emergency (dissection/rupture)
2. Increased Clamp Time
3. Extensive Aneurysms
4. Post-op Hypotension
5. Increased Age
6. Previous Aneurysm Repair
7. Diabetes (comorbid diseases)

Perioperative Insertion

- Side lying position
- Sterile site prep of the lumbar spine
- Needle insertion at L3-L4 or L4-L5 into intrathecal space
- Cerebrospinal fluid flow confirmed
- Catheter advanced 5-7cm – (often times anesthesia will place stich)
- Occlusive Dressing applied
- Transducer connected and leveled at the right atrium
- CSF drained to <10mmHg

ICU Management Orders

- ❑ **Transduce Cerebrospinal Fluid Pressure (CSFP)** (sometimes called ICP)
  - ❑ Position patient HOB 30°
  - ❑ Level transducer to phlebostatic axis or right atrium
  - ❑ Continuously transduce CSFP
  - ❑ Turn stopcock off toward the cylinder
  - ❑ Read waveform on end expiration
  - ❑ Document the CSF pressure every 1 hour for 3 days
  - ❑ If CSF >10mmHg drain to <10mmHg or no more than 15ml

ICU Management Orders

- ❑Neuro Vital Signs
  - ❑Neuromuscular Checks q1h
  - ❑Neurovascular Checks q1h
  - ❑Notify MD/NP/PA for any changes immediately

- ❑Maintain Lumbar Drain
  - ❑ 72 hours for open repair
  - ❑ 24-48 hours for endovascular repair

ICU Management Orders

- ❑ Monitor for Pink/Bloody CSF.
  - ❑ If CSF Pink/Bloody clamp drain and notify CV surgeon and CV Anesthesia
- ❑ Maintain Hemoglobin >9mg/dl
  - ❑ Notify NP/PA/MD for possible transfusion order.
- ❑ Maintain Cardiac Index $\geq$2.5
- ❑ Maintain SBP $\geq$140 mmHg

Delayed Paraplegia

Evidence does suggest that CSF drainage is an effective rescue maneuver for patients who develop delayed-onset paraplegia.

Predictors of DP include:

1. Increased age
2. Greater extent of TAAA (I,II,III),
3. CSF drain complications,
4. Post operative renal replacement therapy
5. Fluctuations in ***systolic*** arterial blood pressure, but ***not*** *mean* arterial pressure.

Estrera, A. et al., 2016. Fluctuations in Spinal Cord Perfusion Pressure: A Harbinger of Delayed Paraplegia After Thoracoabdominal Aortic Repair, AATS Aortic Symposium, May 13, 2016 power point presentation

Recognizing Neurological Deficits

A new neurologic deficit developing after the patient awakened from the operation with a *normal* examination.

Deficits can be graded as:

0 = no muscular contraction
1 = a barely detectable flicker or trace of contraction
2 = active movement with gravity eliminated
3 = active movement against gravity
4 = active movement against gravity and resistance
5 = normal.

A significant improvement in paraplegia or paraparesis defined as an improvement of at least two motor grades.

Delayed Neurologic Deficit Management

C SF Drain Status

Malfunction → Replace Drain

Normal →

1. Patient Flat
2. Drain pressure <5mmHg
3. Drain for 7 days

O xygen Delivery

Low? →

1. O_2 sat
2. Hgb: >10 mg/dl
3. CI: >2.5 L/min/BSA

P atient S s

Assess →

1. Mean BP: >90 mmHg
2. SCPP: >80 mmHg (MAP-CSFP)
3. Cognitive Status: Bloody CFS?

Estrera, A. et al., 2016. Fluctuations in Spinal Cord Perfusion Pressure: A Harbinger of Delayed Paraplegia After Thoracoabdominal Aortic Repair, AATS Aortic Symposium, May 13, 2016 power point presentation

Lumbar Drain Removal & Monitoring

- ✓MD/NP/PA to remove drain in sterile fashion
- ✓Site inspected and covered with 2x2 and clear occlusive dressing
- ✓Patient to lay flat with spine aligned for 2-4 hours
- ✓Monitor for headache due to continued CSF leak
- ✓Notify CV anesthesia if symptoms do not resolve

References

Estrera, A. et al., 2016. Fluctuations in Spinal Cord Perfusion Pressure: A Harbinger of Delayed Paraplegia After Thoracoabdominal Aortic Repair, AATS Aortic Symposium, May 13, 2016 power point presentation.

Fedorow, C. A., Moon, M. C., Mutch, W. A. C., & Grocott, H. P. (2010). Lumbar cerebrospinal fluid drainage for thoracoabdominal aortic surgery: Rationale and practical considerations for management. *Anesthesia and Analgesia, 111*(1), 46. 10.1213/ANE.0b013e3181ddddd