Wound Care is Not Always About Arterial Disease: Venous Obstructive Disease Perspective

PATRICIA E. THORPE, MD, FSIR

OCT 6, 2017

Cardiovascular Disease Management

DISCLOSURES

- CONSULTANT
  - BARD, BOS SCI, VOLCANO
- INARI
  - CONSULTANT
- INTERVENE
  - CONSULTANT
- VIDEO, VIRTUS
  - CLINICAL TRIAL PARTICIPANT, CONSULTANT

- **Case Report:** A 60 year old gentleman comes to see you with bilateral leg edema. Ten years ago he suffered a DVT on his left leg. Now he has occasional left lower leg achiness. He has severe venous reflux and some discoloration in his lower extremities, left worse than right. How would you manage this patient?
-

STOCKINGS?
ABLATIONS?
STENTS?
ALL THE ABOVE

VENOUS PATHOLOGY

VEINS HAVE 2 BASIC COMPONENTS

1.) A TUBULAR PART WITH FEEDING TRIBUTARIES

2.) VALVES

VENOUS PATHOLOGY

- **WHAT CAN GO WRONG?**
- OBSTRUCTION/CLOT
- VALVE DAMAGE/REFLUX
- PHLEBOLYMPHEDEMA

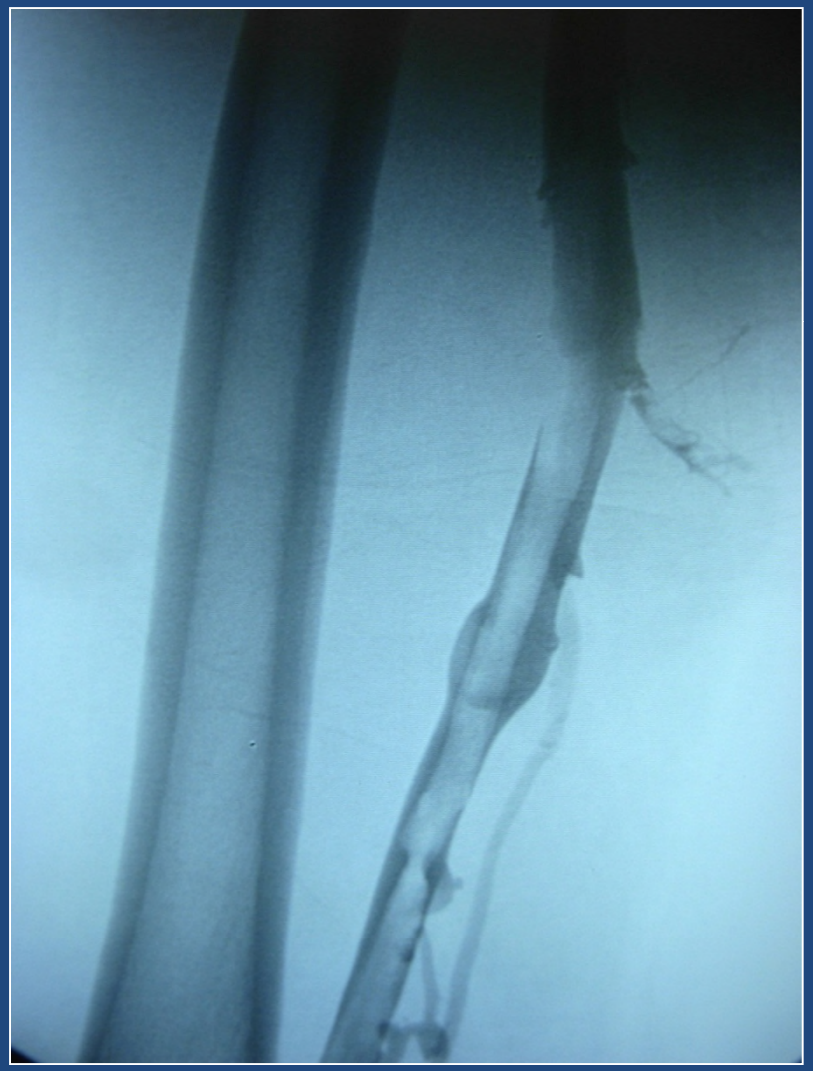

DATE:	4-27-15 9AM
INDICATIONS:	SWELLING
HISTORY:	

(2)

TECHNOLOGIST FINDINGS: 2 EXAMS

IVC + Bil. Iliacs. – There appears to be a narrowing in the left MID CIV, consistent with May Thurner. The distal IVC and both proximal iliacs appear narrowed? Both. EIVs Augment.

2) Left LE Venous Duplex – Chronic DVT in one of Enlarged Lymph node the left peroneals with total obstruction. The left CFV through the popliteal are patent & phasic – there is a duplicated femoral. There is deep reflux noted in the left PTVs, ATVs, & peroneals. The left GSV is patent with no significant reflux.

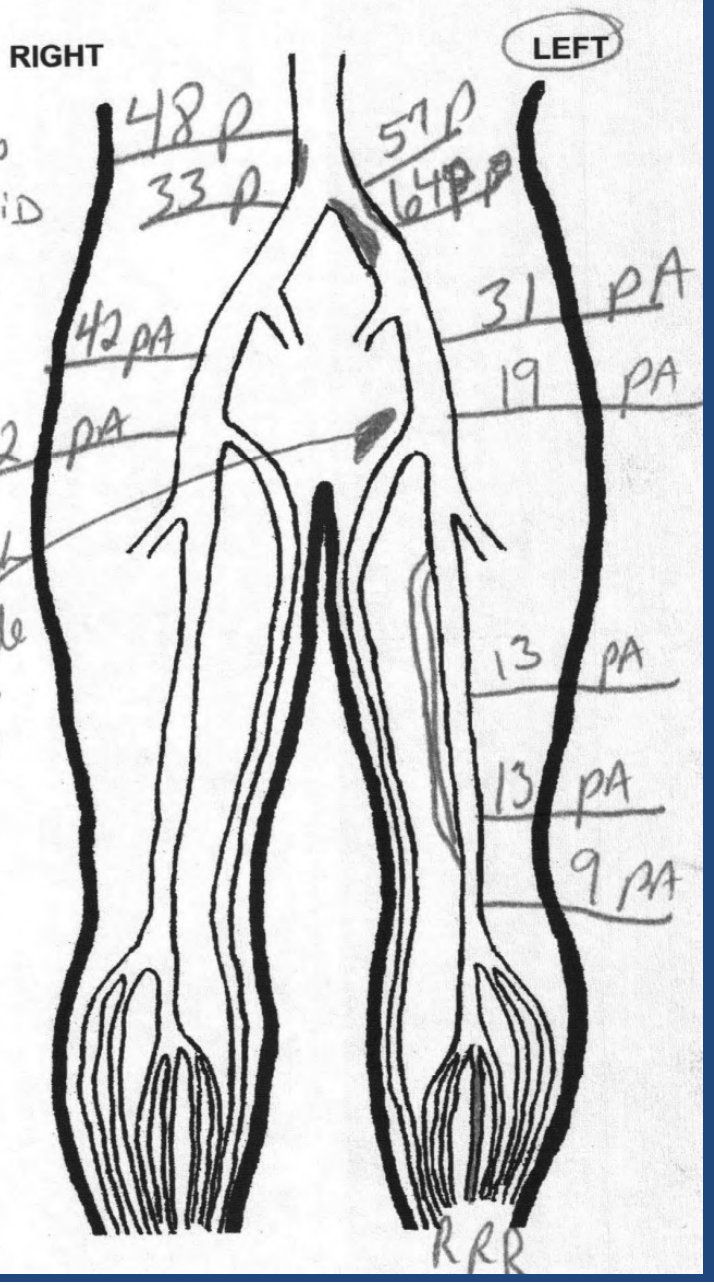

Chronic Leg Edema

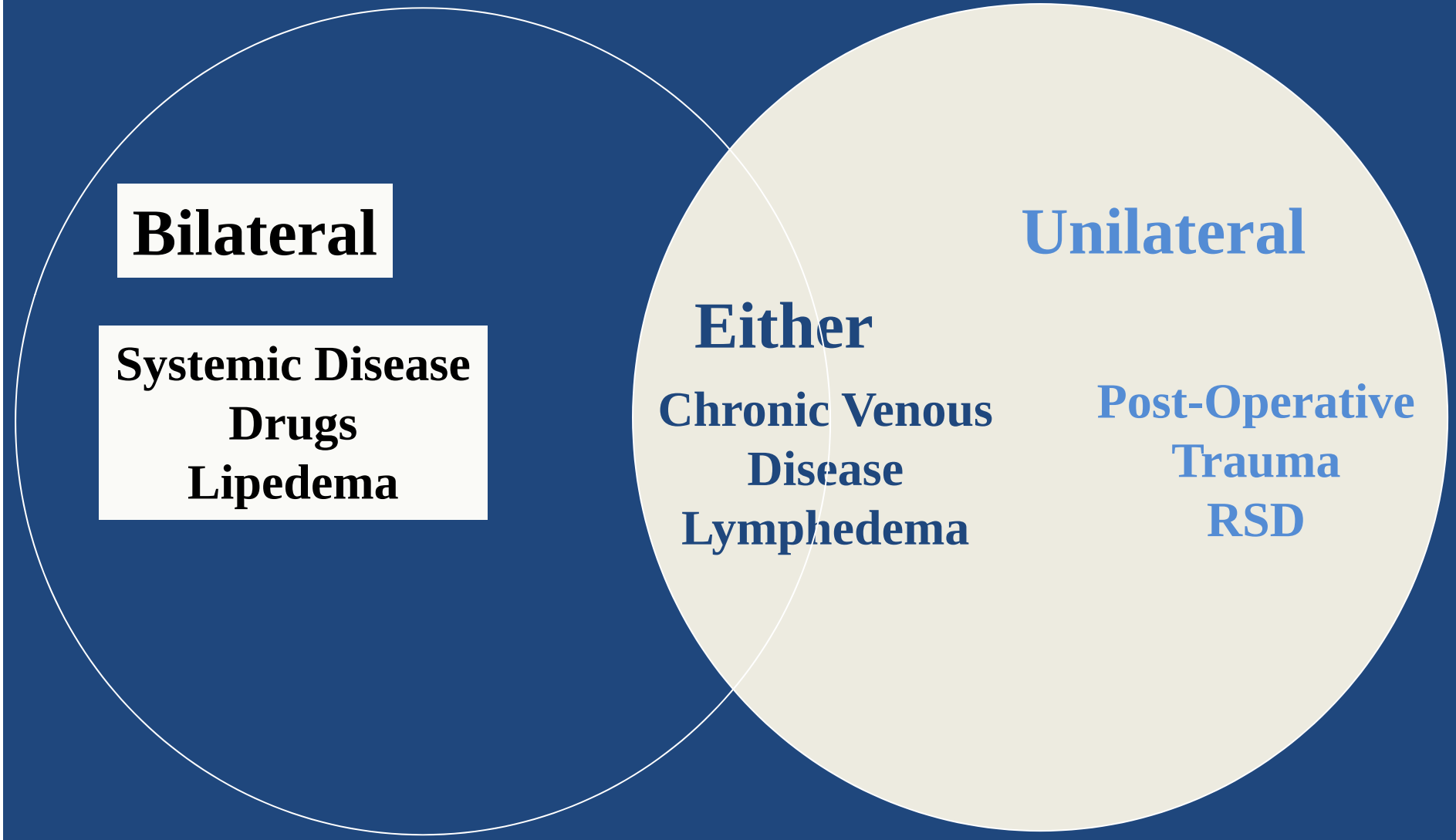

- History
  - Duration
  - Medications
  - Hx of systemic disease
  - Hx of neoplasm
- Physical Examination
  - BMI
  - Distribution of edema
  - Pedal involvement
  - Skin changes
    - Hyperkeratosis,
    - Papillomatosis
    - Lipodermatosclerosis
- Diagnostic tests
  - Laboratory tests
  - Venous duplex U/S
  - Lymphoscintigraphy
  - CT abdomen & pelvis
  - MRI

- History
  - Duration
  - Medications
  - Hx of systemic disease
  - Hx of neoplasm
- Physical Examination
  - BMI
  - Distribution of edema
  - Pedal involvement
  - Skin changes
    - Hyperkeratosis,
    - Papillomatosis
    - Lipodermatosclerosis
- Diagnostic tests
  - Laboratory tests
  - Venous duplex U/S
  - Lymphoscintigraphy
  - CT abdomen & pelvis
  - MRI

Bilateral Edema

Step 1 – Exclude Drugs

- Anti-Hypertensives
  - *Calcium channel blockers*
  - Beta Blockers
  - Hydralazine
  - Minoxidil
  - Methyldopa
- Hormones
  - Corticosteroids
  - Estrogen
  - Progesterone
  - Testosterone
- Other
  - Non-steroidal anti-inflammatories
  - Pioglitazone, Rosiglitazone
  - MAO inhibitors

Systemic Causes

- Cardiac failure
- Renal failure
- Hepatic failure or hypoalbuminemia
- Protein-losing nephropathy
- Pulmonary Hypertension
- Sleep apnea
- Drugs

Local Causes

- Deep Vein Thrombosis
- IVC & iliac thrombosis
- Valvular reflux CVI
- Lymphedema, Lymphangitis
- Cellulitis
- Lipidemia
- Reflex Sympathetic Dystrophy RSD
- Idiopathic

Unilateral Edema

Clinical Evaluation

	Lymphedema	CVD
Gender	Female > Male	Male or Female
Laterality	2/3 Unilateral	Unilateral or Bilateral
Pedal Sparing	No (+ Stemmer's sign)	Yes
Associated Findings	Hyperkeratosis Papillomatosis Recurrent cellulitis	Varicose Veins Lipodermatosclerosis

Step 2

Diagnostic Tests for Guided by Clinical Evaluation

Clinical Evaluation

Suspect Medical Causes

Suspect Lymphedema

Suspect CVD

Laboratory Tests
Echocardiography
Sleep study

Lymphoscintigraphy

Positive

Negative

Venous U/S

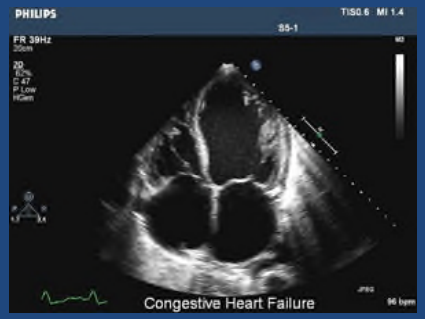

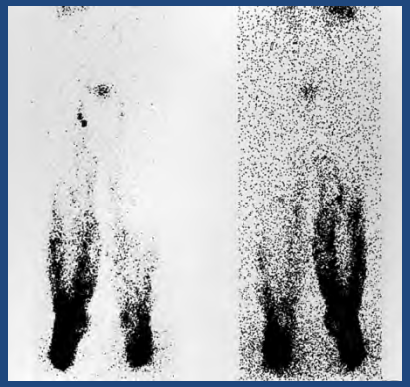

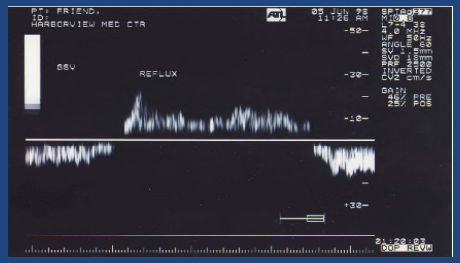

Drugs and Lymphadema

ISLConsensus Guidelines, Lymphology 2009

Drug	Recommendation	Comment
Diuretics	***NO***	
Antimicrobials	Yes	For cellulits/lymphangitis or recurrent limb sepsis
Antihelmintics *(Diethylcarbamazine, albendazole, ivermectin)*	Yes	For filariasis
Hyaluronidase	***No***	
Benzopyrones	***Undefined***	

MULTIPLE ABLATIONS AND NOT GETTING BETTER???

WHAT DO THEY ALL HAVE IN COMMON ?

ILIAC COMPRESSION

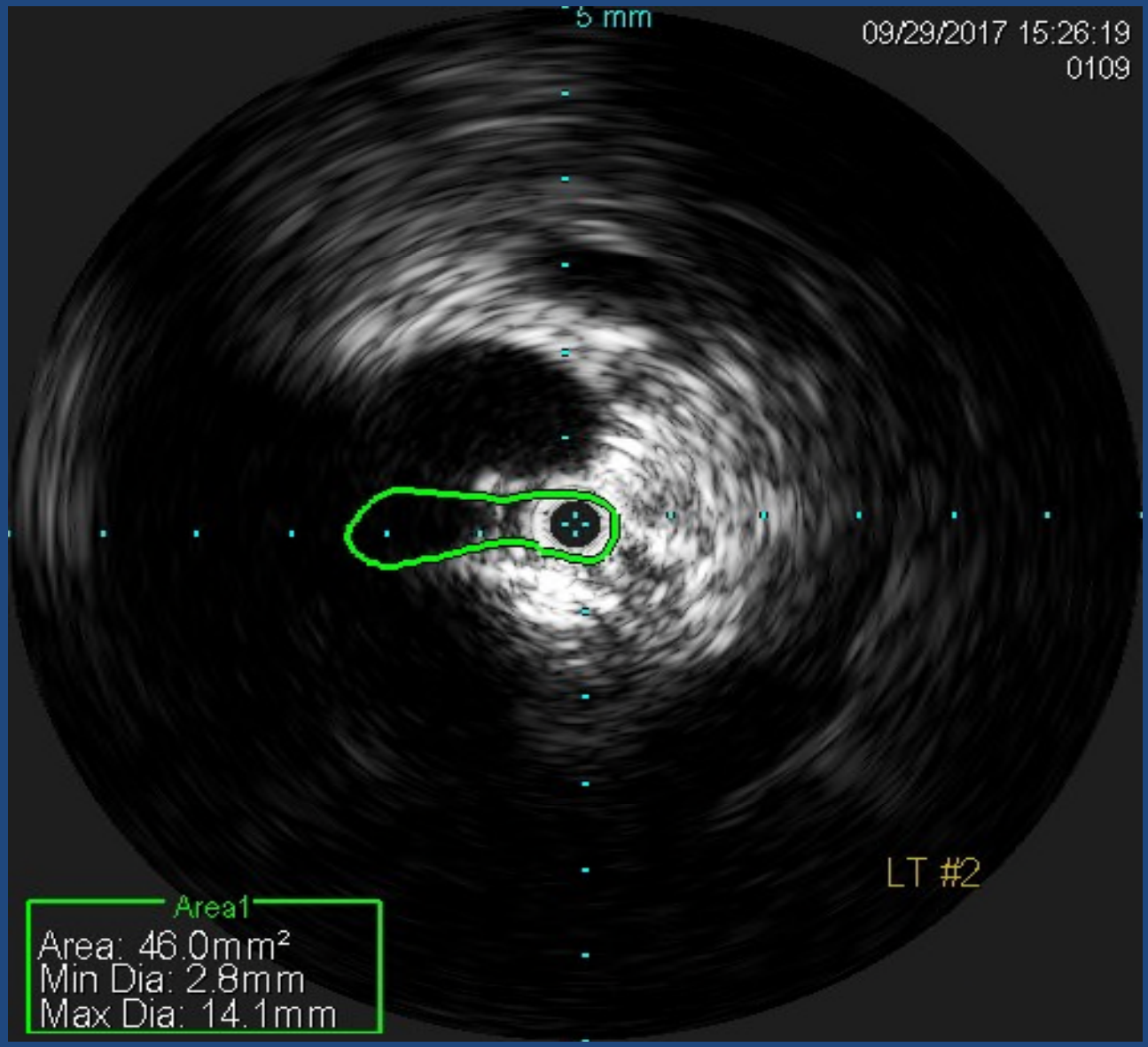
5 mm
09/29/2017 15:26:19
0109
LT #2
Area1
Area: 46.0mm²
Min Dia: 2.8mm
Max Dia: 14.1mm

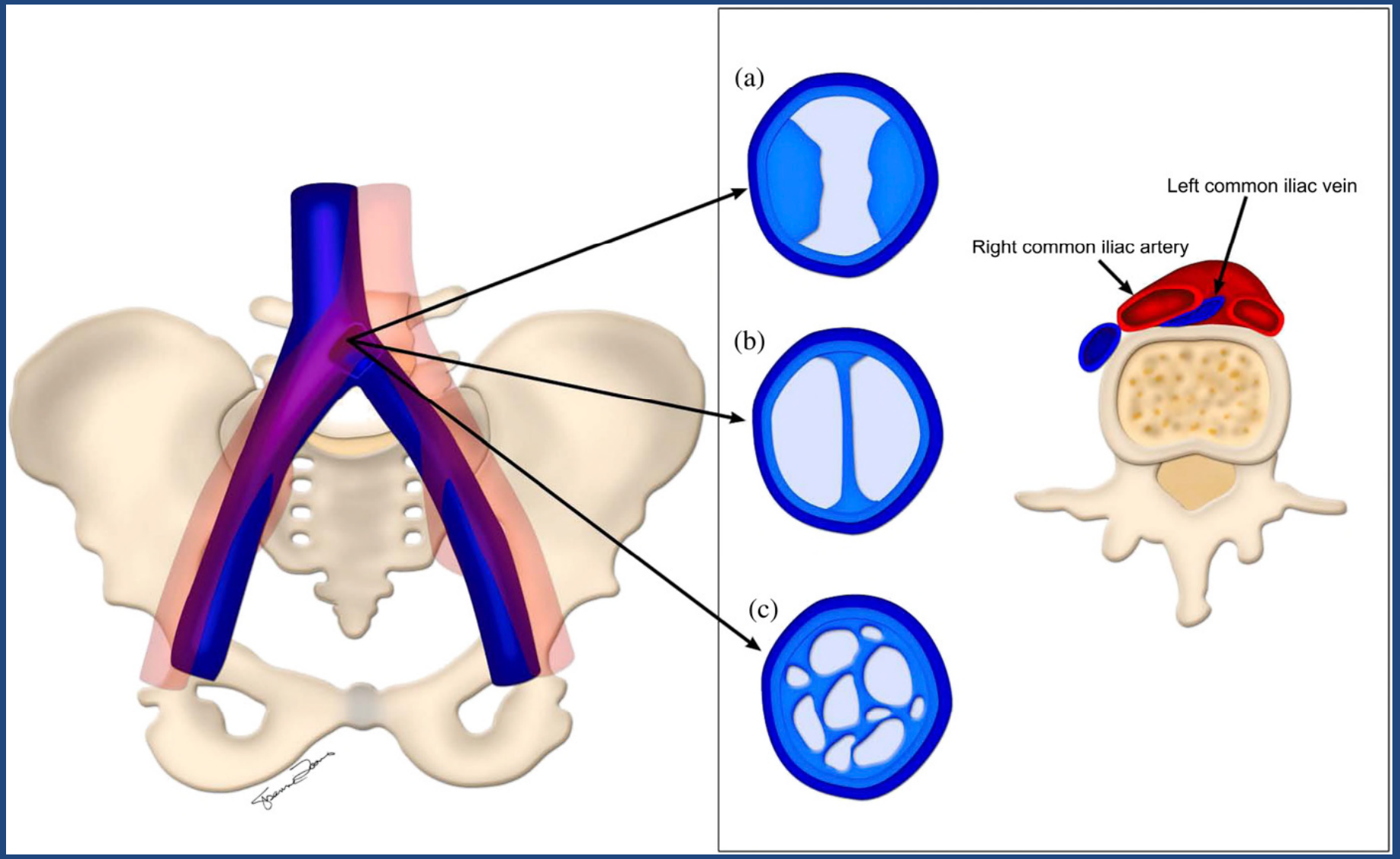

Butros, Br J Radiol, 2013

61 years ago

Z Kreislaufforsch. 1956 Dec;45(23-24):912-22.

A vascular spur in the vena iliaca communis sinistra as a cause of predominantly left-sided thrombosis of the pelvic veins.

[Article in German]

MAY R, THURNER J.

THE SYNDROME

- LEG EDEMA
- VAGUE DISCOMFORT
- ACHE
- HEAVINESS
- TIGHTNESS
- WORSE WITH ACTIVITY
- BETTER IN AM
- GROIN ACHE

2006

High prevalence of non-thrombotic iliac vein lesions in chronic venous disease: a permissive role in pathogenicity.

Raju S, Neglen P.
University of Mississippi Medical Center, River Oaks Hospital, Flowood

J Vasc Surg. **2006** Jul;44(1):136-43

- Nonthrombotic iliac vein lesions (NIVL), such as webs and spurs described by May and Thurner, are commonly found in the asymptomatic general population.

PRONE

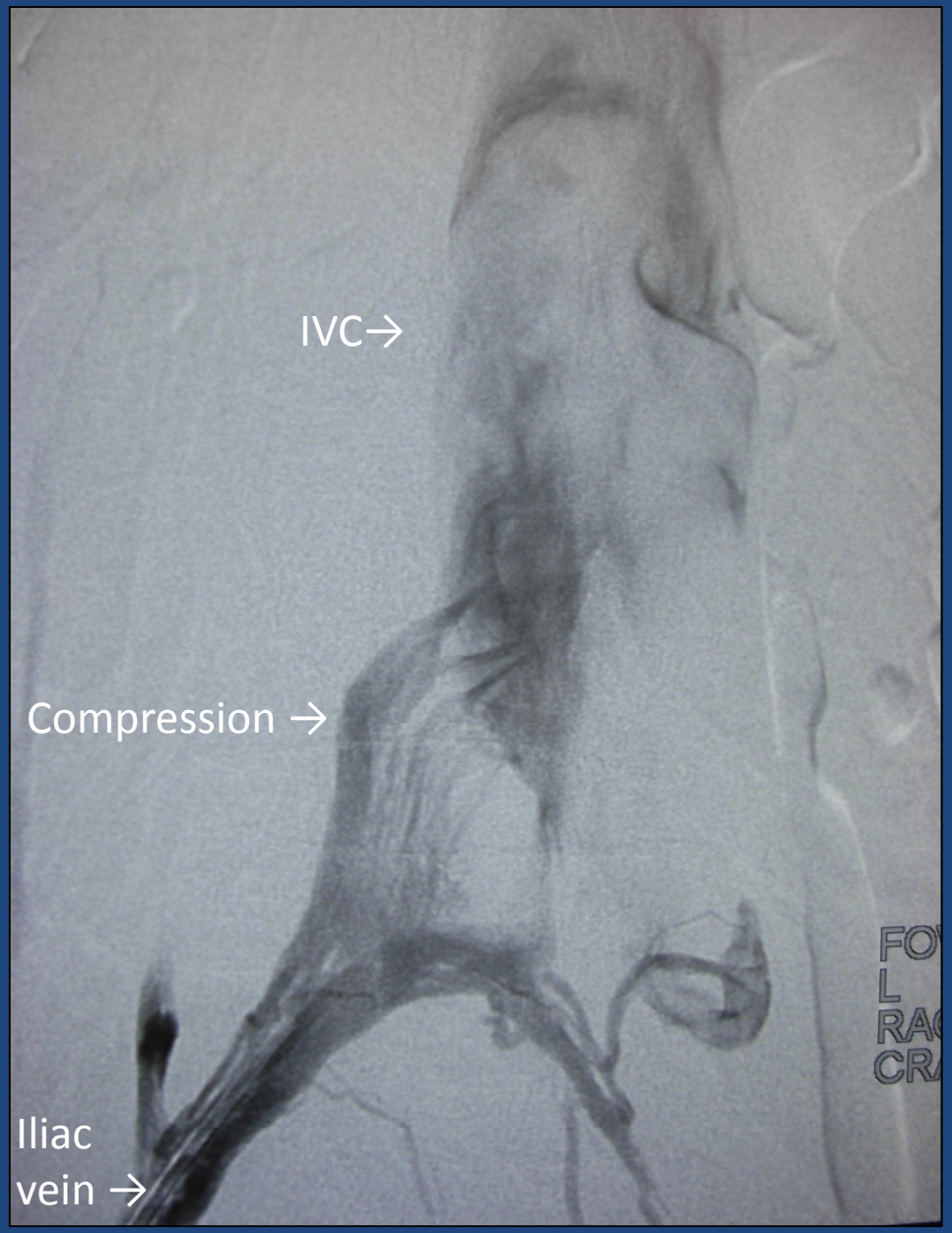

S
L
I
Vitrea®
Zoom:435%
W/L:123/201
Segmented
VR: Base Color

42 YR OLD WOMAN
IOWA CITY

46 yr old man
LIVERPOOL

33 YR OLD WOMAN
NYC

Non thrombotic

34 YR OLD WOMAN
s/p extensive left
leg DVT
SCOTTSDALE

27 YR OLD WOMAN
REDDING

COMPRESSION: NO DVT

- 1/3 POPULATION (100,000,000 PEOPLE)
- 1/3 PEOPLE IN THIS ROOM
- 100,000,000/ 15,000 = 6,666 PATIENTS
- 6666/365= 18.2 YRS (7 D/WK)
- 6666/178 = 37.4 YRS (4 D/WK, 1 MO OFF)

MAY THURNER SYNDROME

- PAIN, DISCOMFORT, ACHE LEFT LEG
- SWELLING LEFT LEG
- INCREASE IN PAIN AND SWELLING WITH ACTIVITY (VENOUS CLAUDICATION)

MTS

- Incidence/Prevalence elusive
  - Autopsy studies report ‘obstructing’ iliac lesions in 22-32% of specimens
  - Retrospective assessment of CT imaging in 50 consecutive ASx patients revealed:
    - 25% incidence of significant stenosis (>50%)
    - 66% incidence of stenosis >25%

Kibbe, JVS, 2004

RISK FACTORS FOR DVT

- DEHYDRATION
- IMMOBILITY
  - CARS, PLANES, TRAINS
  - TRUCKS, COMPUTERS
  - BRACES, CASTS
  - BEDREST
- HORMONES
  - BCP, TESTOSTERONE, STEROIDS

RISK FACTORS DVT

- GENETIC MUTATIONS
- MALIGNANCY
- SURGERY
  - BUNION SX
  - HIP OR KNEE SX
- TRAUMA
  - SPRAIN

BIGGEST RISK FACTOR

- PRIOR IPSILATERAL DVT

GOOD NEWS

OPTIONS: SX OR ENDOVASCULAR

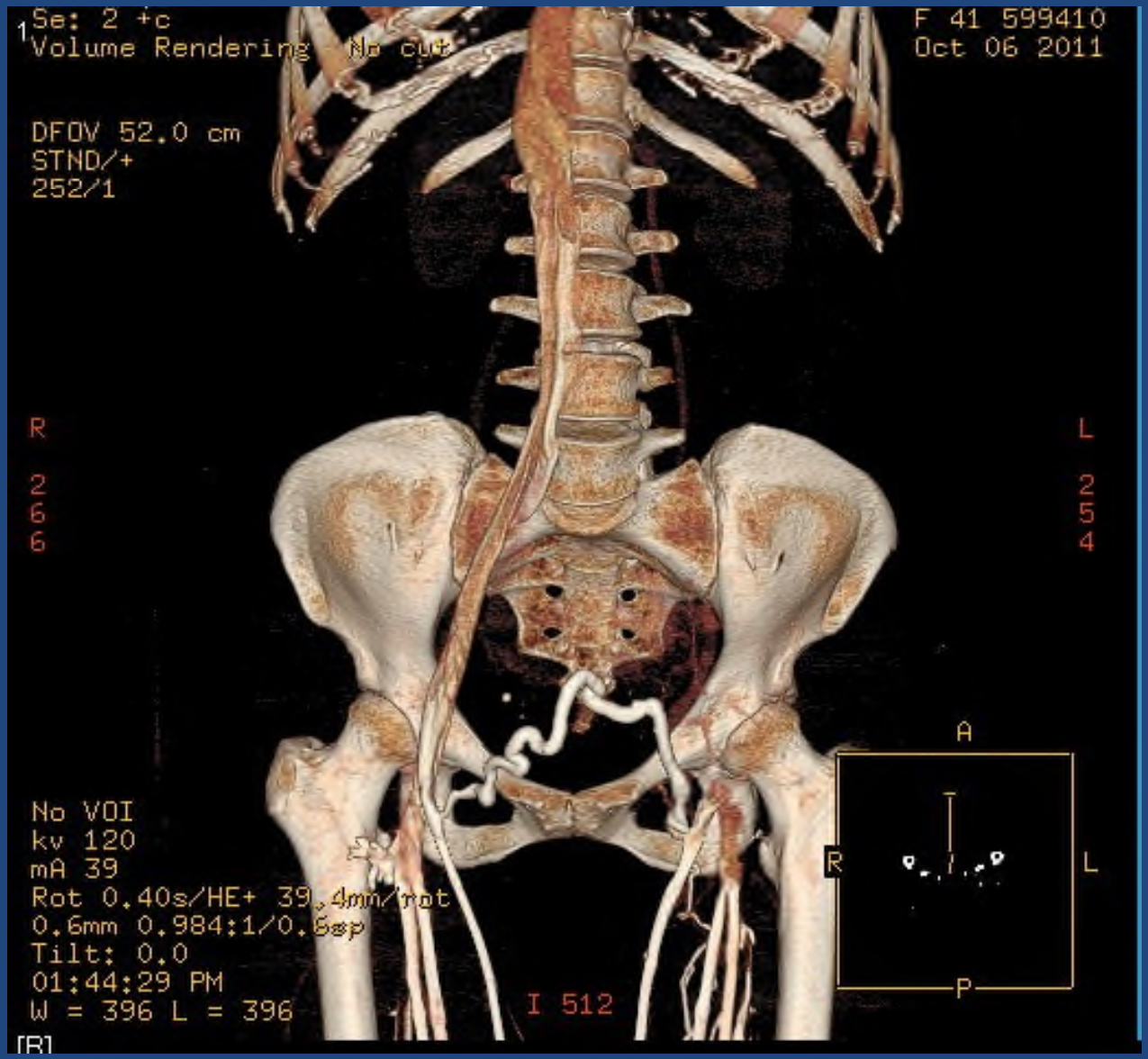

PALMA BYPASS

DATE:	4-27-15 9AM
INDICATIONS:	SWELLING
HISTORY:	

(2)

TECHNOLOGIST FINDINGS: 2 EXAMS

IVC + Bil. Iliacs. – There appears to be a narrowing in the left mid CIV, consistent with May Thurner. The distal IVC and both proximal iliacs appear narrowed? Both. EIVs Augment.

2) Left LE Venous Duplex – Chronic DVT in one of Enlarged lymph node the left peroneals with total obstruction. The left CFV through the popliteal are patent & phasic – there is a duplicated femoral. There is deep reflux noted in the left PTVs, ATVs, & peroneals. The left GSV is patent with no significant reflux.

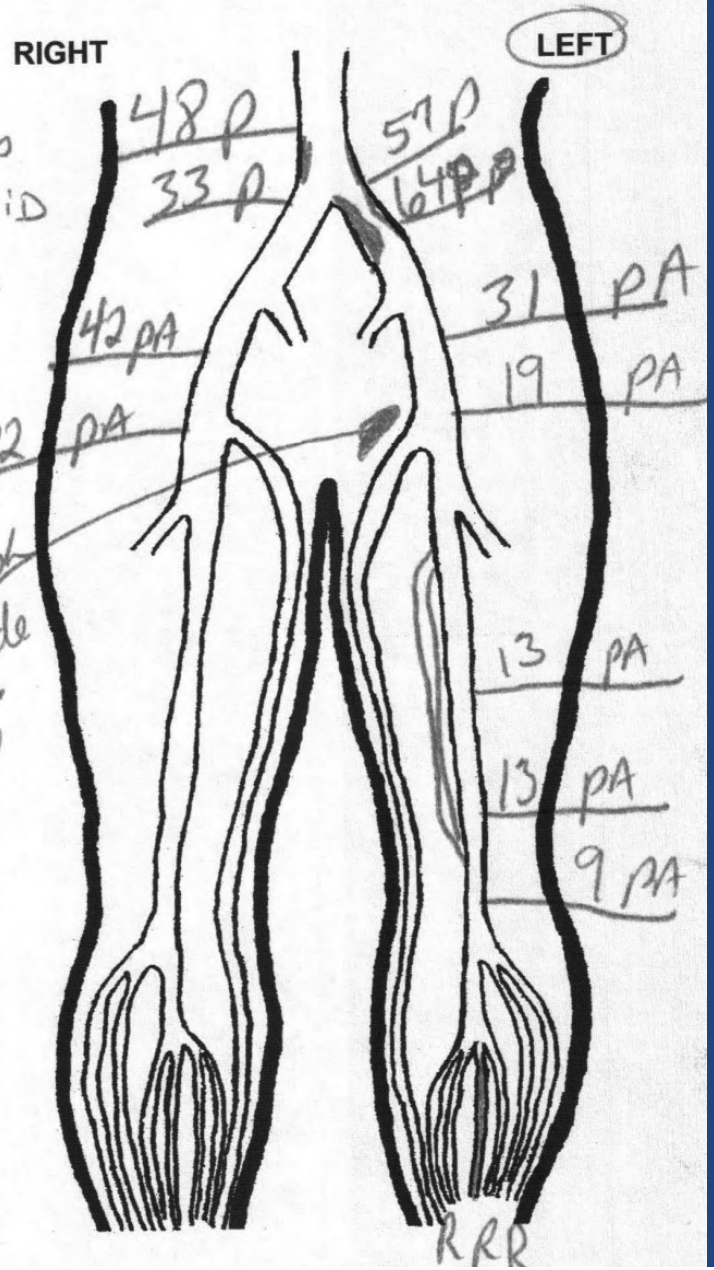

☒ Bilateral	☐ Right Leg	☐ Left Leg
DATE:	1-23-14 2pm	
INDICATIONS:		
HISTORY:		

☐ Technically Difficult Study

TECHNOLOGIST FINDINGS: 2 EXAMS.

I.F 10 mg/d –
12½ 3 X wk –

IVC & Bil. Iliacs: DVT in IVC mid & distal, multiple collaterals, Left CIV occluded Right CIV is narrowed with poss. collateral versus duplicated IVC to ? Right renal?

2) Bil. Venous: String sign in right CFV with good flow in right leg. duplicated femoral & large profunda. ael calf veins are patent on right & ~~left~~ Left leg ~~multiple~~ multiple collaterals at groin. DVT in left femoral with a patent duplicate femoral. DVT extends through popliteal & PTVs & peroneals. ATV are patent. Reflux in (L) pop., ptv

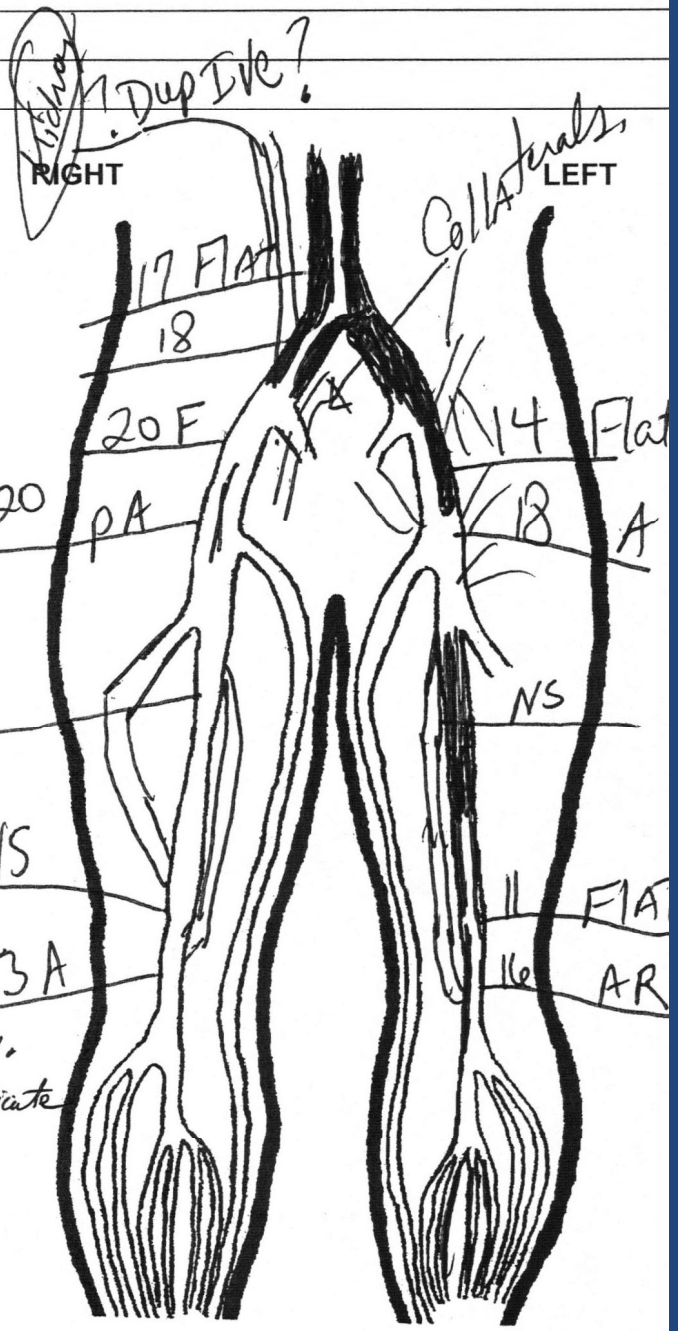

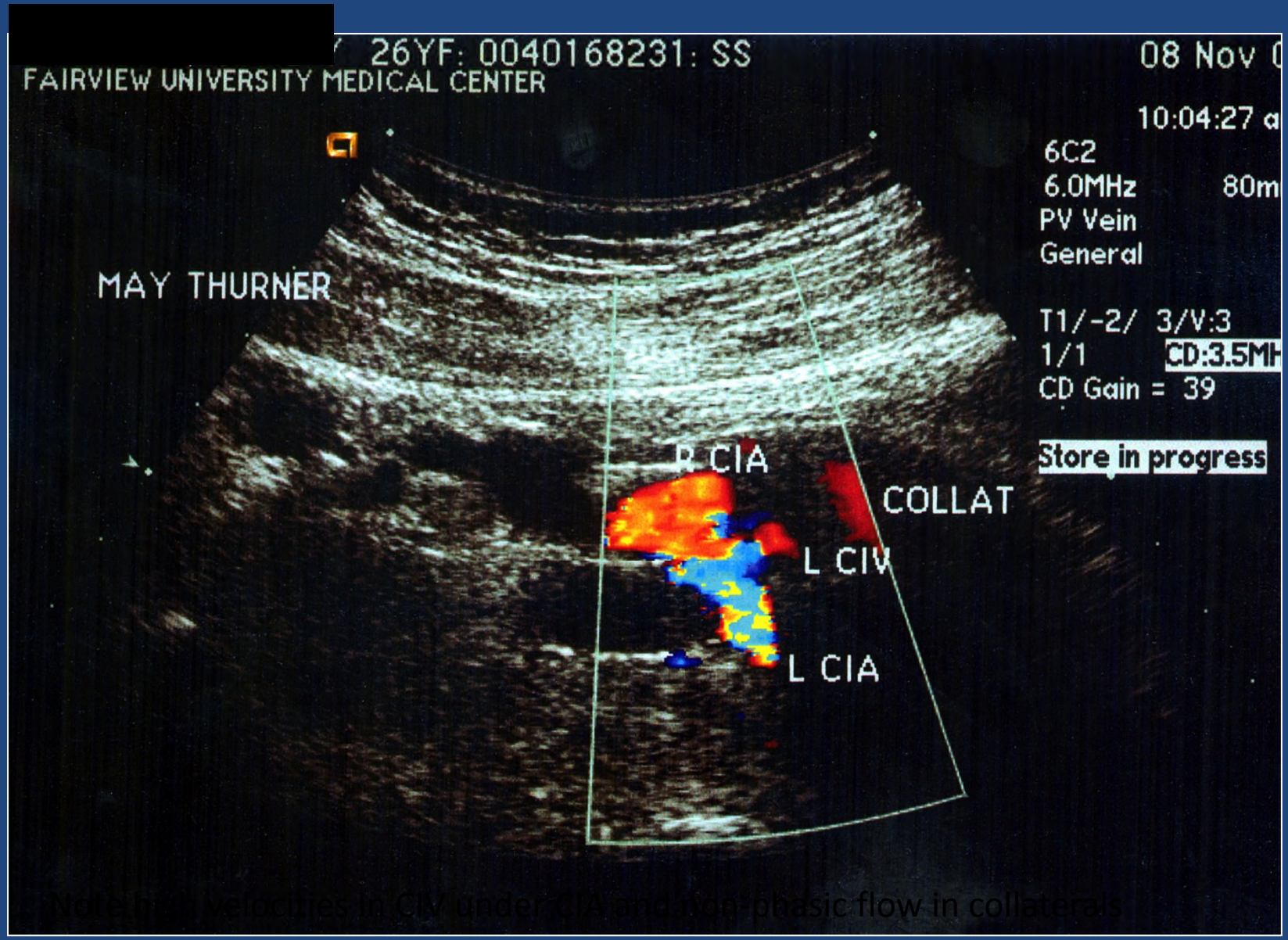

Note high velocities in CIV under CIA and non-phasic flow in collaterals

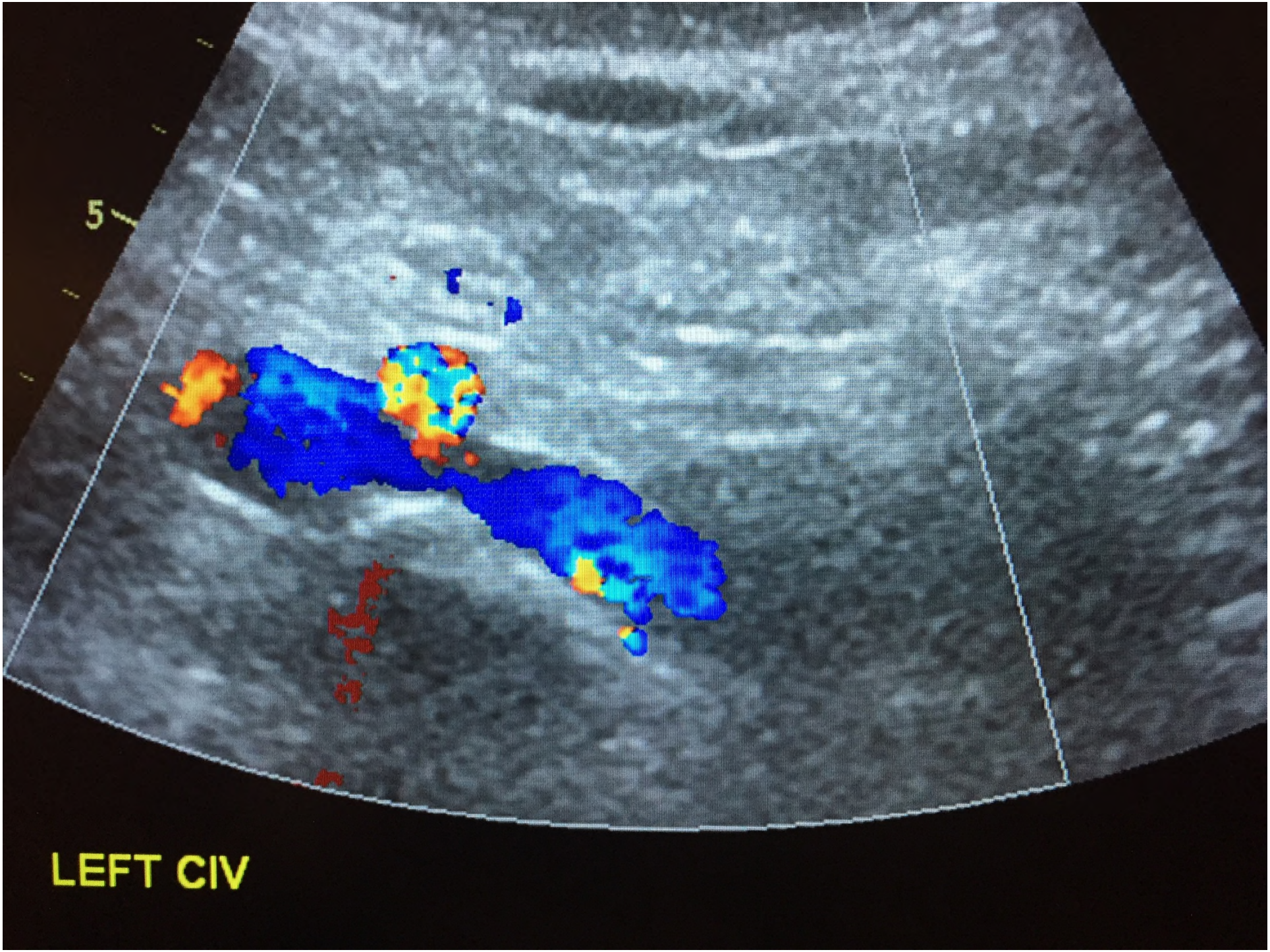
5
LEFT CIV

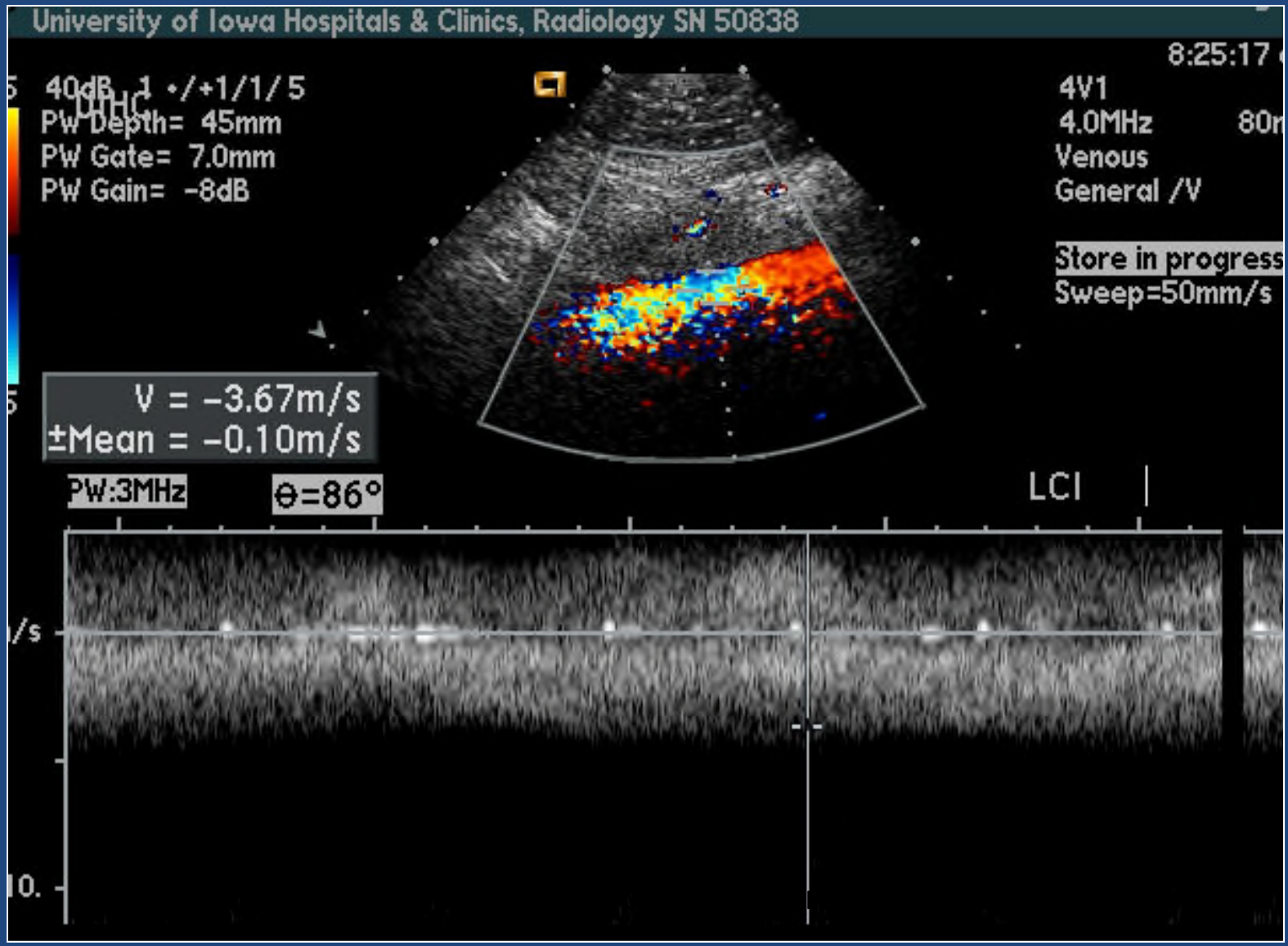
University of Iowa Hospitals & Clinics, Radiology SN 50838
8:25:17
40dB 1 */+1/1/5
PW Depth= 45mm
PW Gate= 7.0mm
PW Gain= -8dB
4V1
4.0MHz
Venous
General /V
Store in progress
Sweep=50mm/s
V = -3.67m/s
±Mean = -0.10m/s
PW:3MHz
θ=86°
LCI

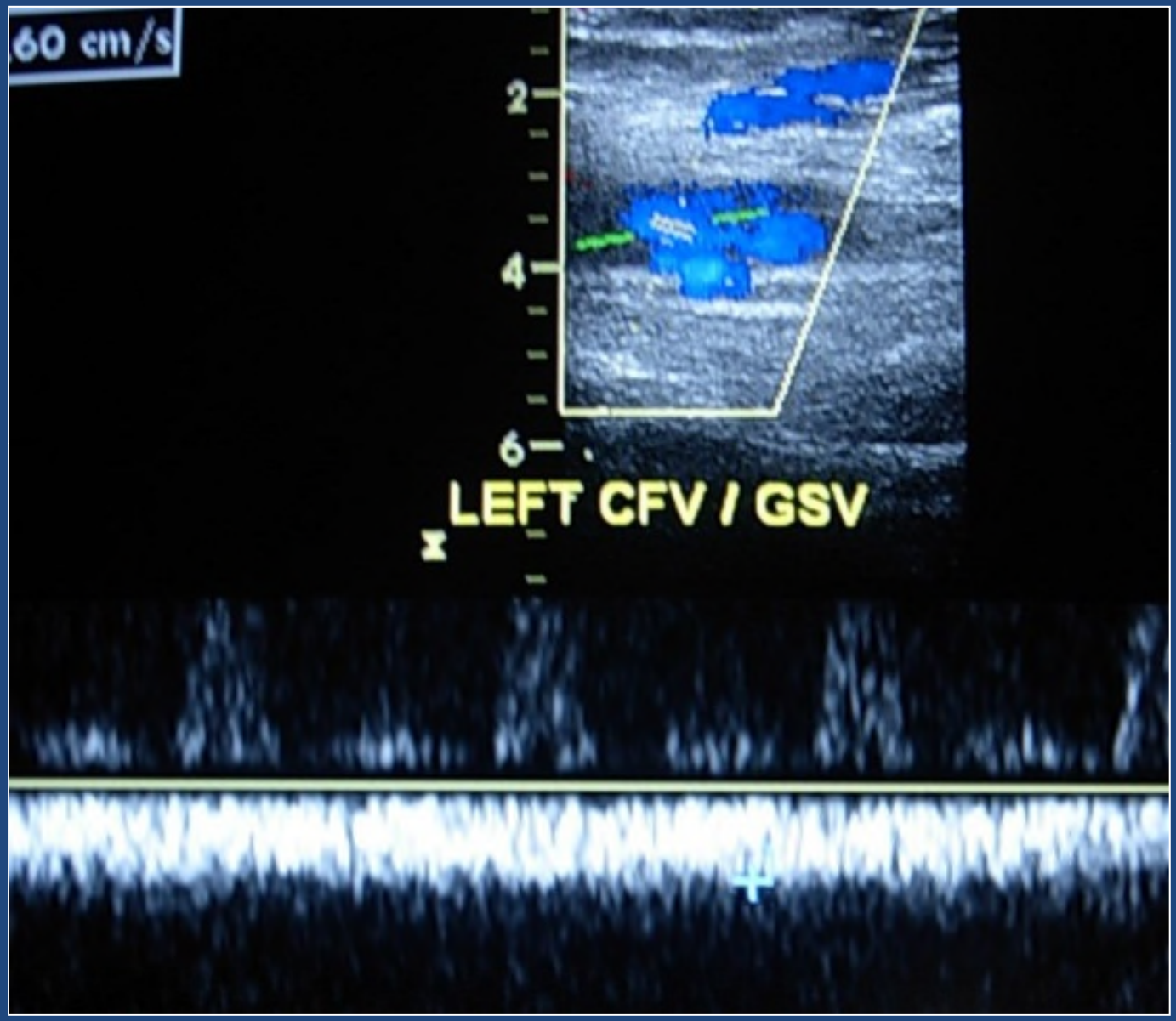
60 cm/s
2
4
6
LEFT CFV / GSV

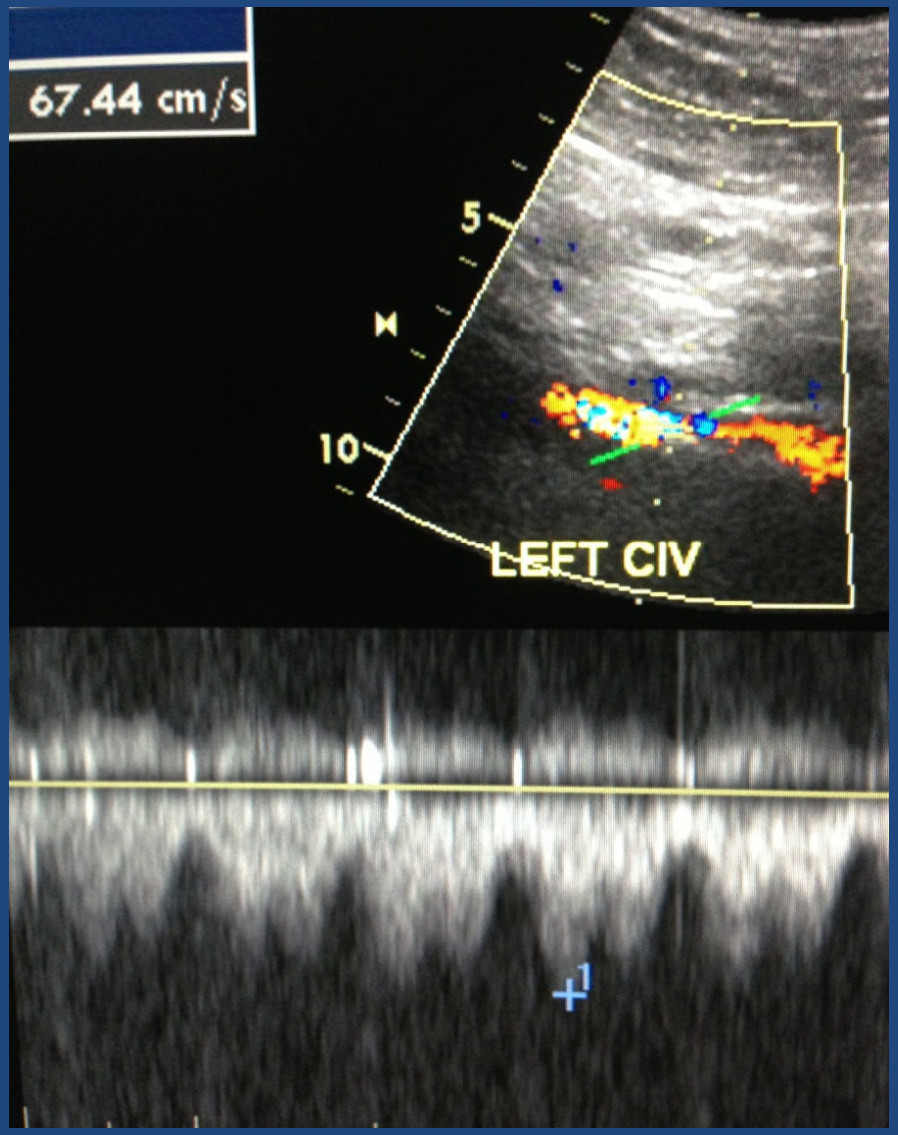

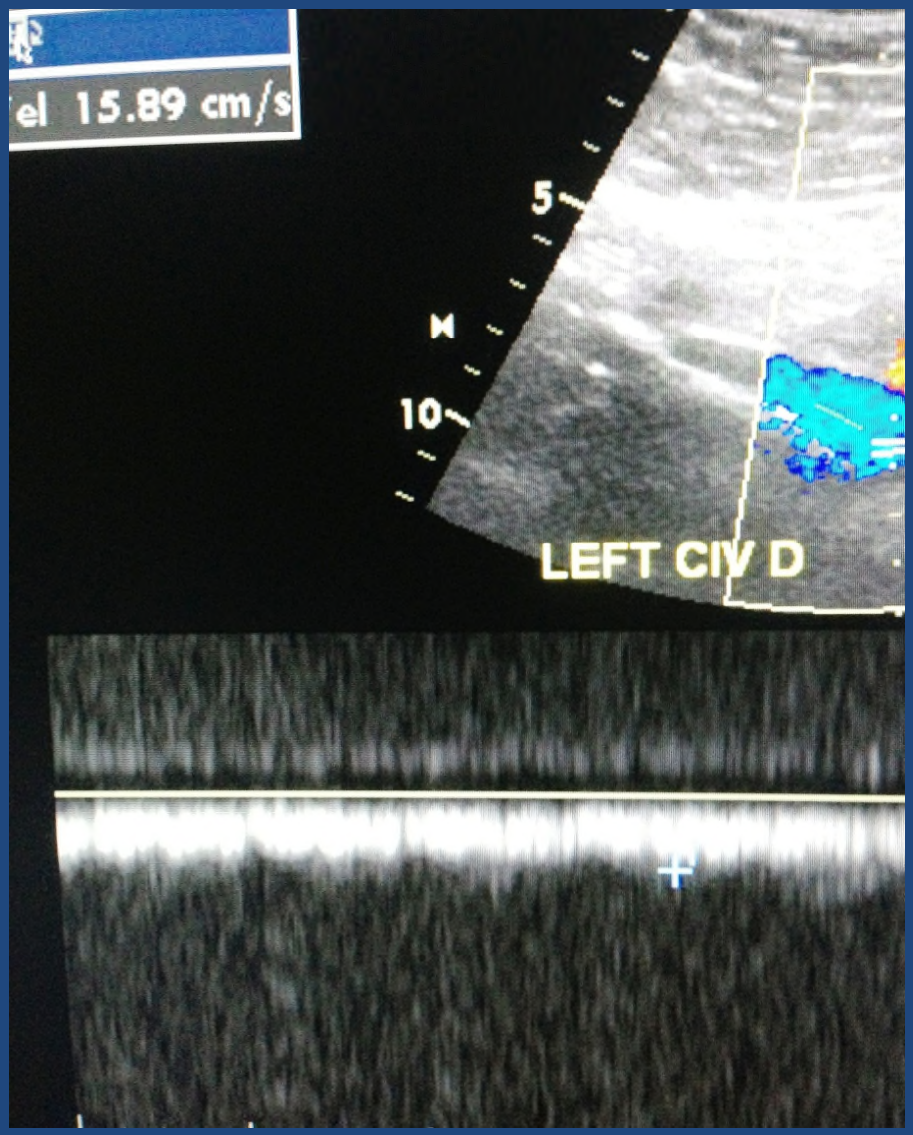

KEY FINDING

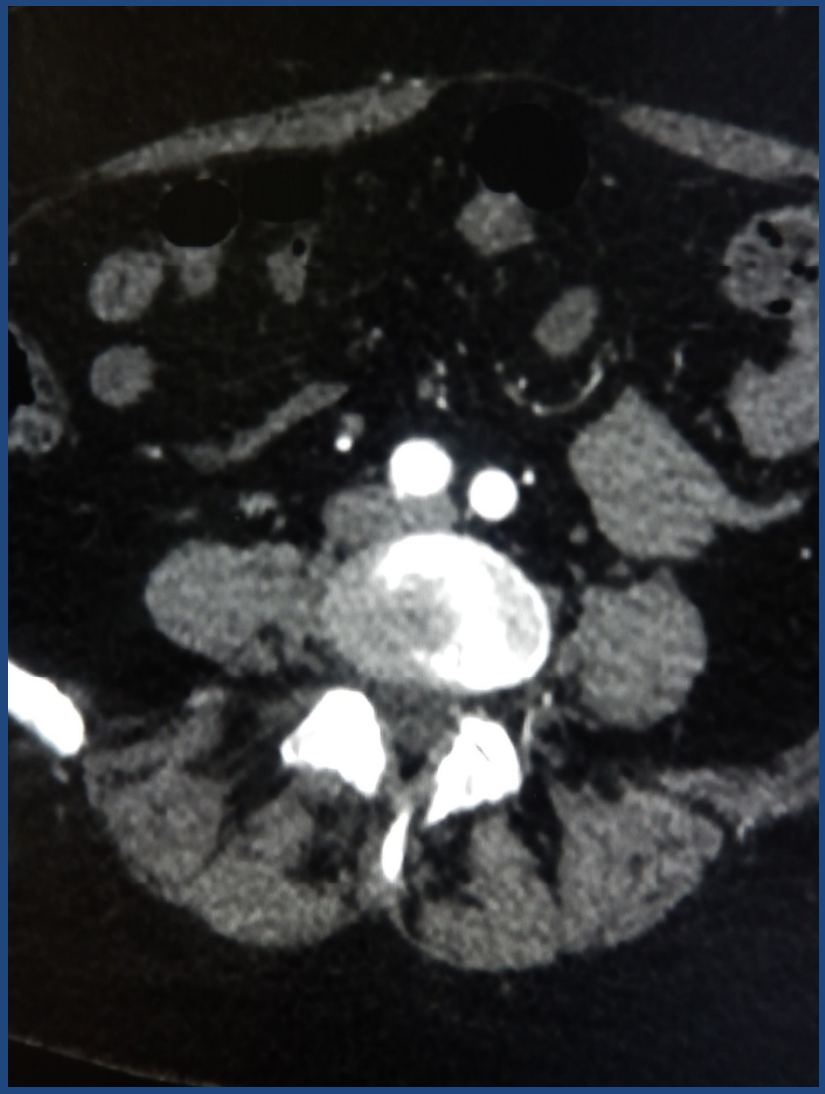

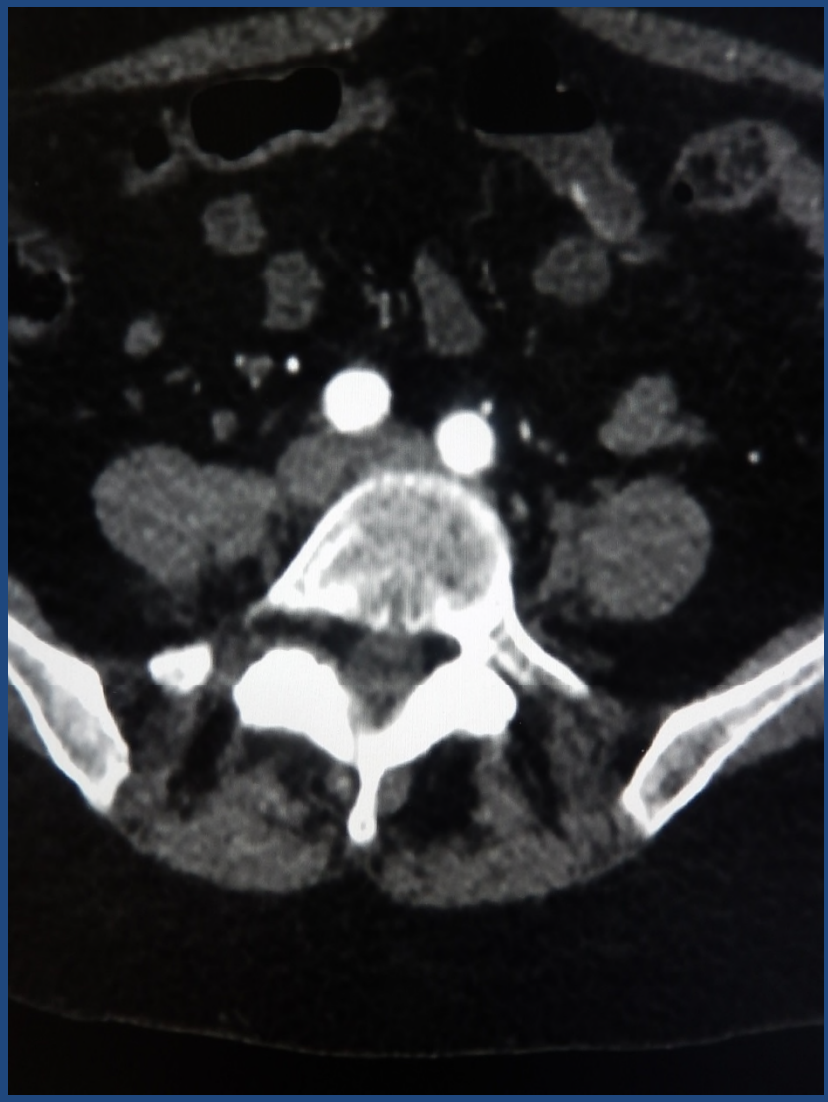

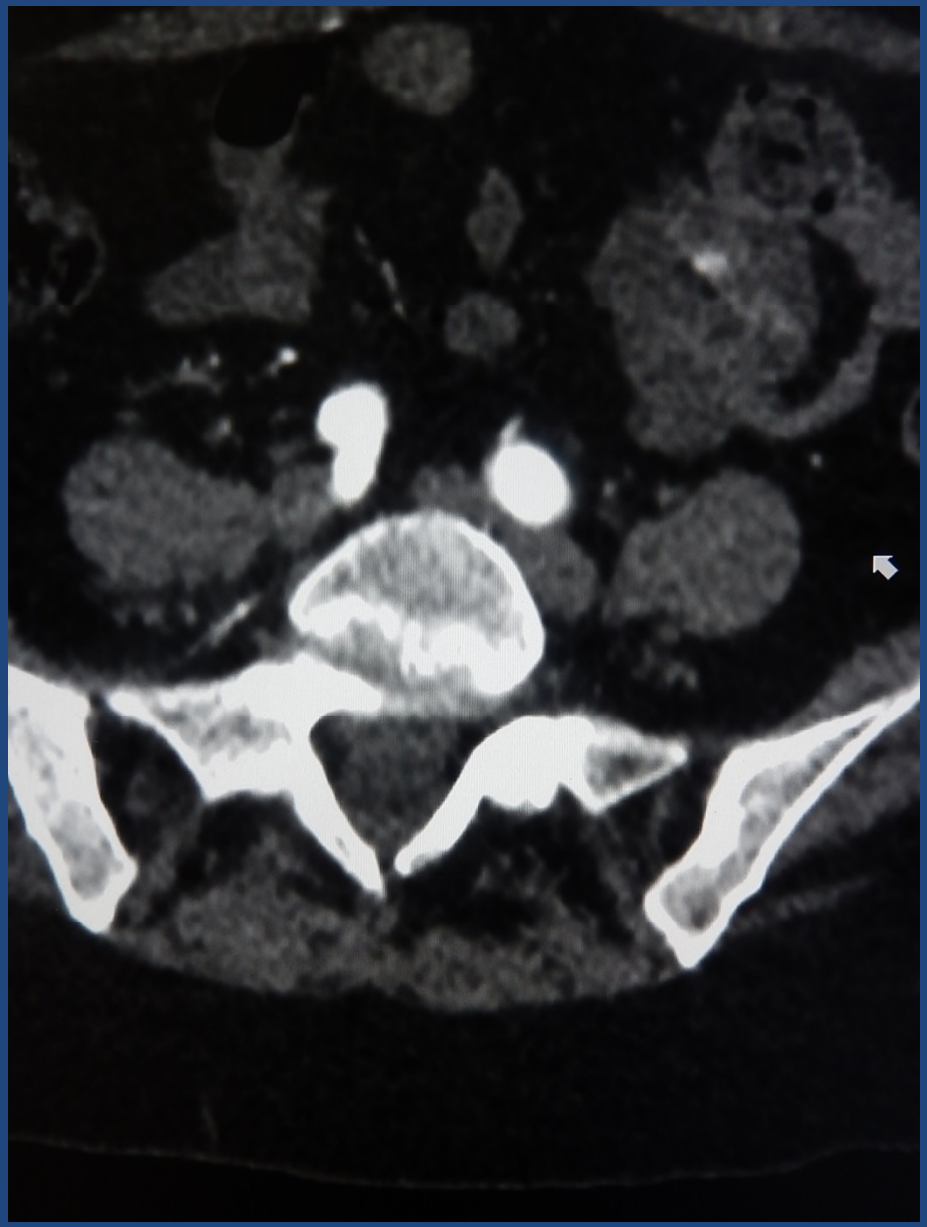

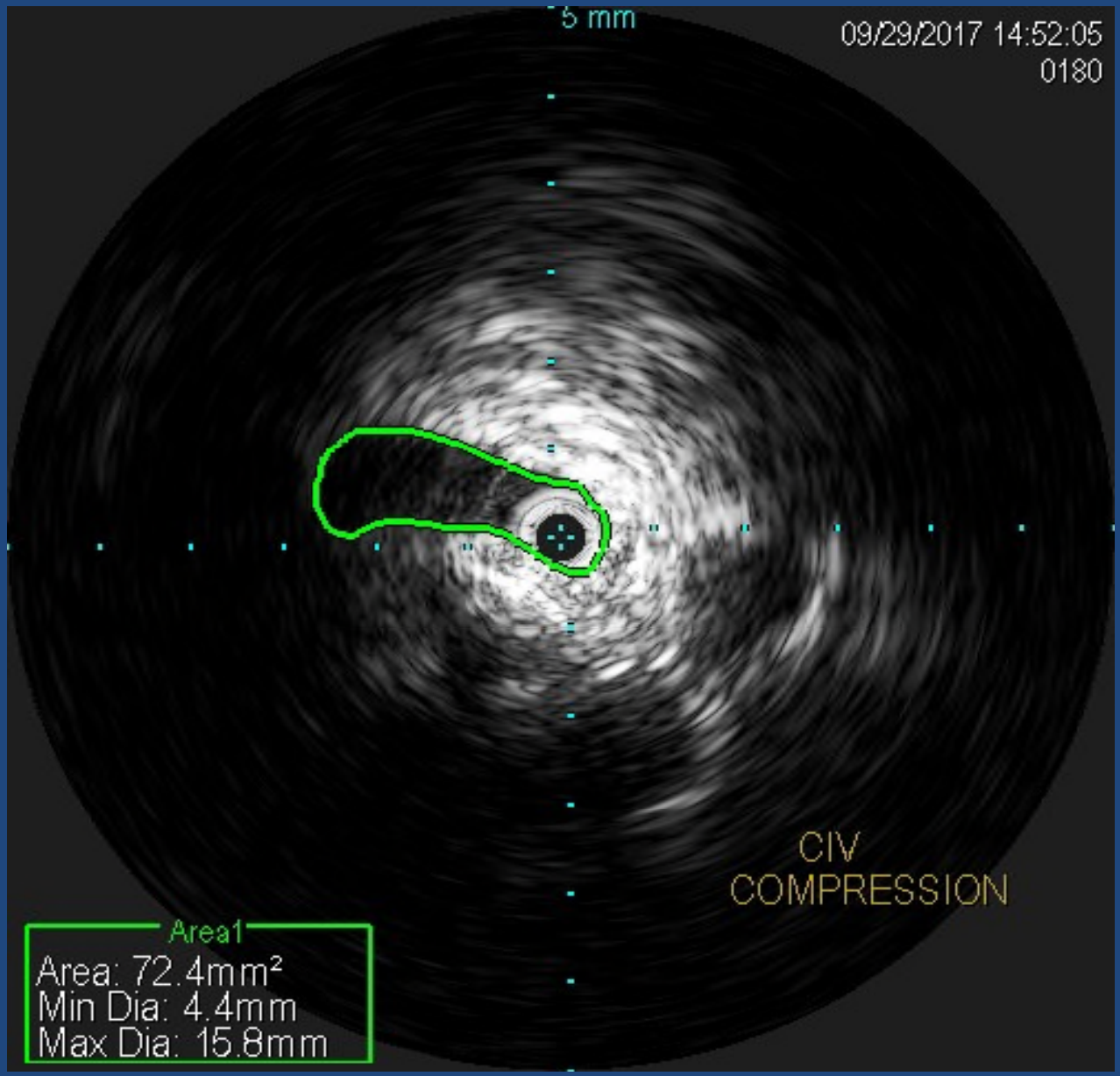
5 mm
09/29/2017 14:52:05
0180
CIV
COMPRESSION
Area1
Area: 72.4mm²
Min Dia: 4.4mm
Max Dia: 15.8mm

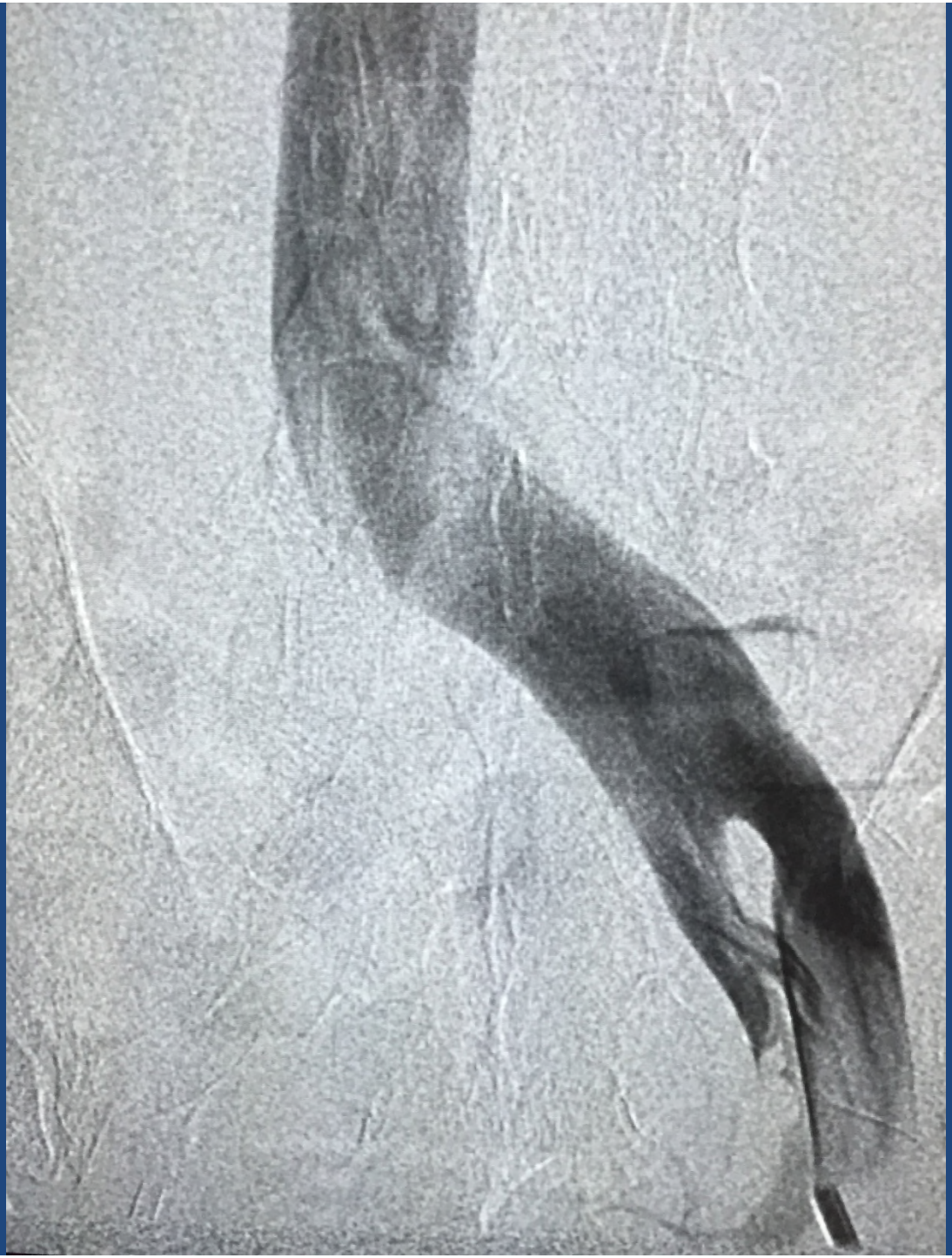

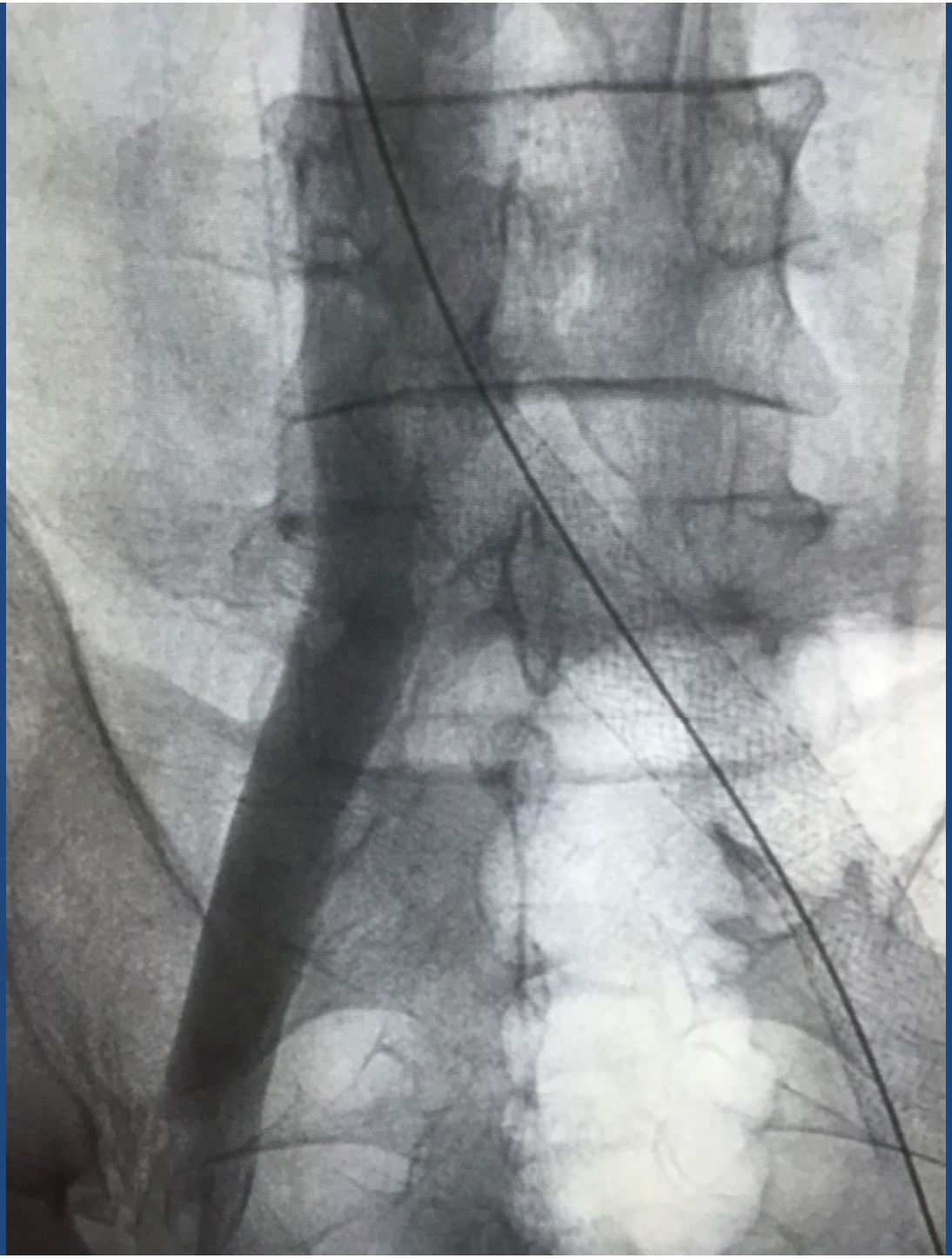

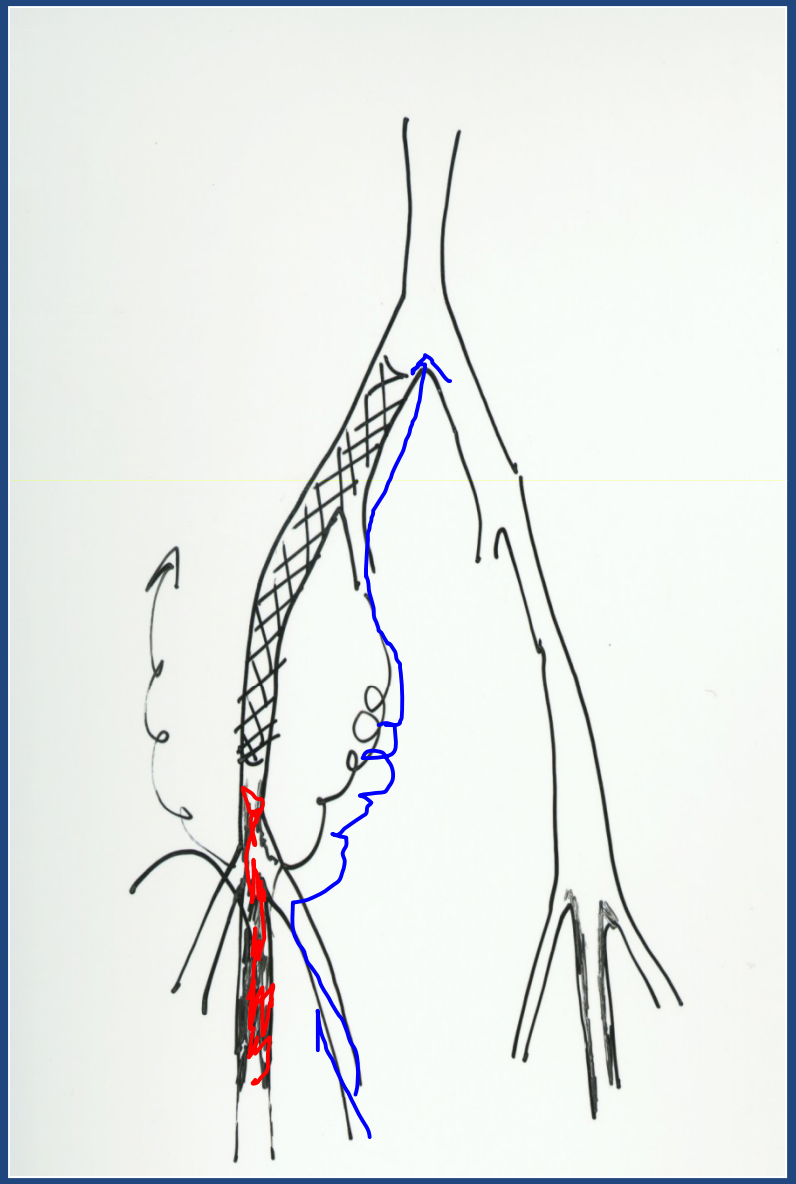

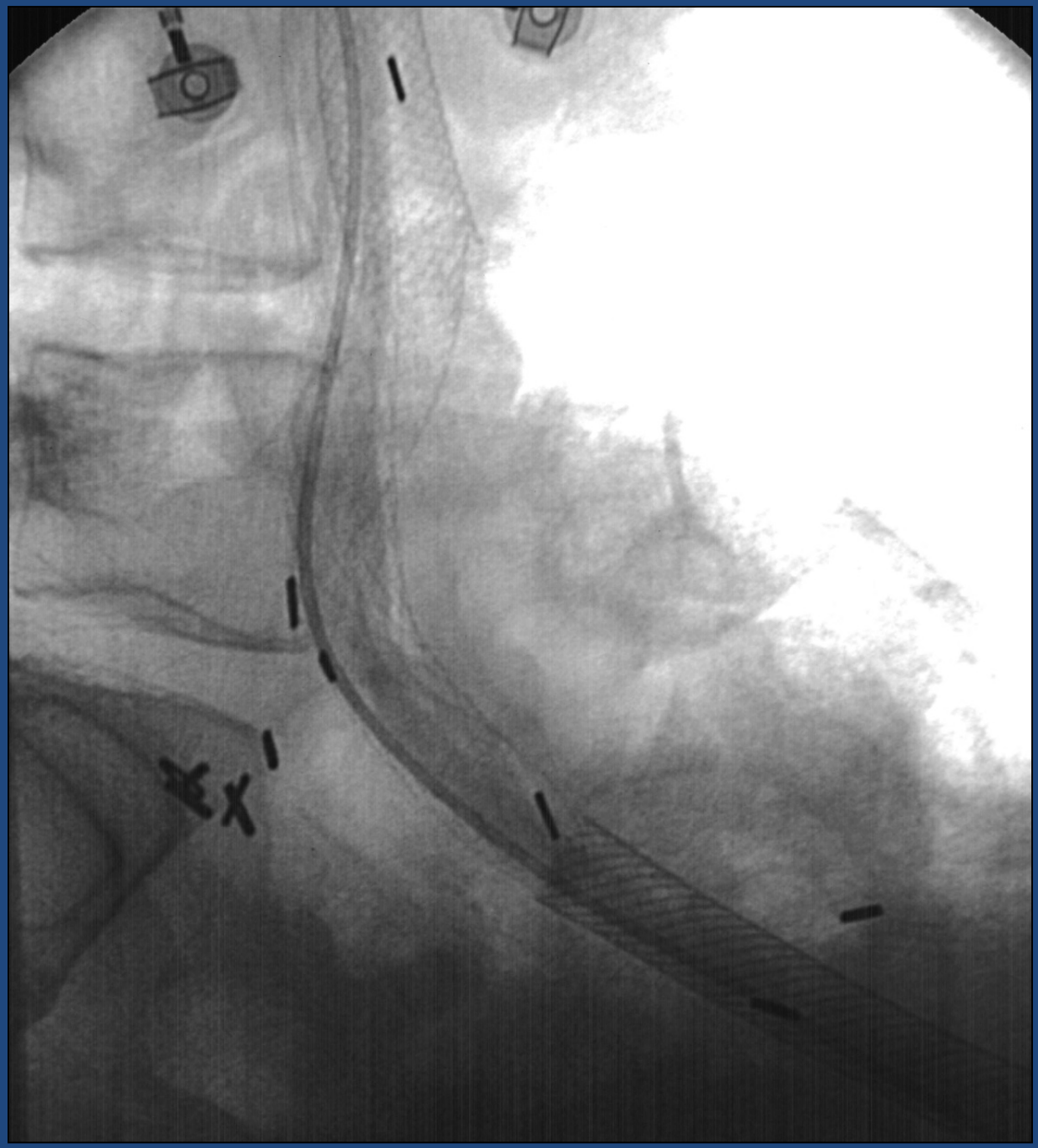

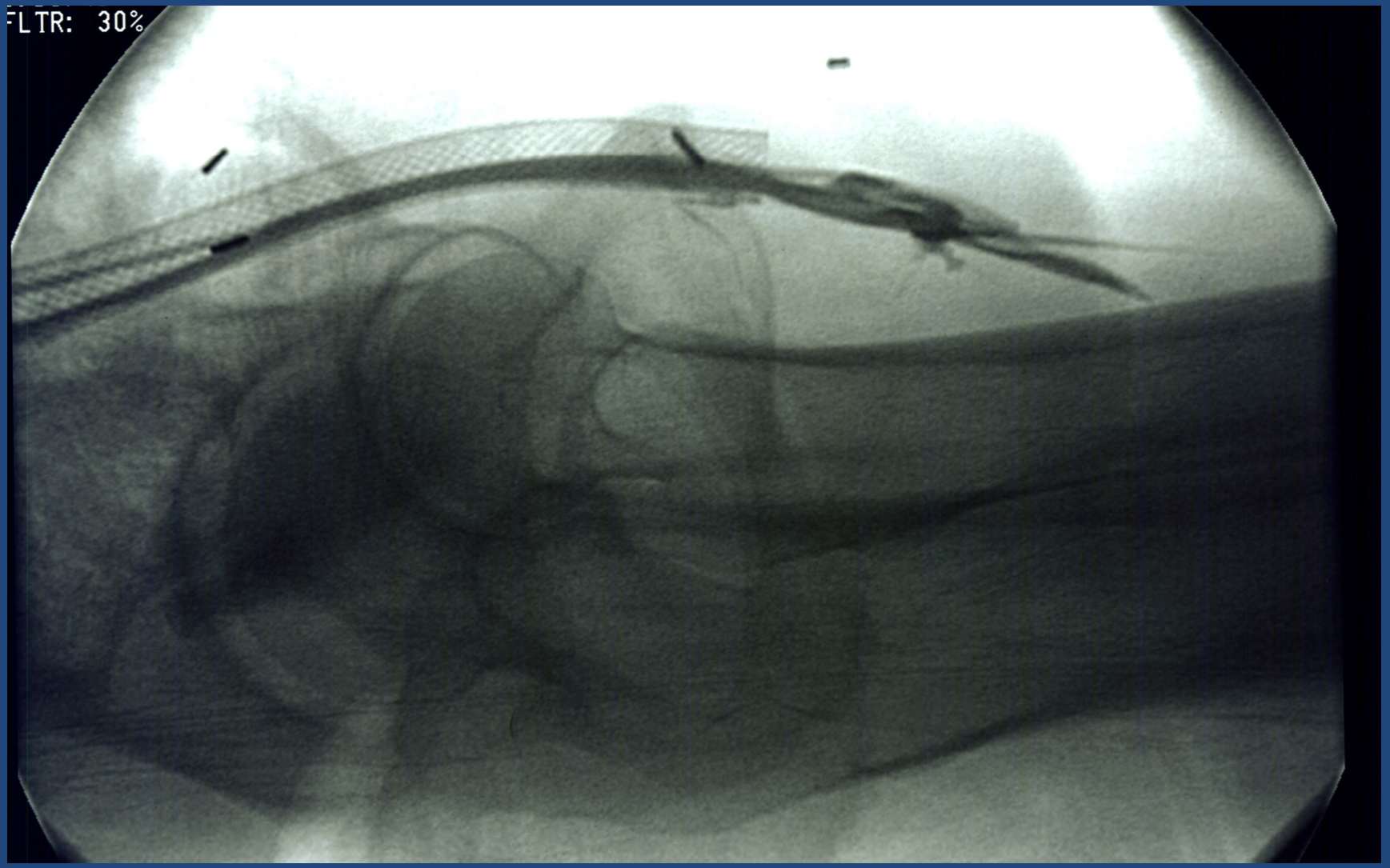
FLTR: 30%

[redacted]
ABRAZO AZ HEART HOSI
12/01/15 8:51:45 A
ADM
4C
MI 1.2
PZVENOU!
TIs 0.5
Pa
Dist IVC
1
2
3
Mth
PV (cm/s)
32.37
Mx
Right
Left
Prox CIV
1
2
3
Mth
1
2
3
PV (cm/s)
16.59
Mx
63.94
Mid EIV
PV (cm/s)
16.02
Mx
13.14
Dist CFV
PV (cm/s)
20.59
Mx
21.70

[redacted]

ABRAZO AZ HEART HOSI 4C MI 1.2
01/15/16 1:50:26 P ADM PZVENOU! TIs 0.4

	1	2	3	Mth
Dist IVC				
PV (cm/s)	44.45			Mx

	Right				Left		
	1	2	3	Mth	1	2	3
Prox CIV							
PV (cm/s)	22.88			Mx	37.40		
Mid EIV							
PV (cm/s)	32.80			Mx	33.23		
Dist CFV							
PV (cm/s)	29.42			Mx	19.80		

Conclusions: Treating Iliac vein compression with stents

- Symtomatic Non-thrombotic → good long term results
- Self-expanding, non-nitinol stents show best patency rates long term
- No thrombophilia, no warfarin long term
- MTS + acute DVT…….
- Thrombolysis may be required before stents
- Close clinical follow-up with duplex
- MTS + chronic DVT? Intervention is definitely an option
- IVUS Pre and Post stent

Meta Analysis – Venous Stenting is Safe and Efficacious

- 27 Studies
-

Peripheral Vascular Disease

Safety and Effectiveness of Stent Placement for Iliofemoral Venous Outflow Obstruction

Systematic Review and Meta-Analysis

Mahmood K. Razavi, MD; Michael R. Jaff, DO; Larry E. Miller, PhD

Conclusions—Stent placement for iliofemoral venous outflow obstruction results in high technical success and acceptable complication rates regardless of cause of obstruction. (*Circ Cardiovasc Interv*. 2015;8:e002772. DOI: 10.1161/CIRCINTERVENTIONS.115.002772.)

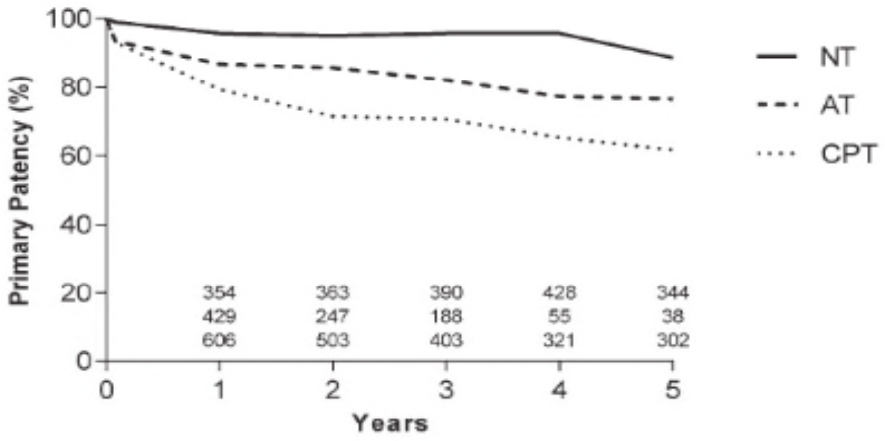

STENT PATENCY

	Nonthrombotic	Acute Thrombotic	Chronic PTS
Primary 1 year	96%	87%	79%
5 years	90%	80%	70%
Secondary 1 year	99%	89%	94%
5 years	98%	80%	85%

Oct 5, 2017

- I am pleased to inform you that your manuscript "Randomized Double-Blinded Study Comparing Medical Treatment Versus Iliac Vein Stenting in Chronic Venous Disease.," Manuscript Number JVS-D-16-00665R4 has been accepted for publication in the Journal of Vascular Surgery:Venous and Lymphatic Disorders.

- “the idea that excellence in performing a complex task requires a critical minimum level of practice surfaces again and again in studies of expertise”

- “ the emerging picture from such studies is that ten thousand hours of practice is required to achieve the level of mastery associated with being a world-class expert-----in anything” (neurologist Daniel Levitin)

- “In fact, researchers have settled on what they believe is the magic number for true expertise: TEN THOUSAND HOURS.”